



# Ovary, Fallopian Tube and Primary Peritoneal Carcinoma Histopathology Reporting Guide

Family/Last name Date of birth Given name(s) Patient identifiers Date of request Accession/Laboratory number Elements in **black text** are **CORE**. Elements in **grey text** are **NON-CORE**. indicates multi-select values  indicates single select values

SCOPE OF THIS DATASET

**CLINICAL INFORMATION** (select all that apply) (Note 1)

- Information not provided  
 Known gene predisposition (e.g., *BRCA1*, *BRCA2*, Lynch syndrome), *specify*

- 
- Prior neoadjuvant therapy,
- specify*

- 
- Other,
- specify*

**SPECIMEN(S) SUBMITTED** (select all that apply) (Note 2)

- Not specified  
 Ovary  
 Left  Right  Laterality not specified  
 Ovarian cystectomy  
 Left  Right  Laterality not specified  
 Fallopian tube  
 Left  Right  Laterality not specified  
 Uterus  
 Cervix  
 Omentum  
 Peritoneal biopsies  
 Peritoneal washings/peritoneal fluid  
 Lymph nodes, *specify site(s)*

- 
- Other,
- specify*

**SPECIMEN INTEGRITY** (select all that apply) (Note 3)

(Required only if ovary(ies)/fallopian tube(s) are submitted)

**Left ovary**

- Ovarian capsule intact  
 Ovarian capsule ruptured  
 Information not provided  
 Preoperatively  
 Intraoperatively

- Tumour on surface  
 Fragmented specimen

- 
- Other,
- specify*

**Right ovary**

- Ovarian capsule intact  
 Ovarian capsule ruptured  
 Information not provided  
 Preoperatively  
 Intraoperatively

- Tumour on surface  
 Fragmented specimen

- 
- Other,
- specify*

**Left fallopian tube**

- Serosa intact  
 Serosa ruptured  
 Information not provided  
 Preoperatively  
 Intraoperatively

- Tumour on serosal surface  
 Fragmented specimen

- 
- Other,
- specify*

**Right fallopian tube**

- Serosa intact  
 Serosa ruptured  
 Information not provided  
 Preoperatively  
 Intraoperatively

- Tumour on serosal surface  
 Fragmented specimen

- 
- Other,
- specify*

**TUMOUR SITE** (select all that apply) (Note 4)

- No macroscopically visible tumour  
 Indeterminate  
 Ovary  
 Left  Right  Laterality not specified  
 Fallopian tube  
 Left  Right  Laterality not specified  
 Fimbrial  Fimbrial  
 Non-fimbrial  Non-fimbrial  
 Peritoneum  
 Other, *specify*

**TUMOUR DIMENSIONS** (Note 5)

(If separate tumours specify dimensions for each site)

 x  x **MACROSCOPIC DESCRIPTION OF OMENTUM** (Note 6)

(Required only if omentum submitted)

**Omentum dimensions** x  x **Omental involvement**

- Not involved  
 Involved

Maximum dimension of largest tumour deposit

**BLOCK IDENTIFICATION KEY (Note 7)**

(List overleaf or separately with an indication of the nature and origin of all tissue blocks)

**HISTOLOGICAL TUMOUR TYPE (select all that apply) (Note 8)**

(Value list based on the World Health Organization Classification of Female Genital Tumours (2020))

- Serous borderline tumour
- Low grade serous carcinoma
- High grade serous carcinoma
- Mucinous borderline tumour
- Mucinous carcinoma
- Endometrioid borderline tumour
- Endometrioid carcinoma
- Clear cell borderline tumour
- Clear cell carcinoma
- Seromucinous borderline tumour
- Borderline Brenner tumour
- Malignant Brenner tumour
- Mesonephric-like adenocarcinoma
- Carcinoma, undifferentiated
- Dedifferentiated carcinoma
- Carcinosarcoma
- Mixed carcinoma
- Neuroendocrine neoplasm, specify type

Other, specify

**PATTERN OF INVASION (Note 9)**

(Applicable for mucinous carcinomas only)

- Expansile
- Infiltrative/destructive

**CARCINOSARCOMA COMPONENTS (select all that apply) (Note 10)**

Epithelial

Percentage  %

List components

Sarcomatous

Percentage  %

Type  Homologous  Heterologous

List components

**HISTOLOGICAL TUMOUR GRADE (Note 11)**

**Endometrioid carcinomas**

- GX: Cannot be assessed
- G1: Well differentiated
- G2: Moderately differentiated
- G3: Poorly differentiated

**Mucinous carcinomas**

- GX: Cannot be assessed
- G1: Well differentiated
- G2: Moderately differentiated
- G3: Poorly differentiated

**BORDERLINE TUMOUR - SPECIAL FEATURES (Note 12)**

(Applicable only if borderline tumour is identified)

**Micropapillary architecture for serous borderline tumour (at least 5 mm in one dimension)**

- Not identified
- Present

**Microinvasion (upper limit 5 mm)**

- Not identified
- Present

**Intraepithelial carcinoma for mucinous borderline tumour**

- Not identified
- Present

**Implants for serous and seromucinous borderline tumour (select all that apply)**

- Non-invasive implants
  - Not identified
  - Present
    - Epithelial
    - Desmoplastic
- Site(s)  Pelvic  Abdominal

Invasive implants/Extra-ovarian low grade serous carcinoma

- Not identified
- Present
  - Site(s)  Pelvic  Abdominal

Indeterminate

- Not identified
- Present
  - Site(s)  Pelvic  Abdominal

**SEROUS TUBAL INTRAEPITHELIAL CARCINOMA (STIC)**

(Required only if fallopian tube(s) are submitted) (Note 13)

**Left fallopian tube**

- Cannot be assessed
- Not identified
- Present (select all that apply)
  - Fimbrial
  - Non-fimbrial

**Right fallopian tube**

- Cannot be assessed
- Not identified
- Present (select all that apply)
  - Fimbrial
  - Non-fimbrial

**HISTOLOGICAL SITES OF TUMOUR INVOLVEMENT (Note 4)**

**Left ovary**

- Not applicable
- Cannot be assessed
- Not involved
- Involved

**Right ovary**

- Not applicable
- Cannot be assessed
- Not involved
- Involved

**Left fallopian tube**

- Not applicable
- Cannot be assessed
- Not involved
- Involved

**Right fallopian tube**

- Not applicable
- Cannot be assessed
- Not involved
- Involved

**Uterus**

- Not applicable
- Cannot be assessed
- Not involved
- Involved (select all that apply)
  - Site(s)  Myometrium
  - Endometrium
  - Cervix

**Omentum**

- Not applicable
- Cannot be assessed
- Not involved
- Involved
  - Level of involvement
    - Macroscopic
    - Microscopic

**Peritoneum (including uterine serosa)**

- Not applicable
- Cannot be assessed
- Not involved
- Involved (select all that apply)
  - Site(s)  Pelvis, *specify site(s)*

- Abdomen, *specify site(s)*

**Other involved organs(s)/sites(s), specify**

**PERITONEAL CYTOLOGY (Note 14)**

- Not submitted
- Indeterminate
- Positive
- Negative

**RESPONSE TO NEOADJUVANT THERAPY (Note 15)**

- Cannot be assessed
- No prior treatment
- No definite or minimal response identified (chemotherapy response score (CRS 1))
- Moderate response identified (CRS 2)
- Marked response with no or minimal residual cancer (CRS 3)

**LYMPH NODE STATUS (Note 16)**

- Cannot be assessed
- No nodes submitted or found
- Not involved
- Involved (select all that apply)

**Regional**

**Left pelvic**

Number of nodes examined<sup>a</sup>

Number of positive nodes<sup>a</sup>

**Right pelvic**

Number of nodes examined<sup>a</sup>

Number of positive nodes<sup>a</sup>

**Para-aortic**

Number of nodes examined<sup>a</sup>

Number of positive nodes<sup>a</sup>

**Maximum dimension of largest deposit in regional node**  mm

**Non-regional**

**Site 1**

Number of nodes examined<sup>a</sup>

Number of positive nodes<sup>a</sup>

**Site 2**

Number of nodes examined<sup>a</sup>

Number of positive nodes<sup>a</sup>

<sup>a</sup> In some cases it may not be possible to record the actual number of nodes due to fragmentation of the specimen.

**COEXISTENT PATHOLOGY/PRECURSOR LESIONS (Note 17)**

- None identified
- Present, *specify*

**ANCILLARY STUDIES (Note 18)**

- Not performed
- Performed (select all that apply)

Immunohistochemistry, *specify test(s) and result(s)*

Molecular findings, *specify test(s) and result(s)*

Other, *specify test(s) and result(s)*

**ANCILLARY STUDIES (Note 18) continued**

**Representative blocks for ancillary studies, specify those blocks best representing tumour and/or normal tissue for further study**

**PROVISIONAL PATHOLOGICAL STAGING (Note 19)****FIGO (2014 edition)<sup>b</sup>****Site of primary tumour**

- Primary tumour, ovary (OV)
- Primary tumour, fallopian tube (FT)
- Primary tumour, peritoneum (P)
- Undesignated: site of primary tumour cannot be assessed (X)
- I Tumour is confined to ovaries or fallopian tube(s)
  - IA Tumour limited to 1 ovary (capsule intact) or fallopian tube; no tumour on ovarian or fallopian tube surface; no malignant cells in the ascites or peritoneal washings
  - IB Tumour limited to both ovaries (capsules intact) or fallopian tubes; no tumour on ovarian or fallopian tube surface; no malignant cells in the ascites or peritoneal washings
  - IC Tumour limited to 1 or both ovaries or fallopian tubes, with any of the following:
    - IC1 Surgical spill
    - IC2 Capsule ruptured before surgery or tumour on ovarian or fallopian tube surface
    - IC3 Malignant cells in the ascites or peritoneal washings
- II Tumour involves 1 or both ovaries or fallopian tubes with pelvic extension (below pelvic brim) or primary peritoneal cancer
  - IIA Extension and/or implants on uterus and/or fallopian tubes and/or ovaries
  - IIB Extension to other pelvic intraperitoneal tissues
- III Tumour involves 1 or both ovaries or fallopian tubes, or primary peritoneal cancer, with cytologically or histologically confirmed spread to the peritoneum outside the pelvis and/or metastasis to the retroperitoneal lymph nodes
  - IIIA1 Positive retroperitoneal lymph nodes only (cytologically or histologically proven):
    - IIIA1(i) Metastasis up to 10 mm in greatest dimension
    - IIIA1(ii) Metastasis more than 10 mm in greatest dimension
  - IIIA2 Microscopic extrapelvic (above the pelvic brim) peritoneal involvement with or without positive retroperitoneal lymph nodes
  - IIIB Macroscopic peritoneal metastasis beyond the pelvis up to 2 cm in greatest dimension, with or without metastasis to the retroperitoneal lymph nodes
  - IIIC Macroscopic peritoneal metastasis beyond the pelvis more than 2 cm in greatest dimension, with or without metastasis to the retroperitoneal lymph nodes (includes extension of tumour to capsule of liver and spleen without parenchymal involvement of either organ)
- IV Distant metastasis excluding peritoneal metastases
  - IVA Pleural effusion with positive cytology
  - IVB Parenchymal metastases and metastases to extra abdominal organs (including inguinal lymph nodes and lymph nodes outside of the abdominal cavity)

<sup>b</sup> Reprinted from *Int J Gynaecol Obstet.*, Volume 124, Part 1 and FIGO Committee on Gynecologic Oncology, *Staging classification for cancer of the ovary, fallopian tube, and peritoneum*, pages 1-5, 2014, with permission from Wiley.

**TNM Staging (UICC TNM 8<sup>th</sup> edition 2016)<sup>c</sup>****TNM Descriptors** (only if applicable) (select all that apply)

- m - multiple primary tumours
- r - recurrent
- y - post-therapy

**Primary tumour (pT)**

- TX Primary tumour cannot be assessed
- T0 No evidence of primary tumour
- T1 Tumour limited to the ovaries (one or both) or fallopian tube(s)
  - T1a Tumour limited to one ovary (capsule intact) or fallopian tube; capsule intact, no tumour on ovarian surface or fallopian tube surface; no malignant cells in ascites or peritoneal washings
  - T1b Tumour limited to both ovaries or fallopian tubes; capsule intact, no tumour on ovarian or fallopian tube surface; no malignant cells in ascites or peritoneal washings
  - T1c Tumour limited to one or both ovaries or fallopian tubes with any of the following:
    - T1c1 Surgical spill
    - T1c2 Capsule ruptured before surgery or tumour on ovarian or fallopian tube surface
    - T1c3 Malignant cells in ascites or peritoneal washings
- T2 Tumour involves one or both ovaries or fallopian tubes with pelvic extension (below pelvic brim) or primary peritoneal cancer
  - T2a Extension and/or implants on uterus and/or fallopian tube(s) and/or ovary(ies)
  - T2b Extension to other pelvic tissues, including bowel within the pelvis
- T3 and/or N1 Tumour involves one or both ovaries or fallopian tubes or primary peritoneal carcinoma with cytologically or histologically confirmed spread to the peritoneum outside the pelvis and/or metastasis to the retroperitoneal lymph nodes

**Regional lymph nodes (pN)**

- N1 Retroperitoneal lymph node metastasis only
  - N1a Lymph node metastasis not more than 10 mm in greatest dimension
  - N1b Lymph node metastasis more than 10 mm in greatest dimension
- T3a any N Microscopic extrapelvic (above the pelvic brim) peritoneal involvement with or without retroperitoneal lymph node, including bowel involvement
- T3b any N Macroscopic peritoneal metastasis beyond pelvic brim 2 cm, or less in greatest dimension, including bowel involvement outside the pelvis with or without retroperitoneal nodes
- T3c any N Peritoneal metastasis beyond pelvic brim more than 2 cm in greatest dimension and/or retroperitoneal lymph node metastasis (includes extension of tumour to capsule of liver and spleen without parenchymal involvement of either organ)

<sup>c</sup> Reproduced with permission. Source: *UICC TNM Classification of Malignant Tumours, 8<sup>th</sup> Edition*, eds by James D. Brierley, Mary K. Gospodarowicz, Christian Wittekind. 2016, Publisher Wiley (incorporating any errata published up until 6<sup>th</sup> October 2020).

## Definitions

### CORE elements

CORE elements are those which are essential for the clinical management, staging or prognosis of the cancer. These elements will either have evidentiary support at Level III-2 or above (based on prognostic factors in the National Health and Medical Research Council (NHMRC) levels of evidence<sup>1</sup>). In rare circumstances, where level III-2 evidence is not available an element may be made a CORE element where there is unanimous agreement by the Dataset Authoring Committee (DAC). An appropriate staging system e.g., Pathological TNM staging would normally be included as a CORE element.

Molecular and immunohistochemical testing is a growing feature of cancer reporting. However, in many parts of the world this type of testing is limited by the available resources. In order to encourage the global adoption of ancillary tests for patient benefit, International Collaboration on Cancer Reporting (ICCR) includes the most relevant ancillary testing in ICCR Datasets as CORE elements, especially when they are necessary for the diagnosis. Where the technical capability does not yet exist, laboratories may consider temporarily using these data elements as NON-CORE items.

The summation of all CORE elements is considered to be the minimum reporting standard for a specific cancer.

### NON-CORE elements

NON-CORE elements are those which are unanimously agreed should be included in the dataset but are not supported by level III-2 evidence. These elements may be clinically important and recommended as good practice but are not yet validated or regularly used in patient management.

Key information other than that which is essential for clinical management, staging or prognosis of the cancer such as macroscopic observations and interpretation, which are fundamental to the histological diagnosis and conclusion e.g., macroscopic tumour details, may be included as either CORE or NON-CORE elements by consensus of the DAC.

 [Back](#)

## Scope

The dataset has been developed for the pathology reporting of resection specimens of primary borderline and malignant epithelial tumours of the ovary, fallopian tubes and peritoneum. It does not include non-epithelial ovarian neoplasms such as germ cell or sex cord stromal tumours or other primary peritoneal neoplasms such as mesothelioma.<sup>2</sup> In those rare cases where more than one primary tumour of different morphological types is present, separate datasets should be completed for each neoplasm. These should include all the elements in this dataset, except for lymph node status which does not need to be documented separately for each tumour.

The 2<sup>nd</sup> edition of this dataset includes changes to align the dataset with the World Health Organization (WHO) Classification of Tumours, Female Genital Tumours, 5<sup>th</sup> edition, 2020.<sup>3</sup> The International Collaboration on Cancer Reporting (ICCR) dataset includes 5<sup>th</sup> edition Corrigenda, June 2021.<sup>4</sup>

The authors of this dataset can be accessed [here](#).

 [Back](#)

## Note 1 – Clinical information (Non-core)

It is estimated that approximately 10% of primary tubo-ovarian and peritoneal carcinomas have a genetic basis,<sup>5</sup> and this figure may be as high as 17% for high grade serous carcinomas (HGSCs).<sup>6</sup> Germline mutations in *BRCA1* and *BRCA2* account for the majority of genetically related cases while up to 10% of patients with Lynch syndrome (LS) will develop ovarian carcinoma.

It is acknowledged that definitive genetic status is often not known or information about genetic status is not provided to the pathologist at the time of biopsy/surgery. Moreover, this information is not essential for the histological assessment and routine reporting of these tumours. Nevertheless, it is recommended that available information on genetic status be recorded for the following reasons:

1. High grade serous carcinomas (HGSCs) associated with *BRCA* mutations (germline or somatic) more commonly show certain morphological features such as solid, pseudoendometrioid or transitional-like ('SET') architectural patterns, very marked nuclear atypia, and tumour-infiltrating lymphocytes.<sup>5,7,8</sup> Thus, pathologists may be able to correlate the histological findings with any genetic data provided, better chemotherapy response, and consideration of specific therapeutic regimes such as those including poly ADP ribose polymerase inhibitors (PARPi).<sup>5,6,9</sup> Patients with suspected germline *BRCA* mutations and their relatives, may also be referred for genetic testing and counselling in regard to appropriate screening for *BRCA*-related neoplasia, although in many places this is done for all HGSCs irrespective of the tumour morphology.
2. Knowledge of proven or potential hereditary gynaecological cancer predisposition will affect pathological sampling of macroscopically normal tissues. This is most evident in the setting of prophylactic 'risk reduction surgery', especially in patients with known *BRCA1* or *BRCA2* mutation, where complete examination of tubal and ovarian tissues is essential.<sup>5</sup> Small, macroscopically occult tubal carcinomas, and their in situ precursor - serous tubal intraepithelial carcinoma (STIC) - is much more likely to be identified in this setting.

Approximately 1-2% of all ovarian carcinomas are associated with LS due to a germline mutation in one of the genes encoding the DNA mismatch repair (MMR) proteins.<sup>10</sup> In approximately 60% of women with LS, a gynaecological tumour (endometrial or ovarian) will represent the sentinel cancer.<sup>11</sup> Endometrioid and clear cell and endometriosis-associated carcinomas occur more frequently in LS and, therefore, immunohistochemical analysis of MMR proteins or molecular testing for microsatellite instability may be considered in these tumour types, or if there is relevant personal or family history of additional LS-related neoplasia.

Preoperative chemotherapy may significantly alter the gross and microscopic appearance of the tumour and result in difficulties in tumour typing and tumour down-staging. If neoadjuvant chemotherapy is being administered, a pretreatment tissue biopsy is recommended for tumour typing. If this is not possible then the diagnosis of malignancy can be made on cytological examination of ascitic fluid, preferably with immunohistochemistry (IHC) performed on a cell block preparation; however, there are limitations to the interpretation of immunohistochemical markers on cell blocks.<sup>12</sup> Markers of value in tumour typing are discussed in **Note 18 ANCILLARY STUDIES**.

 [Back](#)

## Note 2 – Specimen(s) submitted (Core)

Providing information about the specimen type is regarded as an integral part of the reporting of primary ovarian, tubal and peritoneal cancers. While the nature of the specimens submitted for pathological assessment may be deduced from the surgical procedure, specifying the nature of the specimen received provides complementary information and confirmation that entire organs have been resected and submitted.

 [Back](#)

### Note 3 – Specimen integrity (Core)

Assessment of the integrity of the specimen (ovary or tube) is important, particularly for substaging of organ-confined disease (Stage I). Core information should include whether the ovarian capsule or tubal serosa is intact or ruptured, and also if there is tumour on the surface, or whether the tumour was received fragmented or intact. In case of capsule rupture, it is recommended to try to ascertain if rupture occurred before or during surgery (this is important in substaging International Federation of Gynaecology and Obstetrics (FIGO) Stage IC disease).<sup>13</sup> Note that if the specimen ruptures within a bag during laparoscopic removal, or is cut into in the operating room, after removal from the patient, such that the peritoneal cavity is not exposed to the contents of the mass, it should be considered to be not ruptured i.e., 'intact', for surgical pathology reporting purposes.

According to the 2014 FIGO Staging System for ovarian, tubal and primary peritoneal cancer,<sup>13</sup> ovarian capsular or tubal serosal rupture before surgery is considered Stage IC2 while intraoperative rupture is Stage IC1. There is some controversy as to whether rupture during surgery worsens the prognosis in the absence of surface excrescences, ascites or positive washings. Some studies showed a higher risk of recurrence in association with intraoperative ovarian capsular rupture,<sup>14,15</sup> while others did not.<sup>16-18</sup>

A 2014 meta-analysis assessed the impact of intraoperative rupture on prognosis, after analysing nine eligible studies which included 2,382 patients.<sup>13</sup> Patients with preoperative capsular rupture showed poorer progression-free survival (PFS) than those with no rupture or intraoperative rupture. In sub-analyses, preoperative rupture was associated with a worse prognosis, and intraoperative rupture had a poorer PFS than no rupture. However, no difference in PFS was found between intraoperative rupture and no rupture in patients who underwent a complete surgical staging operation, with or without adjuvant platinum-based chemotherapy. In a recent large study, the risk associated with intra-operative rupture/Stage IC1 ovarian carcinoma was histotype dependent and greatest for patients with clear cell carcinoma.<sup>19</sup>

There is some evidence to suggest that clear cell carcinomas exhibit a higher risk of rupture,<sup>20</sup> probably related to adhesions to the surrounding tissues, associated with tumour invasion or endometriosis.<sup>21</sup> Capsular rupture has also been associated with pregnancy.<sup>22</sup>

 [Back](#)

### Note 4 – Tumour site/Histological sites of tumour involvement (Core)

Sites of tumour involvement should be recorded as this is necessary for tumour staging. Although site assignment (tube versus ovary versus peritoneum) for clear cell, endometrioid, low grade serous and mucinous carcinomas is generally not problematic since almost all arise in the ovary, except for occasional cases arising in extraovarian endometriosis, the same is not true for HGSCs.

It was first recognised in 2001, that a high percentage of so-called ovarian HGSC in women with germline *BRCA1* mutations arise in the fimbrial end of the fallopian tube.<sup>23,24</sup> This was initially reported in risk reducing salpingo-oophorectomy specimens where early pre-invasive HGSCs were much more likely to be present in the fallopian tube than ovary. These STICs harbour identical *p53* mutations to the extratubal tumour, establishing that they are clonal.<sup>25</sup> Comparison of telomere length and centrosome amplification in matched STIC and ovarian HGSC suggests that the STICs develop before the ovarian tumours and are in fact a precursor and not a metastatic focus.<sup>26,27</sup> Finally, although numbers are small, early, incidental non-*BRCA1/2* associated (sporadic) HGSCs are predominantly detected in the fallopian tube mucosa, especially the fimbria, rather than the ovary.<sup>28</sup> In summary, there is compelling evidence that the precursors of HGSC originate in the fallopian tube in patients with germline *BRCA1* mutations, and there is accumulating and convincing evidence that this is also true for sporadic HGSC. Assignment of primary site should therefore reflect our current understanding of where HGSCs originate, based on data from the study of early incidental or pre-invasive HGSC. However, some cases of ovarian and primary peritoneal HGSCs do not show STIC lesions or tubal mucosal HGSC despite entire submission of the grossly normal fallopian tubes for histological evaluation. In a consecutive series of non-

uterine HGSCs classified as ovarian or peritoneal based on pre-FIGO 2014 criteria in which the fallopian tubes were examined in their entirety, STICs were identified in 59% of cases, and invasive HGSC of the mucosa of the fallopian tube in an additional 15% of cases.<sup>13,29</sup> In other cases, the fimbrial end of the fallopian tube was obliterated by a tubo-ovarian mass.

According to the 2014 FIGO Staging System, the primary site of non-uterine HGSC is designated as ovarian, tubal or primary peritoneal.<sup>13</sup> In some cases it may not be possible to ascertain the primary site of origin, and these should be categorised as 'undesignated' in the new staging system.<sup>13</sup> The descriptor 'tubo-ovarian HGSC' can also be used in practice for those cases of advanced stage HGSC where there is uncertainty about primary site, e.g., pre-treatment biopsy from the omentum. The problems in ascertaining the primary site and the variation in practice amongst pathologists have significant implications for epidemiological studies, determination of tumour incidence and mortality, data collection by cancer registries and entry into clinical trials. Based on the 2020 WHO Classification,<sup>3</sup> recommendations for assigning the site of origin of extra-uterine HGSC are provided in the following section. Using these criteria, assignment of primary site is no longer based on the site of greatest volume/size of tumour but the presence of STIC or tubal mucosa involvement by HGSC indicates a fallopian tube origin, as does partial or total obliteration of one or both fallopian tubes by a tumour mass. Application of these criteria will be important in ensuring consistency between different pathologists in assigning the site of origin of HGSC with obvious important implications for cancer registration and other parameters.<sup>30</sup>

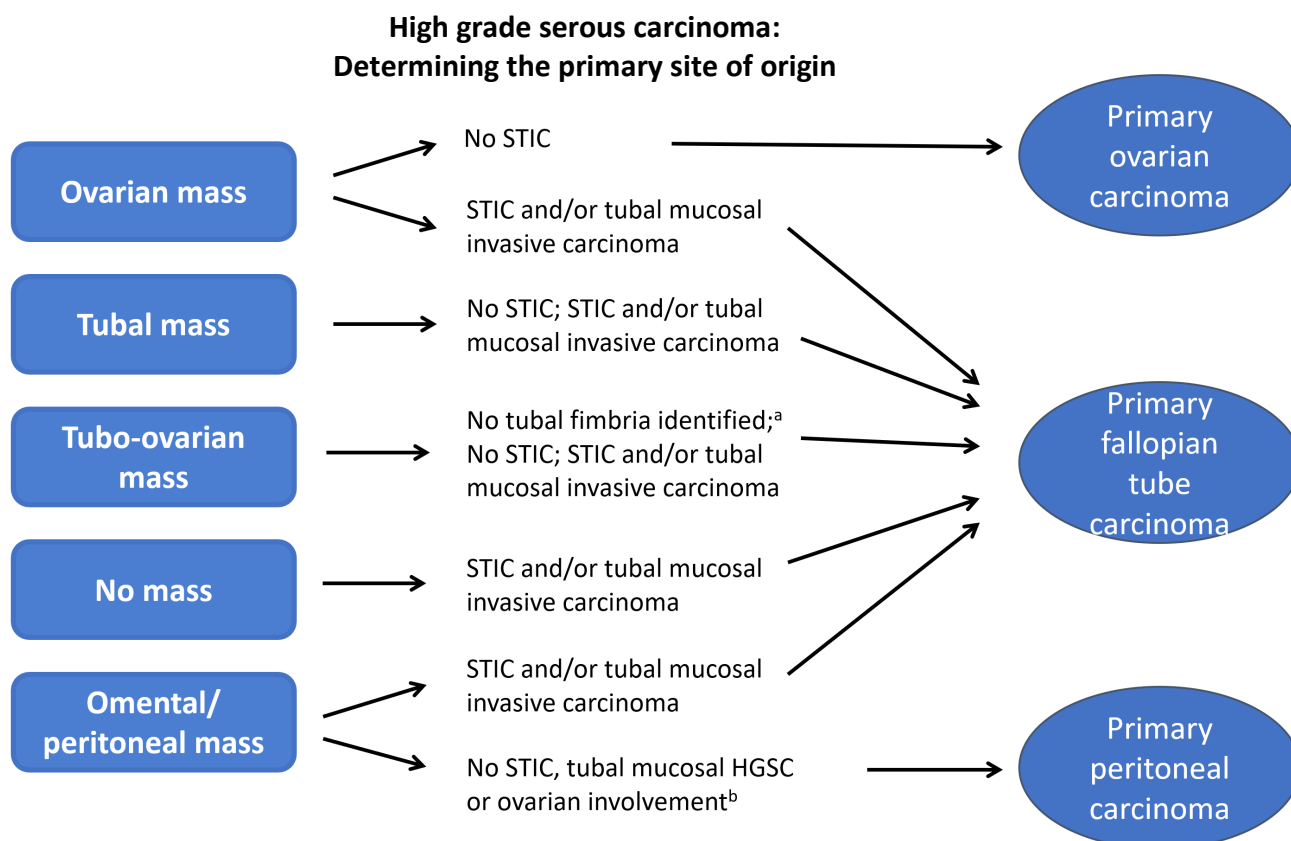
### **Suggestions for assigning site of origin**

The following suggestions are not intended to be an exhaustive list nor are they intended to be binding, and assignment of origin in an individual case (Figure 1) is left to the discretion of the pathologist and the clinical team, ideally in the setting of a multidisciplinary team meeting. Undoubtedly, there will be evolution over time in our ability to accurately assign the primary tumour site, but the following are intended as practical guidelines for handling cases at the present time:<sup>30</sup>

1. The fallopian tubes, or at least their fimbrial ends, should be well sampled - whenever possible - in all cases of HGSC by a sectioning and extensively examining the fimbriated end (SEE-FIM)-like protocol<sup>25</sup> to avoid missing this important site of disease, which probably represents the tumour origin in the large majority of cases.
2. The presence of STIC, in the absence of invasive HGSC involving the fallopian tube, should be considered as tubal primary for staging purposes, e.g., points 4 and 7.
3. The presence of STIC without invasion or extratubal spread should be staged as FIGO Stage IA tubal carcinoma (although these have a favourable prognosis, based on limited experience to date<sup>31</sup>) but with an annotation that there is no 'invasive' carcinoma.
4. Cases with only STIC in the fallopian tube, ovarian surface involvement or parenchymal involvement not exceeding 5 millimetres (mm) and widespread peritoneal involvement, which would traditionally be categorised as primary peritoneal carcinoma,<sup>32</sup> should be classified as tubal primaries.
5. Cases with HGSC located within the mucosa of the fallopian tube, including its fimbrial end, with or without STIC in any portion of the fallopian tube and with no, minimal or even substantial ovarian involvement should be categorised as tubal primaries. Note that the distinction between STIC and intramucosal HGSC of the fallopian tube is subjective, with the latter showing a greater degree of stratification and architectural complexity.
6. Cases in which the fallopian tube is not identifiable, having presumably been overgrown by the ipsilateral adnexal mass, or the distal end of the fallopian tube is incorporated into a large tubo-ovarian mass should also, based on current understanding, be diagnosed as tubal primaries. It is emphasised that a careful effort must be made to identify the tube in all cases.
7. Cases with a dominant ovarian mass(es) and identifiable fallopian tubes with STIC should be classified as tubal primaries.
8. Cases with a dominant ovarian mass(es) and identifiable fallopian tubes without STIC or mucosal involvement by HGSC, after SEE-FIM, should be classified as ovarian primaries.



9. Cases should be categorised as primary peritoneal carcinoma by the conventional criteria below<sup>3</sup> and only after complete histological examination of the fallopian tubes (including the non-fimbrial portions) has excluded the presence of STIC or a small tubal HGSC or ovarian involvement by HGSC.
10. All cases classified as 'undesignated' for FIGO staging purposes should be further described as 'tubo-ovarian' or 'tubal/ovarian' to distinguish them from serous carcinoma originating in the uterus. Using the suggestions presented here, these should represent a small proportion of HGSC.
11. Cases with unilateral or bilateral HGSC in the ovary and/or STIC or HGSC in the tube but with an endometrial serous intraepithelial or invasive carcinoma should be carefully evaluated for an endometrial versus a tubo-ovarian primary (WT1 may be of value in such cases - see **Note 18 ANCILLARY STUDIES**, to distinguish between ovarian and uterine carcinoma). The majority of such cases will represent adnexal metastases from an endometrial serous carcinoma.<sup>33</sup>



**Figure 1: High grade serous carcinoma: determining the primary site of origin.**

Serous tubal intraepithelial carcinoma (STIC).

<sup>a</sup> Failure to detect the tubal fimbria implies overgrowth by tumour.

<sup>b</sup> Apply criteria as specified in the commentary.

© 2021 International Collaboration on Cancer Reporting Limited (ICCR).

↑ Back

## Note 5 – Tumour dimensions (Non-core)

There is little or no published evidence to suggest that size of the primary tumour is of prognostic significance, and size is not important for staging or management. The principal reason for recording the tumour dimensions, especially the maximum diameter, is to provide evidence that the tumour has been adequately sampled for histology. There are no evidence-based guidelines as to the optimal sampling of solid or cystic ovarian tumours. By convention, however, most pathologists sample one block per 10 mm of maximum tumour diameter in solid tumours. These same recommendations appear in cancer datasets for tumours at a range of other anatomical sites.

Adequate sampling of ovarian tumours is important for a number of reasons; for example, to identify foci of microinvasion or invasion in borderline tumours, foci of sarcoma in an ovarian carcinoma (carcinosarcoma), or foci of undifferentiated carcinoma in an endometrioid carcinoma (dedifferentiated carcinoma).

It is recognised that ovarian mucinous neoplasms may exhibit considerable intratumoural heterogeneity with an admixture of benign, borderline and malignant areas. One study which assessed the 'adequacy' of sampling in epithelial ovarian neoplasms,<sup>34</sup> confirmed mucinous carcinomas to display more histological variation than serous carcinomas. The authors concluded that more extensive sampling was required in borderline tumours to exclude foci of invasion. According to the recommendations of the 2004 Bethesda Workshop for borderline ovarian tumours,<sup>35</sup> all borderline tumours should be well sampled – at least two sections per 10 mm (excluding smooth-walled cystic foci) with the exception that borderline tumours of less than 100 mm should be sampled with one block per 10 mm of maximum tumour diameter. The recommendation that there should be more extensive sampling of larger tumours, especially those of mucinous type, reflects their greater likelihood of harbouring foci of invasive carcinoma. Additional sampling of mucinous borderline tumours is also recommended when histological features such as intraepithelial carcinoma or microinvasion are identified in the original sections. Similarly, additional sampling in serous borderline tumours is recommended when micropapillary areas or microinvasion are present in initial sections since such neoplasms are more likely to harbour invasive foci.

In mucinous ovarian tumours, tumour size may be helpful in determining whether the ovarian neoplasm is primary or metastatic. Unilateral mucinous carcinomas  $\geq 100$  mm in diameter are more likely to be primary than metastatic.<sup>36,37</sup>

 [Back](#)

## Note 6 – Macroscopic description of omentum (Core)

Three dimensions of the omentum should be provided in the pathology report to document the size of the specimen received for pathological examination. This may be useful in certain scenarios to direct the need for further surgery. For example, if initially only an omental biopsy was performed, further surgery may be undertaken to remove the remainder of the omentum. The size of the specimen is also helpful to determine the extent of sampling for histologic examination. No standardised guidelines have been developed for sampling omental specimens in cases of ovarian carcinoma or borderline tumours. However, in the setting of a grossly involved omentum, submitting one block for histologic examination is probably sufficient.<sup>38,39</sup> In patients who have received neoadjuvant chemotherapy, where histological assessment of tumour response to therapy is recommended (see **Note 15 RESPONSE TO NEOADJUVANT THERAPY**), examination of 4-6 blocks of omentum is suggested. For grossly negative omental specimens the sampling recommendations are variable – sampling of 3-5 blocks is recommended in one study,<sup>39</sup> other studies suggest at least one block for every 20 mm of maximum omental dimension.<sup>40</sup> Taking this information into account, 4-6 blocks in cases where the omentum is grossly negative in patients with an ovarian carcinoma or borderline tumour is recommended.

The size of the largest omental tumour deposit should be recorded in the pathology report. This is critical for determining the pathological stage.<sup>3,13</sup> Microscopic tumour which is not grossly evident, macroscopically evident tumour  $\leq 20$  mm, and macroscopically evident tumour  $>20$  mm, correspond to FIGO Stages IIIA2, IIIB, and IIIC, respectively.<sup>13</sup>

 [Back](#)

## Note 7 – Block identification key (Non-core)

The origin/designation of all tissue blocks should be recorded, and it is preferable to document this information in the final pathology report. This is particularly important should the need for internal or external review arise. The reviewer needs to be clear about the origin of each block in order to provide an informed specialist opinion. If this information is not included in the final pathology report, it should be available on the laboratory computer system and relayed to the reviewing pathologist. It may be useful to have a digital image of the specimen and record of the origin of the tumour blocks in some cases.

Recording the origin/designation of tissue blocks also facilitates retrieval of blocks for further immunohistochemical or molecular analysis, research studies or clinical trials.

 [Back](#)

## Note 8 – Histological tumour type (Core)

All tubo-ovarian epithelial malignancies and borderline tumours should be typed according to the 2020 WHO Classification of Tumours, Female Genital Tumours, 5<sup>th</sup> edition (Tables 1-3).<sup>3</sup> There are five major histotypes of primary ovarian carcinoma: low grade serous, high grade serous, clear cell, endometrioid and mucinous.<sup>41-44</sup> There are also other uncommon minor types listed in the 2020 WHO Classification including malignant Brenner tumour, mesonephric-like and undifferentiated carcinoma.<sup>3</sup> As seromucinous carcinoma is considered a morphologic variant of endometrioid carcinoma, it has thus been removed from the updated 2020 WHO Classification.<sup>3</sup> Carcinomas formerly diagnosed as seromucinous carcinoma are now included in the endometrioid category. Carcinosarcoma is a mixed epithelial and mesenchymal malignancy but is included in the category of epithelial malignancies in this dataset and in the 2020 WHO Classification since most are of epithelial origin and histogenesis (epithelial mesenchymal transition).<sup>3,45</sup>

Although management of ovarian carcinoma is, at present, largely dependent on tumour stage and grade, accurate typing will almost certainly become more important in the future with the introduction of targeted therapies and specific treatments for different tumour types. This is in part because, although clinically often considered as one disease, there is an increasing realisation that the different histotypes of ovarian carcinoma have different origins, pathogenesis, are associated with distinct molecular alterations, and have a different natural history, response to traditional chemotherapy, and prognosis.<sup>41-44</sup> Tumour typing may also be important in identifying or initiating testing for an underlying genetic predisposition. For example, HGSC may be associated with underlying *BRCA1/2* mutation while endometrioid carcinomas can occur in patients with LS.<sup>46</sup> The most common ovarian carcinoma is HGSC (approximately 70%) followed by clear cell and endometrioid.<sup>47,48</sup> Mucinous and low grade serous are less common. Approximately 90% of advanced stage ovarian carcinomas (Stage III/IV) are high grade serous in type.<sup>47,48</sup> Most primary tubal carcinomas are high grade serous type.

Mixed ovarian carcinomas are now considered to be uncommon. It is recommended that all distinct morphological types in an ovarian carcinoma are documented, even if they comprise less than 10% of the neoplasm. As stated, mixed carcinomas in the ovary are uncommon, the most prevalent combination being clear cell and endometrioid (both of these tumour types often arise in endometriosis). Most neoplasms which were previously classified as mixed serous and endometrioid, and mixed serous and clear cell, represent HGSCs with pseudoendometrioid areas and areas of cytoplasmic clearing respectively. In such cases, immunohistochemical markers, especially WT1, may be useful (see **Note 18 ANCILLARY STUDIES**).

Borderline tumours should also be typed according to 2020 WHO Classification criteria.<sup>3</sup> The most common types are serous and mucinous. Seromucinous, endometrioid and Brenner types also occur. Clear cell borderline tumour should only be diagnosed with the greatest caution, being certain to exclude carcinoma.

**Table 1: World Health Organization classification of tumours of the ovary.<sup>3</sup>**

Descriptor			ICD-O codes <sup>a</sup>
<b>Epithelial tumours</b>			
Serous tumours	Borderline	Serous borderline tumour NOS	8442/1
	Malignant	Low grade serous carcinoma	8460/3
	Malignant	High grade serous carcinoma	8461/3
Mucinous tumours	Borderline	Mucinous borderline tumour	8472/1
	Malignant	Mucinous adenocarcinoma	8480/3
Endometrioid tumours	Borderline	Endometrioid tumour, borderline	8380/1
	Malignant	Endometrioid adenocarcinoma NOS	8380/3
Clear cell tumours	Borderline	Clear cell borderline tumour	8313/1
	Malignant	Clear cell adenocarcinoma NOS	8310/3
Seromucinous tumours	Borderline	Seromucinous borderline tumour	8474/1
Brenner tumours	Borderline	Brenner tumour, borderline malignancy	9000/1
	Malignant	Brenner tumour, malignant	9000/3
Other carcinomas	Malignant	Mesonephric-like adenocarcinoma	9111/3
	Malignant	Carcinoma, undifferentiated, NOS	8020/3
	Malignant	Dedifferentiated carcinoma	8020/3
	Malignant	Carcinosarcoma NOS	8980/3
	Malignant	Mixed cell adenocarcinoma	8323/3
<b>Neuroendocrine neoplasia</b>			
Carcinoid, NOS			8240/3
Small cell neuroendocrine carcinoma			8041/3
Large cell neuroendocrine carcinoma			8013/3
Carcinoma admixed with small cell neuroendocrine carcinoma <sup>b</sup>			8045/3
Carcinoma admixed with large cell neuroendocrine carcinoma <sup>b</sup>			8013/3

<sup>a</sup> These morphology codes are from the International Classification of Diseases for Oncology, third edition, second revision (ICD-O-3.2).<sup>49</sup> Behaviour is coded /0 for benign tumours; /1 for unspecified, borderline, or uncertain behaviour; /2 for carcinoma in situ and grade III intraepithelial neoplasia; and /3 for malignant tumours, primary site; and /6 for malignant tumours, metastatic site. This classification is modified from the previous WHO classification, taking into account changes in our understanding of these lesions. Incorporates all relevant changes from the 5<sup>th</sup> edition Corrigenda June 2021.<sup>4</sup>

<sup>b</sup> This terminology is synonymous with the ICD-O terminology of combined small/large cell neuroendocrine carcinomas.

© World Health Organization/International Agency for Research on Cancer. Reproduced with permission.

**Table 2: World Health Organization classification of tumours of the fallopian tube.<sup>3</sup>**

Descriptor		ICD-O codes <sup>a</sup>
<b>Epithelial tumours</b>		
Epithelial precursor lesion	Serous adenofibroma NOS	9014/0
Epithelial borderline tumour	Serous borderline tumour NOS	8442/1
Malignant epithelial tumours	High grade serous carcinoma	8461/3
	Endometrioid adenocarcinoma NOS	8380/3
	Carcinosarcoma NOS	8980/3

<b>Neuroendocrine neoplasia</b>	
Neuroendocrine tumour NOS	8240/3
Neuroendocrine tumour, grade 1	8240/3
Neuroendocrine tumour, grade 2	8249/3
Small cell neuroendocrine carcinoma	8041/3
Large cell neuroendocrine carcinoma	8013/3
Carcinoma admixed with small cell neuroendocrine carcinoma <sup>b</sup>	8045/3
Carcinoma admixed with large cell neuroendocrine carcinoma <sup>b</sup>	8013/3

<sup>a</sup> These morphology codes are from the International Classification of Diseases for Oncology, third edition, second revision (ICD-O-3.2).<sup>49</sup> Behaviour is coded /0 for benign tumours; /1 for unspecified, borderline, or uncertain behaviour; /2 for carcinoma in situ and grade III intraepithelial neoplasia; and /3 for malignant tumours, primary site; and /6 for malignant tumours, metastatic site. This classification is modified from the previous WHO classification, taking into account changes in our understanding of these lesions. Incorporates all relevant changes from the 5<sup>th</sup> edition Corrigenda June 2021.<sup>4</sup>

<sup>b</sup> This terminology is synonymous with the ICD-O terminology of combined small/large cell neuroendocrine carcinomas.

© World Health Organization/International Agency for Research on Cancer. Reproduced with permission.

**Table 3: World Health Organization classification of tumours of the peritoneum.<sup>3</sup>**

<b>Descriptor</b>	<b>ICD-O codes<sup>a</sup></b>
<b>Epithelial tumours (of Müllerian type)</b>	
Serous borderline tumour NOS	8442/1
Low grade serous carcinoma	8460/3
High grade serous carcinoma	8461/3
<b>Neuroendocrine neoplasia</b>	
Neuroendocrine tumour NOS	8240/3
Neuroendocrine tumour, grade 1	8240/3
Neuroendocrine tumour, grade 2	8249/3
Small cell neuroendocrine carcinoma	8041/3
Large cell neuroendocrine carcinoma	8013/3
Carcinoma admixed with small cell neuroendocrine carcinoma <sup>b</sup>	8045/3
Carcinoma admixed with large cell neuroendocrine carcinoma <sup>b</sup>	8013/3

<sup>a</sup> These morphology codes are from the International Classification of Diseases for Oncology, third edition, second revision (ICD-O-3.2).<sup>49</sup> Behaviour is coded /0 for benign tumours; /1 for unspecified, borderline, or uncertain behaviour; /2 for carcinoma in situ and grade III intraepithelial neoplasia; and /3 for malignant tumours, primary site; and /6 for malignant tumours, metastatic site. This classification is modified from the previous WHO classification, taking into account changes in our understanding of these lesions. Incorporates all relevant changes from the 5<sup>th</sup> edition Corrigenda June 2021.<sup>4</sup>

<sup>b</sup> This terminology is synonymous with the ICD-O terminology of combined small/large cell neuroendocrine carcinomas.

© World Health Organization/International Agency for Research on Cancer. Reproduced with permission.

 **Back**

## Note 9 – Pattern of invasion (Non-core)

It is controversial as to whether the pattern of invasion in Stage I mucinous ovarian carcinoma has prognostic significance; therefore this is a non-core element.<sup>50-55</sup> The expansile/confluent/non-destructive pattern of invasion is characterised by architecturally complex glands, cysts or papillae lined by atypical epithelium with minimal to no intervening stroma. The destructive/infiltrative pattern is characterised by haphazardly arranged glands, tubules, nests and cords of malignant cells infiltrating stroma with an associated oedematous, inflammatory or desmoplastic response. While several studies have shown the expansile pattern heralds a better prognosis,<sup>50-52,54-57</sup> a population-based registry study of mucinous ovarian carcinomas was not able to prognosticate utilising the distinction between the two patterns of invasion.<sup>53</sup> It is recommended that the pattern of invasion in mucinous ovarian carcinomas be recorded. The focus of invasion should measure >5 mm in greatest linear extent; otherwise, this should be considered microinvasion or microinvasive carcinoma.

↑ Back

## Note 10 – Carcinosarcoma components (Non-core)

There is little published evidence suggesting any prognostic significance of the different morphological components within ovarian carcinosarcomas (although some prognostic evidence exists for uterine carcinosarcomas).<sup>58-60</sup> In view of the paucity of studies, the ICCR Ovary Carcinoma DAC recommends that it would be useful to record the percentage of the epithelial and mesenchymal elements as well as the components of the epithelial and mesenchymal (homologous or heterologous) elements. This is a recommendation rather than a requirement as collection of these data may be informative for the future prognosis and management of these neoplasms.<sup>58-60</sup>

↑ Back

## Note 11 – Histological tumour grade (Core and Non-core)

Histological grade is part of current European Society for Medical Oncology (ESMO)-European Society of Gynaecological Oncology (ESGO) management guidelines for endometrioid and mucinous carcinomas.<sup>61</sup> Serous carcinomas are now classified as low grade serous or high grade serous,<sup>3</sup> and despite the names including the term grade, these are two different histotypes rather than low grade and high grade variants of the same tumour type. Hence, grading does not apply to serous carcinomas. Clear cell carcinomas, un-/dedifferentiated carcinomas, anaplastic carcinomas, carcinosarcomas and mesonephric-like carcinomas are aggressive tumours and grading does not apply. There is no grading system for malignant Brenner tumours. If chemotherapy has been administered, tumour grading (and typing) may need to be based on the pre-chemotherapy biopsy.

The independent prognostic significance of grade for ovarian endometrioid carcinomas has only recently been validated.<sup>62</sup> The 1988 FIGO grading system is widely used for grading endometrioid carcinomas of ovarian and endometrial origin.<sup>13</sup> The FIGO grading system is based on architecture; tumours with <5% non-squamous solid component are grade 1, those with 5-50% solid areas are grade 2, and tumours with >50% of solid architecture are classified as grade 3.<sup>13</sup> When grade 1 and 2 tumours show severe nuclear atypia in the majority of the tumour cells (grade 3 nuclei), the histological grade is increased by one.<sup>13,63</sup>

Dedifferentiation in endometrioid carcinoma, sometimes with Switch/Sucrose non-fermenting (SWI/SNF) alterations, results in highly aggressive behaviour and such tumours are high grade by definition.<sup>64</sup> A significant majority of ovarian endometrioid carcinomas are grade 1 and 2. However, there is a subset of grade 3 endometrioid carcinomas which should be diagnosed with caution, since a significant proportion of such tumours are in fact HGSC with so called SET features (solid, pseudoendometrioid, transitional cell). IHC is useful in this regard (see **Note 18 ANCILLARY STUDIES**). The interobserver reproducibility of grading is limited

and several studies have attempted to improve on it.<sup>65-70</sup> There are shortcomings of a primarily architecturally based grading system. Certain growth patterns of endometrioid carcinoma such as spindled with bland nuclear features may be over-graded. On the contrary, tumours with non-solid architecture but high grade nuclear atypia may be under-graded. For example, in a recent study a number of p53 abnormal (p53abn) ovarian endometrioid carcinomas with aggressive course were graded as 1.<sup>62</sup>

As compared to the FIGO grading system,<sup>13</sup> the Silverberg grading system<sup>71</sup> was found to correlate better with survival in a multivariate analysis, although outcome in ovarian endometrioid carcinoma is mostly dictated by stage.<sup>63</sup> The Silverberg system (Table 4) takes into account nuclear atypia and mitotic activity in addition to architecture. Thus, the scores for architecture (majority glandular=1, papillary=2, solid=3), nuclear atypia (mild=1, moderate=2, severe=3), mitotic activity per mm<sup>2</sup> of tumour area or in 10 high power fields (HPF) (based on each HPF being 0.345 mm<sup>2</sup> in area, as per the original study;<sup>71</sup> 0-3 mitotic figures/mm<sup>2</sup> (or 0 to 9 mitotic figures per 10 HPF) =1, 3-7 mitotic figures/mm<sup>2</sup> (or 10 to 24 mitotic figures per 10 HPF) =2, and >7 mitotic figures/mm<sup>2</sup> (or ≥25 mitotic figures per 10 HPF) =3) are added to obtain a score for determining the final grade (G1: 3 to 5, G2: 6 to 7, G3: 8 to 9). The better performance of the Silverberg system was attributed to the better separation of grade 2 from the grade 3 tumours, which had a poor outcome.<sup>63</sup>

**Table 4: The Silverberg grading system.**<sup>71</sup>

Criterion	Score
<b>Architecture (majority pattern)</b>	
Glandular	1
Papillary	2
Solid	3
<b>Nuclear atypia</b>	
Mild	1
Moderate	2
Severe	3
<b>Mitotic count per mm<sup>2</sup></b>	
<3 mitotic figures/mm <sup>2</sup>	1
3-7 mitotic figures/mm <sup>2</sup>	2
>7 mitotic figures/mm <sup>2</sup>	3
<b>Final Grade</b>	<b>Total Score</b>
Grade 1	3-5
Grade 2	6-7
Grade 3	8-9

The DAC agrees that there is insufficient evidence for a change in the grading system of endometrioid carcinomas and continues to recommend the FIGO grading system.<sup>13</sup>

In addition to grading, molecular subtype assignment may further improve outcome prediction in the same way as for endometrioid carcinoma of the uterus; this is done with IHC for MMR proteins and p53 and by sequencing for exonuclease domain mutations (EDM) of *Polymerase epsilon (POLE)*.<sup>62,72</sup>

Some management guidelines for mucinous carcinomas require grading.<sup>61</sup> The DAC previously suggest that if grading of mucinous carcinomas is undertaken (a non-core element rather than a core element), the same grading system for endometrioid carcinomas should be used. However, a recent study showed no prognostic significance of the FIGO grading system and reemphasised that mucinous carcinomas only rarely show a solid growth pattern.<sup>73</sup> In this study, the Silverberg grade was significantly associated with survival, although all mucinous carcinomas were graded as grade 1 or 2 by the Silverberg system, and none as grade 3.<sup>73</sup> The DAC now recommends the Silverberg grading system<sup>71</sup> for mucinous carcinomas as a non-core reporting element.

The same study also proposed a growth-based grading system based on the pattern of invasion.<sup>73</sup> Expansile/confluent invasion or infiltrative invasion  $\leq 10\%$  of the tumour is graded as 1 while infiltrative invasion  $>10\%$  is graded as 2.<sup>73</sup> This was significantly associated with survival in univariable analysis in this relatively small study of 46 cases.<sup>74</sup> This corroborates earlier studies showing that while infiltrative invasion is associated with higher stage, it also predicts higher risk of recurrence at Stage I.<sup>53,57,74,75</sup> It is important to note, however, that an infiltrative pattern of invasion is a characteristic feature of metastatic mucinous carcinoma. In one study, the infiltrative pattern of invasion lost its significant association with survival after metastatic carcinomas to the ovary were excluded.<sup>76</sup> If an infiltrative/destructive pattern is present, metastatic carcinoma should carefully be ruled out. The quantification of the infiltrative component as focal ( $\leq 10\%$ ) or diffuse ( $>10\%$ ) may be recorded to allow more data to be gathered for future studies.

 [Back](#)

## Note 12 – Borderline tumour - special features (Core and Non-core)

Terminology for ovarian borderline tumours has evolved over several years.<sup>40,77</sup> The preferred terminology is borderline tumour, for example serous or mucinous borderline tumour, and this has been endorsed in the 2020 WHO Classification.<sup>3</sup> Serous borderline tumours can be of typical or micropapillary subtypes, as per the latest WHO Classification.<sup>3</sup> For mucinous, endometrioid, clear cell, Brenner, and seromucinous tumours, the designation ‘borderline tumour’ is also used in the 2020 WHO Classification.<sup>3</sup> The terms ‘low malignant potential’ or ‘atypical proliferative’ are not recommended.<sup>3</sup> Synonyms formerly used for seromucinous borderline tumours include endocervical-type mucinous borderline tumour, Müllerian mucinous borderline tumour, and atypical proliferative (borderline) Müllerian tumour.<sup>78</sup>

Determining the lowest threshold for the diagnosis of a borderline tumour in the setting of a cystadenoma/cystadenofibroma with minimal epithelial proliferation can be subjective and quantitative criteria have been suggested: cystadenomas/cystadenofibromas with qualitatively sufficient epithelial stratification/complexity involving  $\geq 10\%$  of the epithelial volume are designated as borderline tumours arising within a cystadenoma/cystadenofibroma.<sup>40</sup> A borderline tumour in which the epithelial stratification/complexity involves  $<10\%$  of the epithelial volume should be diagnosed as cystadenoma/cystadenofibroma with focal epithelial proliferation.

As serous borderline tumour can exhibit variable degrees of micropapillary or cribriform architecture, a diagnosis of micropapillary subtype of serous borderline tumour is based on the presence of  $\geq 5$  mm of confluent micropapillary (defined as micropapillae five times as long as they are wide) or cribriform growth.<sup>3</sup>

A standardised quantitative criterion for distinguishing microinvasion from frankly invasive carcinoma within a borderline tumour has not been established, with varying definitions used in different studies, including 1, 2, 3, 5 and 10 mm<sup>2</sup> as the upper limits of microinvasion.<sup>40,77,79</sup> The 2020 WHO Classification uses 5 mm<sup>2</sup> as a cut-off.<sup>3</sup> Some groups distinguish two patterns of stromal invasion in serous tumours which quantitatively falls short of frankly invasive carcinoma ( $<5$  mm) - conventional ‘microinvasion’ (isolated and/or small clusters of eosinophilic cells and/or small papillae cytologically similar to the non-invasive component within clear lacunar spaces) and ‘microinvasive carcinoma’ (glandular or micropapillary patterns qualitatively analogous to low grade serous carcinoma (LGSC)).<sup>40,77</sup> However, other investigators do not advocate this distinction. Due to insufficient numbers of cases in the literature, definitive conclusions regarding the clinical significance of this distinction cannot be drawn.<sup>77,80</sup> Analogous to the situation for serous tumours, some investigators advocate the separation of ‘microinvasion’ from ‘microinvasive carcinoma’ in mucinous borderline tumours while others use these two terms interchangeably.<sup>79</sup>

In mucinous borderline tumours, intraepithelial carcinoma is diagnosed in non-invasive foci with marked nuclear atypia, and is often associated with mitotic activity.<sup>40,79</sup> However, the reproducibility of this diagnosis has not been formally analysed. It has recently been suggested that p53 IHC could be used instead or in support of a diagnosis of intraepithelial carcinoma but this remains to be proven.<sup>81</sup> Intraepithelial carcinoma



for mucinous borderline tumours is a non-core item for reporting and the term intraepithelial carcinoma is not applied to other types of borderline tumour. Mucinous borderline tumours can be associated with mural nodules, which are classified as reactive sarcoma-like, anaplastic carcinoma, or sarcoma.

Sarcoma-like nodules are composed of a variable mixture of spindled/round mononucleated cells, often associated with marked inflammation.

Extra-ovarian implants occur in approximately 20% of serous borderline tumours and are more common with exophytic neoplasms. The most important adverse prognostic factor for ovarian serous borderline tumours in which there is extra-ovarian disease, is the presence of invasive implants, i.e., LGSC, in extra-ovarian tissues as this portends an adverse prognosis, with non-invasive implants having a favourable prognosis. Specifying the location and size of implants is important for determining the FIGO stage.<sup>13</sup> Non-invasive and invasive implants/LGSC may co-exist in the same specimen. Non-invasive implants are subclassified as epithelial or desmoplastic types.<sup>40</sup> Epithelial-type non-invasive implants resemble detached fragments of a serous borderline tumour involving extra-ovarian tissues. They do not exhibit infiltration of underlying tissue, and they are often present within mesothelial or epithelial-lined spaces although they may be adherent to the serosal surface. Desmoplastic non-invasive implants are composed of glands or papillary clusters within fibroblastic or granulation tissue-like stroma, but they do not exhibit infiltration of adjacent tissue. Often these are located on serosal surfaces or within septa in the omentum. Note that the presence of isolated individual or small clusters of eosinophilic epithelial cells within the stroma is generally considered to be within the spectrum of desmoplastic non-invasive implants rather than representing an invasive implant/LGSC.<sup>77</sup>

The most widely used criterion for diagnosing extra-ovarian LGSC/invasive implants in a patient with an ovarian serous borderline tumour is destructive invasion of underlying tissue.<sup>82</sup> Invasive implants often feature markedly crowded epithelial nests, glands or micropapillary clusters with a haphazard arrangement. The nests, glands and papillae are sometimes surrounded by clefts.<sup>40,77</sup>

In occasional cases, it may not be possible to definitively distinguish non-invasive from invasive implants/LGSC and the recommendation is to designate such implants as being of indeterminate type.<sup>83</sup> This terminology should only be used sparingly, and obtaining a specialist gynaecological pathology opinion and submitting additional sections for histological examination (if an omentectomy specimen), may be useful.

When invasive implants are present this should be diagnosed in the final pathology report as extra-ovarian LGSC;<sup>40,77,84</sup> this has been endorsed in the 2020 WHO Classification.<sup>3</sup> It is unclear whether invasive implants involving extra-ovarian sites in association with an ovarian serous borderline tumour represent metastases from the serous borderline tumour or an independent primary peritoneal tumour. A number of molecular studies analysing primary ovarian tumours with their associated implants have yielded varying results.<sup>77</sup> However, Ardighieri et al (2014) showed in a large population-based cohort has shown that the vast majority of implants are clonally related to the primary ovarian tumour.<sup>85</sup> Most of the cases from this study were non-invasive implants; however, all 10 invasive implants had the same mutational status (*KRAS* mutation, *BRAF* mutation, or wild-type *KRAS/BRAF*) as the corresponding serous borderline tumour, suggesting that invasive implants are clonally related to the primary ovarian tumour as opposed to representing independent primary peritoneal lesions.<sup>85</sup> Nevertheless, the number of invasive implants evaluated by molecular methods in the entire literature is limited. Carcinoma developing in patients with a previous diagnosis of serous borderline tumour are mostly LGSCs and most are clonally related to the serous borderline tumour i.e., represent tumour progression.<sup>86</sup> From a practical point of view, for cases of invasive implants in association with an ovarian tumour diagnosed as serous borderline tumour, it is recommended to consider additional sampling of ovarian tissue to demonstrate LGSC or micropapillary serous borderline tumour.<sup>87</sup>

Implants may also be encountered in the setting of seromucinous borderline tumours, and the same issues for serous tumours pertain. In general implants do not occur in the setting of mucinous, endometrioid, clear cell or Brenner borderline tumours.

 **Back**

## Note 13 – Serous tubal intraepithelial carcinoma (STIC) (Core)

Recently, STIC has been implicated in the pathogenesis of extra-uterine HGSC. The evidence indicating that STIC is a precursor of most HGSCs that were formerly considered to be of tubal, ovarian or primary peritoneal origin, as well as guidelines for assigning primary site in cases of advanced stage non-uterine, HGSC, have already been provided (see **Note 4 HISTOLOGICAL SITES OF TUMOUR INVOLVEMENT**). STIC comprises a population of cytologically malignant epithelial cells replacing the normal tubal mucosa, most commonly involving the fimbria, and characterised by increased nuclear to cytoplasmic ratio with rounded nuclei, loss of cell polarity, coarsely clumped chromatin, prominent nucleoli and absence of ciliated cells. Additional features that may be present include epithelial stratification, small fracture lines in the epithelium and tufting and exfoliation from the tubal surface of small epithelial cell clusters.

The diagnostic criteria for STIC have evolved and guidelines for diagnosis, which include the use of p53 and Ki-67 (MIB1) immunostaining, have been published.<sup>88-90</sup> Use of these criteria results in a high degree of inter-observer diagnostic agreement. In discrete fallopian tube mucosal lesions (usually, but not always, located in the fimbria) with high grade atypia in non-ciliated epithelium, the presence of abnormal p53 immunostaining (three mutation-type patterns: overexpression, complete absence and cytoplasmic) and high Ki-67 proliferation index ( $\geq 10\%$ ) support a diagnosis of STIC. Although immunostains are a valuable adjunct in the diagnosis of isolated lesions of the fallopian tube, they are usually not needed to diagnosis STIC in the context of advanced stage HGSC, where comparison between the tubal mucosal lesion and HGSC elsewhere reveals identical cytological features, with high grade atypia and numerous mitotic figures. Fallopian tube epithelial lesions with atypia that do not meet all the criteria for STIC (e.g., tubal intraepithelial lesion in transition/serous tubal intraepithelial lesion, synonymous terms for lesions that have some but not all features of STIC) are of uncertain significance at present with poor reproducibility and these are not reportable diagnoses and should generally not be used in routine practice; additional research is required to determine the clinical significance, if any, of such lesions. Similarly, p53 signatures should not be reported as a diagnosis.

Fallopian tube mucosal involvement by uterine or non-gynaecological primary tumours can occur and mimic STIC.<sup>91-93</sup> Most cases with unilateral or bilateral HGSC in the ovary and/or STIC or HGSC in the tube but with an endometrial serous intraepithelial or invasive carcinoma will represent adnexal metastases from an endometrial serous carcinoma (see **Note 18 ANCILLARY STUDIES**).<sup>94</sup> A diagnosis of STIC always requires consideration of clinical and pathological findings and the exclusion of secondary involvement of the fallopian tube.

 [Back](#)

## Note 14 – Peritoneal cytology (Core)

The results of peritoneal cytology (peritoneal washings or peritoneal fluid) are important for the substaging of Stage I ovarian tumours (borderline and malignant). Positive peritoneal washings in a Stage I tumour signify Stage IC3 in the 2014 FIGO Staging System.<sup>13</sup> In the previous 2006 FIGO Staging System,<sup>95</sup> the results of peritoneal cytology were used for the substaging of Stage II neoplasms, but this is no longer the case. Positive peritoneal cytology in a Stage I carcinoma may indicate the need for adjuvant therapy in certain cases. Cells of LGSC and serous borderline tumour cannot be reliably distinguished in a cytology specimen; in such cases, the cytology findings should be correlated with the histopathological findings.

 [Back](#)

## Note 15 – Response to neoadjuvant therapy (Non-core)

Histological assessment of chemotherapy response is only applicable to HGSC at this time. An initial study has tested and validated the prognostic significance of chemotherapy response criteria, and assessed reproducibility in two independent series of tubo-ovarian HGSC.<sup>96,97</sup> This three-tier scoring system (the Chemotherapy Response Score (CRS)) is reproducible, simple to apply in practice, and has been validated in an international multicentre study.<sup>98</sup> This is the grading system currently recommended by the DAC. The method is as follows:

1. Scoring should be carried out on a single haematoxylin and eosin (H&E)-stained section (refer to discussion of omental sampling in Note 6 Macroscopic description of omentum).
2. A single block of involved omental tissue that shows the least response to chemotherapy should be selected (if there is no residual omental tumour a CRS score of 3 is given - see Table 5).
3. The amount of viable tumour should be assessed; this may or may not show degenerative changes in the form of nuclear atypia, smudging of the nuclear chromatin and cytoplasmic clearing.
4. The presence of fibrosis may be helpful in marking the site of previous tumour infiltration:
  - a. When found in the absence of tumour, fibrosis is likely to indicate regression.
  - b. If fibrosis occurs in association with tumour, this may simply reflect tumour-associated desmoplasia rather than regression.
  - c. However, when fibrosis in association with tumour is accompanied by an inflammatory response (so-called 'fibro-inflammatory' response – fibrosis with associated macrophages and a mixed population of inflammatory cells), this indicates regression.
  - d. Psammoma bodies may mark the site of previous tumour and can sometimes appear more numerous because their density increases in areas where tumour has disappeared.
5. As a guide, >95% of tumour should be viable for a score of 1, and <5% for a score of 3.
6. In studies to date using this system or a closely related system, a difference in prognosis was shown only when tumours with a CRS score of 1 or 2 were compared with those having a CRS score of 3.<sup>96,97</sup> However, the DAC recommends use of the three-tier system to gather more data for future studies.
7. Note that this system has only been applied to HGSCs to date.
8. If the omental tissue appears normal, with neither tumour cells nor fibrosis, it is important to ascertain that there was omental involvement prior to the start of chemotherapy, that has completely regressed, by review of the clinical and radiological findings, before assigning a CRS score of 3. If there was no omental involvement prior to starting chemotherapy, then a CRS score cannot be applied.

**Table 5: Chemotherapy response score (CRS).<sup>96</sup>**

Score	Criterion	Tumour regression
1	Mainly viable tumour with no or minimal regression-associated fibro-inflammatory changes <sup>a</sup> limited to a few foci	No definite or minimal tumour response identified
2	Multifocal or diffuse regression-associated fibro-inflammatory changes, <sup>a</sup> with viable tumour ranging from diffuse sheets, streaks or nodules, to extensive regression with multifocal but easily identifiable residual tumour.	Moderate response identified
3	Mainly regression, with few irregularly scattered individual tumour cells or cell groups (all measuring less than 2 mm), or no residual tumour identified.	Marked response with no or minimal residual cancer

<sup>a</sup> Regression associated fibro-inflammatory changes: fibrosis associated with macrophages, including foam cells, mixed inflammatory cells and psammoma bodies; to be distinguished from tumour-related inflammation or desmoplasia.

 [Back](#)

## Note 16 – Lymph node status (Core)

In the revised 2014 FIGO Staging System, metastases involving retroperitoneal lymph nodes, in the absence of peritoneal spread above the pelvic brim or distant metastases, represent Stage IIIA1 disease.<sup>13</sup> This stage is further subdivided into Stages IIIA1(i) and IIIA1(ii) for nodal metastases  $\leq 10$  mm and  $>10$  mm, respectively. Formerly, regional node metastases were a criterion for Stage IIIC disease and this amendment is based upon evidence that patients with only nodal metastases (in the absence of peritoneal disease) have a relatively favourable outcome - although it should be noted that the data are based mainly on cases of HGSC.<sup>99,100</sup> Positive extra-abdominal lymph nodes including inguinal metastases represent Stage IVB disease.

International Federation of Gynaecology and Obstetrics (FIGO) specifically restricts the definition of Stage IIIA1 disease to retroperitoneal lymph nodes (pelvic and para-aortic) but does not indicate how tumour spread to intraperitoneal nodes (such as those in the mesentery or omentum) should be interpreted, although it would be very unusual to have isolated nodal metastases at these sites.<sup>13</sup> According to FIGO (personal communication), this should be regarded as intra-abdominal disease, i.e., Stage IIIC.<sup>101,102</sup> At present there are also limited data to justify the subdivision of Stage IIIA1 according to the size of the nodal metastases.<sup>13</sup> It is also not clear how the extent of nodal involvement ( $\leq 10$  mm or  $>10$  mm) should be measured if the diagnosis is based only upon cytological sampling. According to FIGO (personal communication), this should be regarded as Stage IIIA(i) disease.

Data on lymph node involvement in borderline ovarian tumours is largely restricted to tumours of serous subtype where approximately 25% of fully staged cases will show positive nodes.<sup>103,104</sup> While this finding does not appear to influence overall survival, cases with nodular epithelial tumour aggregates  $>1$  mm in extent may show decreased disease-free survival.<sup>105</sup> Rarely, LGSC appears to develop within the lymph nodes of patients with ovarian serous borderline tumours.<sup>106</sup>

According to TNM8,<sup>107</sup> nodal involvement should be recorded as the presence of isolated tumour cells (ITC,  $<0.2$  mm), micrometastases (MIC, 0.2-2 mm), or macrometastases (MAC,  $>2$  mm).

 [Back](#)

## Note 17 – Coexistent pathology/Precursor lesions (Non-core)

Borderline and malignant endometrioid, clear cell and seromucinous ovarian tumours may arise from endometriosis. Thus, the presence of endometriosis, although not of prognostic or therapeutic significance, particularly if contiguous with the tumour, may assist in determining the histotype in problematic cases.<sup>108,109</sup>

 [Back](#)

## Note 18 – Ancillary studies (Non-core)

Morphology remains the mainstay in ovarian carcinoma diagnosis. Diagnostic ancillary testing is currently based primarily on IHC. Diagnostic immunohistochemical markers may assist in establishing a diagnosis of a primary ovarian carcinoma or aid in histotyping. It is beyond the scope of this dataset to present a detailed analysis (sensitivity, specificity, cut-off interpretation) but the most commonly used first-line immunohistochemical panels are discussed. In general, panels of markers are better than reliance on individual markers and it should be remembered that no marker is totally specific or sensitive for any tumour type. Unexpected positive and negative staining reactions may occur. Therefore, the results of immunohistochemical studies should always be interpreted in conjunction with the clinical, gross and microscopic features.<sup>109,110</sup>

The choice of ancillary tests for the distinction of a primary ovarian carcinoma from a metastatic malignancy (Table 6) depends on its morphological context and can be problematic particularly on small or cytological specimens.

**Table 6: Ancillary tests to distinguish primary ovarian carcinoma from a metastasis.**

Comparator #1	Comparator #2	Expressed/abnormal in comparator #1	Expressed/abnormal in comparator #2	References
Primary ovarian carcinoma	Benign mesothelial proliferation	Claudin 4, B72.3, Ber-EP4	Desmin	111-117
Primary ovarian carcinoma	Mesothelioma	Claudin 4, B72.3, Ber-EP4, Estrogen receptor (ER) <sup>a</sup>	Calretinin, BAP1	112,118-120
Ovarian endometrioid carcinoma	Lower gastrointestinal tract (colorectal and appendiceal)	CK7, PAX8 <sup>b</sup> , ER <sup>a</sup>	SATB2, CK20	121
Ovarian endometrioid carcinoma	Sex cord stromal tumour	EMA, CK7	Inhibin, Calretinin, SF1	122
Ovarian mucinous carcinoma	Lower gastrointestinal tract (colorectal and appendiceal)	CK7	SATB2, CK20	36,37,121
Ovarian mucinous carcinoma	Endocervical adenocarcinoma (human papilloma virus (HPV)-associated)		P16, HPV-PCR	123,124
Tubo-ovarian high grade serous carcinoma	Metastatic breast carcinoma	PAX8, WT1	GATA3	125
Tubo-ovarian high grade serous carcinoma	Endometrial serous carcinoma	WT1, p53	p53	33,126

<sup>a</sup> ER is absent in ovarian clear cell and mucinous carcinomas as well about 20% of endometrioid and high grade serous carcinomas.

<sup>b</sup> PAX8 is absent in 15% of ovarian endometrioid carcinomas.

In the distinction between a primary ovarian carcinoma and a benign mesothelial proliferation, a first line panel of claudin 4, B72.3 and desmin is slightly better than the traditional panel of MOC31 (or BerEP4), estrogen receptor (ER) and calretinin.<sup>114</sup> Claudin 4 can be superior to MOC31, BerEP4, or PAX8.<sup>116</sup> Expression of PAX8 in reactive mesothelial proliferations has been noted.<sup>117,127-129</sup> However, claudin 4 or BP72.3 may not be widely available. Desmin is an excellent second marker for differentiating primary ovarian carcinoma from reactive mesothelial proliferation,<sup>111</sup> which outperforms calretinin (positive, at least focally, in some serous carcinomas). WT1 is consistently positive in both serous and mesothelial proliferations but the combination of WT1 expression with abnormal p53 is characteristic of tubo-ovarian HGSC, although some mesotheliomas can harbor a *TP53* mutation. If mesothelioma is in the differential diagnosis, BAP1 should be added. Bernardi et al (2020) showed that claudin 4 expression was completely sensitive and specific for metastatic carcinoma versus mesothelioma.<sup>112</sup>

Metastatic colorectal adenocarcinomas may mimic an endometrioid carcinoma or a mucinous neoplasm, either borderline or malignant. In the distinction between an ovarian endometrioid carcinoma and a metastatic colorectal adenocarcinoma, the following panel of markers may assist: CK7, CK20, PAX8, ER and SATB2.

Endometrioid carcinoma may closely mimic an ovarian sex cord-stromal tumour, either a granulosa cell tumour or a Sertoli cell tumour. Conversely, some Sertoli-Leydig cell tumours have a pseudoendometrioid appearance and can mimic an endometrioid neoplasm.<sup>130</sup> Markers which are useful to distinguish between them include inhibin, calretinin and SF-1 versus EMA, PAX8, BerEP4 and CK7.<sup>130-135</sup>

Simultaneous involvement of the endometrium and ovaries by an endometrioid carcinoma is not uncommon.<sup>136,137</sup> IHC and molecular testing are of little value in ascertaining the relationship between the tumours as synchronous dual primaries versus metastasis since it has been shown that in almost all such the tumours are clonally related.<sup>138-140</sup> However, an indolent behaviour can be anticipated if both tumours are low grade; the endometrial tumour shows less than 50% myometrial invasion; substantial lymphovascular invasion is absent; and only the endometrium and one ovary and no other site is involved.<sup>141</sup> These tumours can be designated as synchronous.

In the distinction between an ovarian mucinous carcinoma and a metastatic colorectal adenocarcinoma or appendiceal neoplasm, as well as the macroscopic and microscopic findings, with large size and unilaterality being more in keeping with primary ovarian mucinous carcinoma, a panel of CK7, CK20, CDX2 and SATB2 may assist.<sup>36,37,121</sup> The use of IHC to distinguish primary ovarian mucinous carcinoma from metastatic adenocarcinoma of upper gastrointestinal origin (pancreatic, hepatobiliary, gastric) is limited. An absence of staining with SMAD4 (DPC4) may suggest a pancreatic adenocarcinoma since staining of this nuclear transcription factor is lost in about 50% of pancreatic adenocarcinomas.<sup>142</sup> Conversely, DPC4 is expressed in virtually all primary ovarian mucinous neoplasms. Rarely, a metastatic human papillomavirus (HPV)-associated endocervical adenocarcinoma may mimic a primary ovarian mucinous or endometrioid neoplasm.<sup>143</sup> Diffuse p16 immunoreactivity in such cases may be useful in suggesting a metastatic cervical adenocarcinoma, but performing HPV testing is more specific.<sup>123,124,144</sup>

Metastatic triple negative ductal breast carcinomas may mimic a tubo-ovarian HGSC. In a patient with a history of breast carcinoma and germline *BRCA1/2* mutation who is found to have a pelvic mass or a disseminated peritoneal malignancy, most often this will represent a new tubo-ovarian HGSC. A panel of PAX8, WT1 and GATA3 is helpful.<sup>125,145-147</sup> However, in the setting of triple negative breast carcinomas, GATA3 expression is often limited or completely negative.

With a serous carcinoma involving the endometrium and one or both tubes/ovaries, correct site assignment becomes important because only tubo-ovarian HGSC are eligible for PARPi at this time, but this could change. WT1 and p53 staining may be of some value in distinguishing between an endometrial serous carcinoma with metastasis to the tube/ovary, a 'drop metastasis' in the endometrium from a tubo-ovarian HGSC or independent synchronous neoplasms. Differences in staining between the sites, especially with both markers, suggest the latter. Absence of WT1 staining is a relatively specific indicator of endometrial primary site because almost all tubo-ovarian HGSC show diffuse WT1 staining (approximately 2% show partial or complete absence).<sup>94,148</sup> On the contrary, while WT1 expression is consistent with a tubo-ovarian HGSC, approximately one third of endometrial serous carcinoma exhibit WT1 staining (often focal).<sup>33,94,126,148-153</sup>

While most primary ovarian carcinomas are straightforward to histotype on well sampled specimens, on occasion it is difficult to distinguish between a HGSC and a high grade endometrioid carcinoma (Table 7). The recommended panel is a combination of WT1 and p53.<sup>154</sup> Diffuse strong WT1 expression in combination with abnormal mutation-type p53 staining is highly sensitive and specific for HGSC. If it is not possible to distinguish between high grade serous and endometrioid carcinoma, these cases could be submitted for cancer susceptibility screening and predictive testing for both histotypes (*BRCA1/2* mutation testing and MMR protein expression). HGSC with clear cell areas and clear cell carcinoma can be distinguished by a combination of WT1, napsin A/HNF1B and ER.<sup>109</sup> HGSC can be distinguished from LGSC by p53 and from mucinous carcinoma by

WT1.<sup>155</sup> Endometrioid carcinoma can be distinguished from clear cell carcinoma by napsin A, HNF1B and progesterone receptor (PR).<sup>110</sup> Endometrioid and mucinous carcinomas can be distinguished by PR and vimentin.<sup>76,108,155</sup>

**Table 7: Ancillary tests to distinguish serous and endometrioid carcinomas.**

Comparator #1	Comparator #2	Expressed/abnormal in comparator #1	Expressed/abnormal in comparator #2	References
High grade serous carcinoma	Endometrioid carcinoma (grade 3)	WT1, p53		154
High grade serous carcinoma	Clear cell carcinoma	WT1, Estrogen receptor	Napsin A, HNF1B	109,156
High grade serous carcinoma	Low grade serous carcinoma	p53		155
High grade serous carcinoma	Mucinous carcinoma	WT1		109
Endometrioid carcinoma	Clear cell carcinoma	Progesterone receptor	Napsin A, HNF1B	157
Endometrioid carcinoma	Mucinous carcinoma	Progesterone receptor, Vimentin		76
Low grade serous carcinoma	Endometrioid, clear cell, mucinous	WT1		109

Biomarkers are not necessary if the features are unequivocally those of STIC, however if there is diagnostic uncertainty, both p53 and Ki-67 staining should be performed.<sup>158</sup> The cells must exhibit abnormal (mutation-type) p53 staining.<sup>159,160</sup> The Ki-67 proliferation index is increased, typically in the region of 40% to nearly 100% with most cases showing focal areas exceeding 70%. However, some cases of STIC exhibit a lower Ki-67 proliferation index and it has been suggested that at least 10% of the nuclei should be positive for a diagnosis of STIC in cases where IHC is undertaken (morphological features and aberrant p53 staining are also needed).<sup>158</sup>

While many prognostic biomarker studies have been published for HGSC, none provide sufficient stratification to influence management.

This is different for endometrioid carcinoma where three recent studies validated that the same molecular subtype assignment of their uterine counterparts showed prognostic stratification.<sup>62,72,161</sup> The four molecular subtypes are *POLE* mutated with the longest survival, mismatch repair deficient (MMRd) and no specific molecular profile (NSMP) cases with intermediate survival and p53abn cases with the shortest survival. In particular, assessing the latter may supplant grading. Assessing the MMR status also serves genetic LS screening and might provide predictive information. The NSMP group is the largest in ovarian endometrioid carcinoma, as it is in endometrial endometrioid carcinoma. Further stratification of this group might require other biomarkers. For example, PR expression status and/or *CTNNB1* mutation status both have been shown to be associated with survival across all ovarian endometrioid carcinomas, but have not been studied within the NSMP group.<sup>162-166</sup>

There are no validated prognostic biomarkers for ovarian clear cell or mucinous carcinoma. However, p53 status might inform about the course of mucinous borderline tumours. A recent study showed that p53abn mucinous borderline tumours were associated with a higher risk of death.<sup>167</sup> While there are no current therapeutic options for these patients, the converse information that p53 normal mucinous borderline tumours are at very low risk of disease progression can be useful in some clinical circumstances.<sup>81</sup>

Tubo-ovarian HGSCs with proven *BRCA1/2* mutations (germline or somatic) are likely to respond to PARPi. If modern IHC supported histotyping is performed, *BRCA1/2* mutations are confined to HGSC so *BRCA1/2* testing

can be restricted to this histotype.<sup>168</sup> Difficult cases (e.g., differential diagnosis with grade 3 endometrioid) can also be tested at the discretion of the pathologist. Several clinical trials showed effects of PARPi in the *BRCA1/2* wild-type but homologous repair deficient group.<sup>169</sup> It can be anticipated that eligibility for PARPi will be expanded. Several competing proprietary homologous repair deficiency (HRD) tests (mutational signatures, genomic scars etc.) are being marketed, with an alternative approach to testing being an expanded gene panel that includes proven HRD genes such as *RAD51C*, *RAD51D*, *BRIP1*, *PALB2* among others.<sup>170</sup>

The United States Food and Drug Administration (FDA) has approved immunotherapy for MMRd tumours irrespective of site. Universal MMRd testing is recommended for ovarian endometrioid carcinoma to screen for hereditary LS.<sup>171</sup> While MMRd is rarely observed in prototypical clear cell carcinomas, some cases with ambiguous morphology between endometrioid and clear cell carcinoma are MMRd and even with the use of diagnostic IHC panels these cases might be diagnosed as clear cell carcinoma. While MMRd in clear cell carcinoma is uncommon, all cases reported in the literature were proven or probable LS.<sup>172-175</sup> Hence, if funding is not restricted, clear cell carcinoma might also be tested for LS. Alternatively, a features-based screening for clear cell carcinoma is possible (ambiguous/mixed morphology between endometrioid/clear cell carcinoma, microcystic architecture and intratumoural stromal lymphocytic infiltrate, presence of synchronous endometrial and ovarian carcinoma).<sup>172</sup> Age cut-offs have limited value.

No other molecular targeted therapies are approved. Hormone receptor expression assessment might be requested by oncologists before commencing hormonal therapy for endometrioid or LGSC.<sup>165</sup> No predictive cut-offs have been established and the expression of ER and PR should be reported descriptively. About 5% of LGSCs harbor a *BRAF* V600E mutation and case reports suggest promising results with BRAF inhibitors.<sup>176</sup> *HER2* amplifications occur in 18% of ovarian mucinous<sup>177</sup> and 7-14% of ovarian clear cell carcinoma.<sup>178</sup>

Ovarian carcinomas represent a heterogeneous group of tumours. In recent years, molecular pathology has been instrumental in demonstrating that ovarian carcinomas are not a single entity, but a group of tumours with diverse morphology, natural history, and pathogenesis.<sup>179</sup> While molecular investigations at present do not have a significant role in diagnosis, prediction of prognosis or determination of treatment in ovarian, tubal and peritoneal carcinomas, this may change in the future, especially with the introduction of PARPi therapy for HGSC.

High grade serous carcinomas (HGSCs) are chromosomally unstable tumours, in which *TP53* mutations are ubiquitous. Germline or sporadic, genetic or epigenetic, alterations in *BRCA1* and *BRCA2* also occur. A pathogenetic model has been proposed, starting with early *TP53* alteration, followed by *BRCA1* loss, leading to deficiency in homologous recombination repair of double strand breaks, triggering chromosomal instability with gene copy number variation. The Cancer Genome Atlas (TCGA) performed an integrated genomic analysis of 489 high grade ovarian serous carcinomas.<sup>180</sup> Mutations in *TP53* were seen in 96% of the cases. There was a low prevalence, but there were statistically recurrent somatic mutations in nine further genes, including *NF1*, *BRCA1*, *BRCA2*, *RB1* and *CDK12*. Copy number alterations and promoter hypermethylation events were detected in 168 genes. The most common amplifications were detected in *CCNE1*, *MYC* and *MECOM*. Deletions were identified in *RB1*, *NF1* and *PTEN*. Hierarchical clustering analysis identified four transcriptional subtypes, three microRNA subtypes, four promoter methylation subtypes, and a transcriptional signature associated with survival. In 33% of the tumours, alterations in *BRCA* genes, either somatic or germline mutations or promoter hypermethylation were present. Defects in DNA repair by homologous recombination, secondary to mutations in *BRCA1*, *BRCA2* or related genes, or by mechanisms not yet elucidated, are seen in approximately 50% of HGSCs, and HRD is a predictive marker for response to PARPi therapy.<sup>181,182</sup> At present there is no single agreed upon predictive assay for HRD/prediction of response to PARPi.

Low grade serous carcinomas (LGSCs) are closely related to serous borderline tumours, and show frequent mutations in the MAPK pathway (*KRAS*, *BRAF*, *NRAS*), prognostically unfavourable alterations in *CDK2A* and mutations in *USP9X*<sup>164,183</sup> PR is an unfavourable prognostic marker.<sup>165</sup>

The molecular events in endometrioid carcinoma are similar to the uterine counterpart. The main molecular alterations are: *CTNNB1* mutation (50%), microsatellite instability (13%), and mutations in the *PTEN* (20%), *KRAS*,



*PIK3CA*, *TP53*, and *POLE* genes. The molecular subtypes from the uterine counterpart are equally prognostic in ovarian endometrioid carcinomas, as discussed earlier.<sup>62,184</sup>

Clear cell carcinoma shows frequent *ARID1A* and *PIK3CA* mutations. Alterations in *KRAS* and *TP53* are unusual. *HER2* amplifications are uncommon.

Mucinous carcinomas frequently harbour genomic loss of *CDKN2A*, *KRAS* and *TP53* mutations often co-occurring and *HER2* amplifications.<sup>185</sup> In mucinous tumours with areas of carcinoma admixed with foci of benign or borderline mucinous tumour, *KRAS* mutations have been demonstrated in all components, suggesting that this represents an early event during tumourigenesis. *TP53* mutations are implicated in the progression from mucinous borderline tumour to carcinoma and, as discussed earlier, a recent study demonstrated a higher risk of death for patient with mucinous borderline tumour harbouring a *TP53* mutation.<sup>167</sup>

 [Back](#)

## Note 19 – Provisional pathological staging (Core)

Tumour stage is amongst the strongest prognostic factors in tubo-ovarian carcinoma.<sup>186</sup> Patients with localised, regional and distant disease have been shown to have 5 year relative survival rates of 92%, 72% and 27%, based on United States figures from 2014.<sup>187</sup> Therefore pathological staging must be provided on the pathology report and is a core element.

The term ‘provisional pathological staging’ is used in this dataset to indicate that the stage that is provided may not represent the final tumour stage which should be determined at the multidisciplinary tumour board meeting where all the pathological, clinical and radiological features are available.<sup>13,107,188,189</sup>

All ovarian carcinomas and borderline tumours, as well as carcinomas of the fallopian tube and peritoneum should be staged.<sup>13,189</sup> The latest version of either FIGO<sup>13,189</sup> or TNM staging,<sup>107,188</sup> or both, can be used depending on local preferences. The FIGO system is in widespread use internationally and is the system used in most clinical trials and research studies. However, Union for International Cancer Control (UICC) or American Joint Committee on Cancer (AJCC) 8<sup>th</sup> edition TNM Staging Systems are used or mandated in many parts of the world.<sup>107,188</sup> With regards to updating of staging systems, there is collaboration between FIGO and those agencies responsible for TNM with an agreement to adopt FIGO staging but no coordination of timing of revisions; generally, what happens is that following the introduction of a new FIGO Staging System, this is incorporated into TNM (both UICC and AJCC versions) at a later date. Apart from minor discrepancies in terminology, the UICC and AJCC 8<sup>th</sup> edition systems are broadly concurrent.<sup>107,188</sup>

For reasons of comparability, FIGO continue to classify umbilical metastases as Stage IVB (personal communication).<sup>13,189</sup> It is recommended that these cases are reported separately to keep track of and obtain further insight into the prognostic value of umbilical involvement in tubo-ovarian cancer and whether this may be best regarded as Stage III.

A tumour should be staged following diagnosis using various appropriate modalities (clinical, radiological, pathological). While the original tumour stage should not be altered following treatment, TNM systems allow staging to be performed on a resection specimen following non-surgical treatment (for example chemotherapy, radiotherapy); in such cases, if a stage is being provided on the pathology report (this is optional), it should be prefixed by ‘y’ to indicate that this is a post-therapy stage.

The reference document TNM Supplement: A commentary on uniform use, 5<sup>th</sup> edition (C Wittekind et al. editors) may be of assistance when staging.<sup>190</sup>

 [Back](#)

## References

- 1 Merlin T, Weston A and Tooher R (2009). Extending an evidence hierarchy to include topics other than treatment: revising the Australian 'levels of evidence'. *BMC Med Res Methodol* 9:34.
- 2 International Collaboration on Cancer Reporting (2017). *Mesothelioma in the Pleura and Peritoneum Histopathology Reporting Guide 2nd edition*. Available from: <http://www.iccr-cancer.org/datasets/published-datasets/thorax/mesothelioma> (Accessed 16th June 2021).
- 3 WHO Classification of Tumours Editorial Board (2020). *Female Genital Tumours, WHO Classification of Tumours, 5th Edition, Volume 4*. IARC Press, Lyon.
- 4 WHO Classification of Tumours Editorial Board (2021). *Female Genital Tumours, WHO Classification of Tumours, 5th Edition, Volume 4 - Corrigenda June 2021*. Available from: <https://publications.iarc.fr/Book-And-Report-Series/Who-Classification-Of-Tumours/Female-Genital-Tumours-2020> (Accessed 16th June 2021).
- 5 Folkins AK and Longacre TA (2013). Hereditary gynaecological malignancies: advances in screening and treatment. *Histopathology* 62:2-30.
- 6 Alsop K, Fereday S, Meldrum C, deFazio A, Emmanuel C, George J, Dobrovic A, Birrer MJ, Webb PM, Stewart C, Friedlander M, Fox S, Bowtell D and Mitchell G (2012). BRCA mutation frequency and patterns of treatment response in BRCA mutation-positive women with ovarian cancer: a report from the Australian Ovarian Cancer Study Group. *J Clin Oncol* 26:2654-2663.
- 7 Soslow RA, Han G, Park KJ, Garg K, Olvera N, Spriggs DR, Kauff ND and Levine DA (2012). Morphologic patterns associated with BRCA1 and BRCA2 genotype in ovarian carcinoma. *Mod Pathol* 25:625-636.
- 8 Fujiwara M, McGuire VA, Felberg A, Sieh W, Whittemore AS and Longacre TA (2012). Prediction of BRCA1 germline mutation status in women with ovarian cancer using morphology-based criteria. Identification of a BRCA1 ovarian cancer phenotype. *Am J Surg Pathol* 36:1170-1177.
- 9 Dean E, El-Helw L and Hasan J (2010). Targeted therapies in epithelial ovarian cancer. *Cancers (Basel)* 2:88-113.
- 10 Long B, Lilyquist J, Weaver A, Hu C, Gnanaolivu R, Lee KY, Hart SN, Polley EC, Bakkum-Gamez JN, Couch FJ and Dowdy SC (2019). Cancer susceptibility gene mutations in type I and II endometrial cancer. *Gynecol Oncol* 152(1):20-25.
- 11 Chui MH, Gilks B, Cooper K and Clarke BA (2013). Identifying Lynch syndrome in patients with ovarian carcinoma: the significance of tumor type. *Adv Anat Pathol* 20:378-386.
- 12 Lee S, Piskorz AM, Le Page C, Mes Masson AM, Provencher D, Huntsman D, Chen W, Swanson PE, Gilks CB and Köbel M (2016). Calibration and optimization of p53, WT1, and napsin A immunohistochemistry ancillary tests for histotyping of ovarian carcinoma: Canadian Immunohistochemistry Quality Control (CIQC) experience. *Int J Gynecol Pathol* 35(3):209-221.
- 13 Prat J and FIGO Committee on Gynecologic Oncology (2014). Staging classification for cancer of the ovary, fallopian tube, and peritoneum. *Int J Gynaecol Obstet*. 124:1-5.
- 14 Vergote I, De Brabanter J, Fyles A, Bertelsen K, Einhorn N, Sevelde P, Gore ME, Kaern J, Verrelst H, Sjøvall K, Timmerman D, Vandewalle J, Van Gramberen M and Tropé CG (2001). Prognostic importance of degree of differentiation and cyst rupture in stage I invasive epithelial ovarian carcinoma. *Lancet*. 357:176-182.

- 15 Bakkum-Gamez JN, Richardson DL, Seamon LG, Aletti GD, Powless CA, Keeney GL, O'Malley DM and Cliby WA (2009). Influence of intraoperative capsule rupture on outcomes in stage I epithelial ovarian cancer. *Obstet Gynecol* 113:11-17.
- 16 Seidman JD, Yemelyanova AV, Khedmati F, Bidus MA, Dainty L, Boice CR and Cosin JA (2010). Prognostic factors for stage I ovarian carcinoma. *Int J Gynecol Pathol* 29:1-7.
- 17 Dembo AJ, Davy M, Stenwig AE, Berle EJ, Bush RS and Kjorstad K (1990). Prognostic factors in patients with stage I epithelial ovarian cancer. *Obstet Gynecol* 75:263-273.
- 18 Ahmed FY, Wiltshaw E, A'Hern RP, Nicol B, Shepherd J, Blake P, Fisher C and Gore ME (1996). Natural history and prognosis of untreated stage I epithelial ovarian carcinoma. *J Clin Oncol* 14:2968-2975.
- 19 Matsuo K, Machida H, Yamagami W, Ebina Y, Kobayashi Y, Tabata T, Kaneuchi M, Nagase S, Enomoto T and Mikami M (2019). Intraoperative capsule rupture, postoperative chemotherapy, and survival of women with Stage I epithelial ovarian cancer. *Obstet Gynecol* 134(5):1017-1026.
- 20 Timmers PJ, Zwinderman AH, Teodorovic I, Vergote I and Trimbos JB (2009). Clear cell carcinoma compared to serous carcinoma in early ovarian cancer: same prognosis in a large randomized trial. *Int J Gynecol Cancer* 19:88-93.
- 21 Higashi M, Kajiyama H, Shibata K, Mizuno M, Mizuno K, Hosono S, Kawai M, Nakanishi T, Nagasaka T and Kikkawa F (2011). Survival impact of capsule rupture in stage I clear cell carcinoma of the ovary in comparison with other histological types. *Gynecol Oncol* 123:474-478.
- 22 Gottheil S and McGee J (2013). Endometrioid ovarian carcinoma during pregnancy presenting with acute rupture. *J Obstet Gynaecol Can* 35:1020-1022.
- 23 Colgan TJ, Murphy J, Cole DE, Narod S and Rosen B (2001). Occult carcinoma in prophylactic oophorectomy specimens: prevalence and association with BRCA germline mutation status. *Am J Surg Pathol* 25:1283-1289.
- 24 Piek JM, van Diest PJ, Zweemer RP, Jansen JW, Poort-Keesom RJ, Menko FH, Gille JJ, Jongasma AP, Pals G, Kenemans P and Verheijen RH (2001). Dysplastic changes in prophylactically removed fallopian tubes of women predisposed to developing ovarian cancer. *J Pathol*. 195:451-456.
- 25 Kindelberger DW, Lee Y, Miron A, Hirsch MS, Feltmate CM, Medeiros F, Callahan MJ, Garner EO, Gordon RW, Birch C, Berkowitz RS, Muto MG and Crum CP (2007). Intraepithelial carcinoma of the fimbria and pelvic serous carcinoma: Evidence for a causal relationship. *Am J Surg Pathol* 31:161-169.
- 26 Kuhn E, Meeker A, Wang TL, Sehdev AS, Kurman RJ and Shih I-M (2010). Shortened telomeres in serous tubal intraepithelial carcinoma: an early event in ovarian high-grade serous carcinogenesis. *Am J Surg Pathol* 34:829-836.
- 27 Kuhn E, Bahadirli-Talbot A, Kurman R, Sehdev AS, Wang T-L and Shih I-M (2013). CCNE1 amplification may precede centrosome number abnormality in progression from serous tubal intraepithelial carcinoma to high-grade serous carcinoma. *Mod Pathol* 26:283A.
- 28 Garg K and Rabban J (2013). Practical value of systematic and complete examination of fallopian tubes in unselected women undergoing salpingectomy for benign indications: results of a prospective study. *Mod Pathol* 26:276A.
- 29 Przybycin CG, Kurman RJ, Ronnett BM, Shih I-M and Vang R (2010). Are all pelvic (nonuterine) serous carcinomas of tubal origin? *Am J Surg Pathol* 34:1407-1416.

- 30 Singh N, Gilks CB, Wilkinson N and McCluggage WG (2014). Assignment of primary site in high-grade serous tubal, ovarian and peritoneal carcinoma: a proposal. *Histopathology* 65:149-154.
- 31 Wethington SL, Park KJ, Soslow RA, Kauff ND, Brown CL, Dao F, Otegbeye E, Sonoda Y, Abu-Rustum NR, Barakat RR, Levine DA and Gardner GJ (2013). Clinical outcome of isolated serous tubal intraepithelial carcinomas (STIC). *Int J Gynecol Cancer* 23:1603-1611.
- 32 Bloss JD, Liao S, Buller RE, Manetta A, Berman ML, McMeekin S, Bloss LP and DiSaia PJ (1993). Extraovarian peritoneal serous papillary carcinoma: a case-control retrospective comparison to papillary adenocarcinoma of the ovary. *Gynecol Oncol* 50:347-351.
- 33 Kommos F, Faruqi A, Gilks CB, Lamshang Leen S, Singh N, Wilkinson N and McCluggage WG (2017). Uterine serous carcinomas frequently metastasize to the fallopian tube and can mimic serous tubal intraepithelial carcinoma. *Am J Surg Pathol* 41(2):161-170.
- 34 Gramlich T, Austin RM and Lutz M (1990). Histologic sampling requirements in ovarian carcinoma: a review of 51 tumors. *Gynecol Oncol* 38:249-256.
- 35 Silverberg SG, Bell DA, Kurman RJ, Seidman JD, Prat J, Ronnett BM, Coperland L, Silva E, Gorstein F and Young RH (2004). Borderline ovarian tumors: key points and workshop summary. *Hum Pathol* 35:910-917.
- 36 Hu J, Khalifa RD, Roma AA and Fadare O (2018). The pathologic distinction of primary and metastatic mucinous tumors involving the ovary: A re-evaluation of algorithms based on gross features. *Ann Diagn Pathol* 37:1-6.
- 37 Pinto PB, Derchain SF and Andrade LA (2012). Metastatic mucinous carcinomas in the ovary: a practical approach to diagnosis related to gross aspects and to immunohistochemical evaluation. *Int J Gynecol Pathol* 31(4):313-318.
- 38 Doig T and Monaghan H (2006). Sampling the omentum in ovarian neoplasia: when one block is enough. *Int J Gynecol Cancer* 16:36-40.
- 39 Usubütün A, Ozseker HS, Himmetoglu C, Balci S and Ayhan A (2007). Omentectomy for gynecologic cancer: how much sampling is adequate for microscopic examination? *Arch Pathol Lab Med* 131:1578-1581.
- 40 Seidman JD, Soslow RA, Vang R, Berman JJ, Stoler MH, Sherman ME, Oliva E, Kajdacsy-Balla A, Berman DM and Copeland LJ (2004). Borderline ovarian tumors: diverse contemporary viewpoints on terminology and diagnostic criteria with illustrative images. *Hum Pathol* 35:918-933.
- 41 McCluggage WG (2008). My approach to and thoughts on typing of ovarian carcinomas. *J Clin Pathol* 61:152-163.
- 42 Shih IM and Kurman RJ (2004). Ovarian tumorigenesis. A proposed model based on morphological and molecular genetic analysis. *Am J Pathol* 164:1511-1518.
- 43 Gilks CB (2004). Subclassification of ovarian surface epithelial tumors based on correlation of histologic and molecular pathologic data. *Int J Gynecol Pathol* 23:200-205.
- 44 Soslow RA (2008). Histologic subtypes of ovarian carcinoma: an overview. *Int J Gynecol Pathol* 27:161-174.

- 45 McCluggage WG (2002). Malignant biphasic uterine tumours: carcinosarcomas or metaplastic carcinomas? *J Clin Pathol* 55:321-325.
- 46 Downes MR, Allo G, McCluggage WG, Sy K, Ferguson SE, Aronson M, Pollett A, Gallinger S, Bilbily E, Shaw P and Clarke BA (2014). Review of findings in prophylactic gynaecologic specimens in Lynch syndrome with literature review and recommendations for grossing. *Histopathology* 65:228-239.
- 47 Seidman JD, Horkayne-Szakaly I, Haiba M, Boice CR, Kurman RJ and Ronnett BM (2004). The histologic type and stage distribution of ovarian carcinomas of surface epithelial origin. *Int J Gynecol Pathol* 23:41-44.
- 48 Köbel M, Kalloger SE, Huntsman DG, Santos JL, Swenerton KD, Seidman JD and Gilks CB (2010). Differences in tumor type in low-stage versus high-stage ovarian carcinomas. *Int J Gynecol Pathol* 29:203-211.
- 49 Fritz A, Percy C, Jack A, Shanmugaratnam K, Sobin LH, Parkin DM, Whelan SL (eds) (2020). *International Classification of Diseases for Oncology, Third edition, Second revision ICD-O-3.2*. Available from: [http://www.iacr.com.fr/index.php?option=com\\_content&view=category&layout=blog&id=100&Itemid=577](http://www.iacr.com.fr/index.php?option=com_content&view=category&layout=blog&id=100&Itemid=577) (Accessed 21st January 2021).
- 50 Rodríguez IM and Prat J (2002). Mucinous tumors of the ovary: a clinicopathologic analysis of 75 borderline tumors (of intestinal type) and carcinomas. *Am J Surg Pathol*. 26:139-152.
- 51 Lee KR and Scully RE (2000). Mucinous tumors of the ovary: a clinicopathologic study of 196 borderline tumors (of intestinal type) and carcinomas, including an evaluation of 11 cases with 'pseudomyxoma peritonei'. *Am J Surg Pathol* 24:1447-1446.
- 52 Nomura K and Aizawa S (2000). Noninvasive, microinvasive, and invasive mucinous carcinomas of the ovary: a clinicopathologic analysis of 40 cases. *Cancer* 89:1541-1546.
- 53 Chen S, Leitao MM, Tornos C and Soslow RA (2005). Invasion patterns in stage I endometrioid and mucinous ovarian carcinomas: a clinicopathologic analysis emphasizing favorable outcomes in carcinomas without destructive stromal invasion and the occasional malignant course of carcinomas with limited destructive stromal invasion. *Mod Pathol* 18:903-911.
- 54 Ludwick C, Gilks CB, Miller D, Yaziji H and Clement PB (2005). Aggressive behavior of stage I ovarian mucinous tumors lacking extensive infiltrative invasion: a report of four cases and review of the literature. *Int J Gynecol Pathol* 24:205-217.
- 55 Tabrizi AD, Kalloger SE, Köbel M, Cipollone J, Roskelley CD, Mehl E and Gilks CB (2010). Primary ovarian mucinous carcinoma of intestinal type: significance of pattern of invasion and immunohistochemical expression profile in a series of 31 cases. *Int J Gynecol Pathol* 29:99-10.
- 56 Hada T, Miyamoto M, Ishibashi H, Matsuura H, Sakamoto T, Kakimoto S, Iwahashi H, Tsuda H and Takano M (2021). Survival and biomarker analysis for ovarian mucinous carcinoma according to invasive patterns: retrospective analysis and review literature. *J Ovarian Res* 14(1):33.
- 57 Muyldermans K, Moerman P, Amant F, Leunen K, Neven P and Vergote I (2013). Primary invasive mucinous ovarian carcinoma of the intestinal type: importance of the expansile versus infiltrative type in predicting recurrence and lymph node metastases. *Eur J Cancer* 49(7):1600-1608.
- 58 Ariyoshi K, Kawauchi S, Kaku T, Nakano H and Tsuneyoshi M (2000). Prognostic factors in ovarian carcinosarcoma: a clinicopathological and immunohistochemical analysis of 23 cases. *Histopathology* 37:427-436.

- 59 Rutledge TL, Gold MA, McMeekin DS, Huh WK, Powell MA, Lewin SN, Mutch DG, Johnson GA, Walker JL and Mannel RS (2006). Carcinosarcoma of the ovary-a case series. *Gynecol Oncol* 100:128-132.
- 60 Lu CH, Chen IH, Chen YJ, Wang KL, Qiu JT, Lin H, Lin WC, Liou WS, Huang YF, Lin YS, Tee YT and Hung YC (2014). Primary treatment and prognostic factors of carcinosarcoma of the ovary, fallopian tube, and peritoneum: a Taiwanese Gynecologic Oncology Group Study. *Int J Gynecol Cancer* 24:506-512.
- 61 Colombo N, Sessa C, du Bois A, Ledermann J, McCluggage WG, McNeish I, Morice P, Pignata S, Ray-Coquard I, Vergote I, Baert T, Belaroussi I, Dashora A, Olbrecht S, Planchamp F and Querleu D (2019). ESMO-ESGO consensus conference recommendations on ovarian cancer: pathology and molecular biology, early and advanced stages, borderline tumours and recurrent disease. *Ann Oncol* 30(5):672-705.
- 62 Krämer P, Talhouk A, Brett MA, Chiu DS, Cairns ES, Scheunhage DA, Hammond RFL, Farnell D, Nazeran TM, Grube M, Xia Z, Senz J, Leung S, Feil L, Pasternak J, Dixon K, Hartkopf A, Krämer B, Brucker S, Heitz F, du Bois A, Harter P, Kommoss FKF, Sinn HP, Heublein S, Kommoss F, Vollert HW, Manchanda R, de Kroon CD, Nijman HW, de Bruyn M, Thompson EF, Bashashati A, McAlpine JN, Singh N, Tinker AV, Staebler A, Bosse T, Kommoss S, Köbel M and Anglesio MS (2020). Endometrial cancer molecular risk stratification is equally prognostic for endometrioid ovarian carcinoma. *Clin Cancer Res* 26(20):5400-5410.
- 63 Parra-Herran C, Bassiouny D, Vicus D, Olkhov-Mitsel E, Cesari M, Ismiil N and Nofech-Mozes S (2019). FIGO versus Silverberg grading systems in ovarian endometrioid carcinoma: a comparative prognostic analysis. *Am J Surg Pathol* 43(2):161-167.
- 64 Tessier-Cloutier B, Coatham M, Carey M, Nelson GS, Hamilton S, Lum A, Soslow RA, Stewart CJ, Postovit LM, Köbel M and Lee CH (2020). SWI/SNF-deficiency defines highly aggressive undifferentiated endometrial carcinoma. *J Pathol Clin Res* 7(2):144-153.
- 65 Zaino RJ, Kurman RJ, Diana KL and Morrow CP (1995). The utility of the revised International Federation of Gynecology and Obstetrics histologic grading system. A Gynecologic Oncology Group Study. *Cancer* 75:81-86.
- 66 Taylor RR, Zeller J, Lieberman RW and O'Connor DM (1999). An analysis of two versus three grades for endometrial carcinoma. *Gynecol Oncol* 92:119-123.
- 67 Takeshima N, Hirai Y and Hasumi K (1998). Prognostic validity of neoplastic cells with notable nuclear atypia in endometrial cancer. *Obstet Gynecol* 92:119-123.
- 68 Lax SF, Kurgan RJ, Pizer ES, Wu L and Ronnett BM (2000). A binary architectural grading system for uterine endometrial endometrioid carcinoma has superior reproducibility compared with FIGO grading and identifies subsets of advance-stage tumors with favorable and unfavorable prognosis. *Am J Surg Pathol* 24:1201-1208.
- 69 Scholten AN, Smit VT, Beerman H, van Putten WL and Creutzberg CL (2004). Prognostic significance and interobserver variability of histologic grading system for endometrial carcinoma. *Cancer* 100:764-772.
- 70 Alkushi A, Abdul-Rahman ZH, Lim P, Schulzer M, Coldman A, Kalloger SE, Miller D and Gilks CB (2005). Description of a novel system for grading of endometrial carcinoma and comparison with existing grading systems. *Am J Surg Pathol* 29:295-304.

- 71 Shimizu Y, Kamoi S, Amada S, Akiyama F and Silverberg SG (1998). Toward the development of a universal grading system for ovarian epithelial carcinoma: testing of a proposed system in a series of 461 patients with uniform treatment and follow-up. *Cancer* 82:893-901.
- 72 Leskela S, Romero I, Rosa-Rosa JM, Caniego-Casas T, Cristobal E, Pérez-Mies B, Gutierrez-Pecharroman A, Santón A, Ojeda B, López-Reig R, Palacios-Berraquero ML, Andrada E, Montes S, Pastor F, Gomez MC, López-Guerrero JA, Poveda A and Palacios J (2020). Molecular heterogeneity of endometrioid ovarian carcinoma: an analysis of 166 cases using the endometrial cancer subrogate molecular classification. *Am J Surg Pathol* 44(7):982-990.
- 73 Busca A, Nofech-Mozes S, Olkhov-Mitsel E, Gien LT, Bassiouny D, Mirkovic J, Djordjevic B and Parra-Herran C (2020). Histological grading of ovarian mucinous carcinoma - an outcome-based analysis of traditional and novel systems. *Histopathology* 77(1):26-34.
- 74 Khunamornpong S, Settakorn J, Sukpan K, Suprasert P and Siriaunkgul S (2014). Primary ovarian mucinous adenocarcinoma of intestinal type: a clinicopathologic study of 46 cases. *Int J Gynecol Pathol* 33(2):176-185.
- 75 Gouy S, Saidani M, Maulard A, Bach-Hamba S, Bentivegna E, Leary A, Pautier P, Devouassoux-Shisheboran M, Genestie C and Morice P (2018). Characteristics and prognosis of stage I ovarian mucinous tumors according to expansile or infiltrative type. *Int J Gynecol Cancer* 28(3):493-499.
- 76 Woodbeck R, Kelemen LE and Köbel M (2019). Ovarian endometrioid carcinoma misdiagnosed as mucinous carcinoma: an underrecognized problem. *Int J Gynecol Pathol* 38(6):568-575.
- 77 Bell DA, Longacre TA, Prat J, Kohn EC, Soslow RA, Ellenson LH, Malpica A, Stoler MH and Kurman RJ (2004). Serous borderline (low malignant potential, atypical proliferative) ovarian tumors: workshop perspectives. *Hum Pathol* 35:934-948.
- 78 Köbel M, Bell DA and Carcangiu ML (2014). Tumours of the ovary: Epithelial tumours- Seromucinous tumours. In: *World Health Organization Classification of Tumours of Female Reproductive Organs, 4th Edition*, Kurman RJ, Carcangiu ML, Herrington S and Young RH (eds), IARC Press, Lyon, France.
- 79 Ronnett BM, Kajdacsy-Balla A, Gilks CB, Merino MJ, Silva E, Werness BA and Young RH (2004). Mucinous borderline ovarian tumors: points of general agreement and persistent controversies regarding nomenclature, diagnostic criteria, and behavior. *Hum Pathol* 35:949-960.
- 80 McKenney JK, Balzer BL and Longacre TA (2006). Patterns of stromal invasion in ovarian serous tumors of low malignant potential (borderline tumors): a reevaluation of the concept of stromal microinvasion. *Am J Surg Pathol* 30:1209-1221.
- 81 Kang EY, Cheasley D, LePage C, Wakefield MJ, da Cunha Torres M, Rowley S, Salazar C, Xing Z, Allan P, Bowtell DDL, Mes-Masson AM, Provencher DM, Rahimi K, Kelemen LE, Fasching PA, Doherty JA, Goodman MT, Goode EL, Deen S, Pharoah PDP, Brenton JD, Sieh W, Mateoiu C, Sundfeldt K, Cook LS, Le ND, Anglesio MS, Gilks CB, Huntsman DG, Kennedy CJ, Traficante N, DeFazio A, Kaufmann S, Churchman M, Gourley C, Stephens AN, Meagher NS, Ramus SJ, Antill YC, Campbell I, Scott CL, Köbel M and Gorringer KL (2020). Refined cut-off for TP53 immunohistochemistry improves prediction of TP53 mutation status in ovarian mucinous tumors: implications for outcome analyses. *Mod Pathol*: DOI: 10.1038/s41379-41020-40618-41379.
- 82 Bell DA, Weinstock MA and Scully RE (1988). Peritoneal implants of ovarian serous borderline tumors. Histologic features and prognosis. *Cancer* 62:2212-2222.

- 83 Longacre TA, McKenney JK, Tazelaar HD, Kempson RL and Hendrickson MR (2005). Ovarian serous tumors of low malignant potential (borderline tumors): outcome-based study of 276 patients with long-term (> or =5-year) follow-up. *Am J Surg Pathol* 29:707-723.
- 84 Bell KA, Smith Sehdev AE and Kurman RJ (2001). Refined diagnostic criteria for implants associated with ovarian atypical proliferative serous tumors (borderline) and micropapillary serous carcinomas. *Am J Surg Pathol* 25:419-432.
- 85 Ardighieri L, Zeppernick F, Hannibal CG, Vang R, Cope L, Junge J, Kjaer SK, Kurman RJ and Shih I-M (2014). Mutational analysis of BRAF and KRAS in ovarian serous borderline (atypical proliferative) tumours and associated peritoneal implants. *J Pathol*. 232:16-22.
- 86 Chui MH, Xing D, Zeppernick F, Wang ZQ, Hannibal CG, Frederiksen K, Kjaer SK, Cope L, Kurman RJ, Shih IM, Wang TL and Vang R (2019). Clinicopathologic and molecular features of paired cases of metachronous ovarian serous borderline tumor and subsequent serous carcinoma. *Am J Surg Pathol* 43(11):1462-1472.
- 87 Seidman JD, Savage J, Krishnan J, Vang R and Kurman RJ (2020). Intratumoral heterogeneity accounts for apparent progression of noninvasive serous tumors to invasive low-grade serous carcinoma: a study of 30 low-grade serous tumors of the ovary in 18 patients with peritoneal carcinomatosis. *Int J Gynecol Pathol* 39(1):43-54.
- 88 Carlson JW, Jarboe EA, Kindelberger D, Nucci MR, Hirsch MS and Crum CP (2010). Serous tubal intraepithelial carcinoma: diagnostic reproducibility and its implications. *Int J Gynecol Pathol* 29:310-314.
- 89 Visvanathan K, Vang R, Shaw P, Gross A, Soslow R, Parkash V, Shih I-M. and Kurman RJ (2011). Diagnosis of serous tubal intraepithelial carcinoma (STIC) based on morphologic and immunohistochemical features. A reproducibility study. *Am J Surg Pathol* 35:1766-1775.
- 90 Vang R, Visvanathan K, Gross A, Maambo E, Gupta M, Kuhn E, Fanghong R, Ronnett BM, Seidman JD, Yemelyanova A, Shih I-M., Shaw PA, Soslow RA and Kurman RJ (2012). Validation of an algorithm for the diagnosis of serous tubal intraepithelial carcinoma. *Int J Gynecol Pathol* 31:243-253.
- 91 Tang S, Onuma K, Deb P, Wang E, Lytwyn A, Monalisa S and Daya D (2012). Frequency of serous tubal intraepithelial carcinoma in various gynecologic malignancies: a study of 300 consecutive cases. *Int J Gynecol Pathol* 31:103-110.
- 92 Jarboe EA, Miron A, Carlson JW, Hirsch MS, Kindelberger D, Mutter GL, Crum CP and Nucci MR (2009). Coexisting intraepithelial serous carcinomas of the endometrium and fallopian tube: frequency and potential significance. *Int J. Gynecol Pathology* 28:308-315.
- 93 Rabban JT, Vohra P and Zaloudek C (2014). Intramucosal growth in fallopian tube fimbriae by tumors of non-gynecologic origin may mimic serous tubal intraepithelial carcinoma and tubal mucinous metaplasia. *Mod Pathol* 27:302A.
- 94 McCluggage WG (2004). WT1 is of value in ascertaining the site of origin of serous carcinomas within the female genital tract. *Int J Gynecol Pathol* 23:97-99.
- 95 Heintz A, Odicino F, Maisonneuve P, Quinn MA, Benedet JL, Creasman WT, Ngan H, Pecorelli S and Beller U (2006). Carcinoma of the Ovary. *Int J Gynaecol Obstet* 95 Suppl 1:S161-s192.



- 96 Boehm S, Said I, Faruqi A, Gilks CB and Singh N (2014). Development of a response scoring system to quantify the effect of neoadjuvant chemotherapy in ovarian cancer - ovarian cancer response scoring (OCRS) study. *Mod Pathol* 27:276A.
- 97 Sassen S, Schmalfeldt B, Avril N, Kuhn W, Busch R, Hofler H, Fend F and Nahring J (2007). Histopathologic assessment of tumor regression after neoadjuvant chemotherapy in advanced-stage ovarian cancer. *Hum Pathol* 38:926-934.
- 98 Cohen PA, Powell A, Böhm S, Gilks CB, Stewart CJR, Meniawy TM, Bulsara M, Avril S, Brockbank EC, Bosse T, de Azevedo Focchi GR, Ganesan R, Glasspool RM, Howitt BE, Kim HS, Lee JY, Le ND, Lockley M, Manchanda R, Mandalia T, McCluggage WG, McNeish I, Midha D, Srinivasan R, Tan YY, van der Griend R, Yunokawa M, Zannoni GF and Singh N (2019). Pathological chemotherapy response score is prognostic in tubo-ovarian high-grade serous carcinoma: A systematic review and meta-analysis of individual patient data. *Gynecol Oncol* 154(2):441-448.
- 99 Berek JS. (2009). Lymph node-positive stage IIIC ovarian cancer. A separate entity? *Int J Gynecol Cancer* 19:S18-20.
- 100 Bakker R, Gershenson D, Fox P, Vu K, Zenali M and Silva E (2014). Stage IIIC ovarian/ peritoneal serous carcinoma: a heterogenous group of patients with different prognosis. *Int J Gynecol Cancer* 33:302-308.
- 101 Berretta R, Capozzi VA, Sozzi G, Volpi L, Ceni V, Melpignano M, Giordano G, Marchesi F, Monica M, Di Serio M, Riccò M and Ceccaroni M (2018). Prognostic role of mesenteric lymph nodes involvement in patients undergoing posterior pelvic exenteration during radical or supra-radical surgery for advanced ovarian cancer. *Arch Gynecol Obstet* 297(4):997-1004.
- 102 Gallotta V, Fanfani F, Fagotti A, Chiantera V, Legge F, Gueli Alletti S, Nero C, Margariti AP, Papa V, Alfieri S, Ciccarone F, Scambia G and Ferrandina G (2014). Mesenteric lymph node involvement in advanced ovarian cancer patients undergoing rectosigmoid resection: prognostic role and clinical considerations. *Ann Surg Oncol* 21(7):2369-2375.
- 103 Fadare O (2009). Recent developments on the significance and pathogenesis of lymph node involvement in ovarian serous tumors of low malignant potential (borderline tumors). *Int J Gynecol Cancer* 19:103-108.
- 104 Morice P, Uzan C, Fauvet R, Gouy S, Duvillard P and Darai E (2012). Borderline ovarian tumour: pathological diagnostic dilemma and risk factors for invasive or lethal recurrence. *Lancet Oncol* 13:e103-115.
- 105 McKenney JK, Balzer BL and Longacre TA (2006). Lymph node involvement in ovarian serous tumors of low malignant potential (borderline tumors): pathology, prognosis, and proposed classification. *Am J Surg Pathol* 30:614-624.
- 106 Djordjevic B and Malpica A (2010). Lymph node involvement in ovarian serous tumors of low malignant potential: a clinicopathologic study of thirty-six cases. *Am J Surg Pathol* 34(1):1-9.
- 107 Brierley JD, Gospodarowicz MK and Wittekind C (eds) (2016). *Union for International Cancer Control. TNM Classification of Malignant Tumours, 8th Edition*, Wiley, USA.
- 108 Köbel M, Luo L, Grevers X, Lee S, Brooks-Wilson A, Gilks CB, Le ND and Cook LS (2019). Ovarian carcinoma histotype: strengths and limitations of integrating morphology with immunohistochemical predictions. *Int J Gynecol Pathol* 38(4):353-362.

- 109 Köbel M, Rahimi K, Rambau PF, Naugler C, Le Page C, Meunier L, de Ladurantaye M, Lee S, Leung S, Goode EL, Ramus SJ, Carlson JW, Li X, Ewanowich CA, Kelemen LE, Vanderhyden B, Provencher D, Huntsman D, Lee CH, Gilks CB and Mes Masson AM (2016). An immunohistochemical algorithm for ovarian carcinoma typing. *Int J Gynecol Pathol* 35(5):430-441.
- 110 Köbel M, Luo L, Grevers X, Lee S, Brooks-Wilson A, Gilks CB, Le ND and Cook LS (2019). Ovarian carcinoma histotype: strengths and limitations of integrating morphology with immunohistochemical predictions. *Int J Gynecol Pathol* 38(4):353-362.
- 111 Attanoos RL, Griffin A and Gibbs AR (2003). The use of immunohistochemistry in distinguishing reactive from neoplastic mesothelium. A novel use for desmin and comparative evaluation with epithelial membrane antigen, p53, platelet-derived growth factor-receptor, P-glycoprotein and Bcl-2. *Histopathology* 43(3):231-238.
- 112 Bernardi L, Bizzarro T, Pironi F, Szymczuk S, Buda R, Fabbri E, Di Claudio G and Rossi G (2020). The "Brescia panel" (Claudin-4 and BRCA-associated protein 1) in the differential diagnosis of mesotheliomas with epithelioid features versus metastatic carcinomas. *Cancer Cytopathol*: DOI: 10.1002/cncy.22368.
- 113 Facchetti F, Lonardi S, Gentili F, Bercich L, Falchetti M, Tardanico R, Baronchelli C, Lucini L, Santin A and Murer B (2007). Claudin 4 identifies a wide spectrum of epithelial neoplasms and represents a very useful marker for carcinoma versus mesothelioma diagnosis in pleural and peritoneal biopsies and effusions. *Virchows Arch* 451(3):669-680.
- 114 Ordóñez NG (2006). Value of immunohistochemistry in distinguishing peritoneal mesothelioma from serous carcinoma of the ovary and peritoneum: a review and update. *Adv Anat Pathol* 13(1):16-25.
- 115 Ordóñez NG (2013). Value of PAX8, PAX2, claudin-4, and h-caldesmon immunostaining in distinguishing peritoneal epithelioid mesotheliomas from serous carcinomas. *Mod Pathol* 26(4):553-562.
- 116 Patel A, Borczuk AC and Siddiqui MT (2020). Utility of Claudin-4 versus BerEP4 and B72.3 in pleural fluids with metastatic lung adenocarcinoma. *J Am Soc Cytopathol* 9(3):146-151.
- 117 Tandon RT, Jimenez-Cortez Y, Taub R and Borczuk AC (2018). Immunohistochemistry in peritoneal mesothelioma: a single-center experience of 244 cases. *Arch Pathol Lab Med* 142(2):236-242.
- 118 Hwang HC, Sheffield BS, Rodriguez S, Thompson K, Tse CH, Gown AM and Churg A (2016). Utility of BAP1 immunohistochemistry and p16 (CDKN2A) FISH in the diagnosis of malignant mesothelioma in effusion cytology specimens. *Am J Surg Pathol* 40(1):120-126.
- 119 Kleinberg L, Holth A, Trope CG, Reich R and Davidson B (2008). Claudin upregulation in ovarian carcinoma effusions is associated with poor survival. *Hum Pathol* 39(5):747-757.
- 120 Ohta Y, Sasaki Y, Saito M, Kushima M, Takimoto M, Shiokawa A and Ota H (2013). Claudin-4 as a marker for distinguishing malignant mesothelioma from lung carcinoma and serous adenocarcinoma. *Int J Surg Pathol* 21(5):493-501.

- 121 Meagher NS, Wang L, Rambau PF, Intermaggio MP, Huntsman DG, Wilkens LR, El-Bahrawy MA, Ness RB, Odunsi K, Steed H, Herpel E, Anglesio MS, Zhang B, Lambie N, Swerdlow AJ, Lubiński J, Vierkant RA, Goode EL, Menon U, Toloczko-Grabarek A, Oszurek O, Bilic S, Talhouk A, García-Closas M, Wang Q, Tan A, Farrell R, Kennedy CJ, Jimenez-Linan M, Sundfeldt K, Etter JL, Menkiszak J, Goodman MT, Klonowski P, Leung Y, Winham SJ, Moysich KB, Behrens S, Kluz T, Edwards RP, Gronwald J, Modugno F, Hernandez BY, Chow C, Kelemen LE, Keeney GL, Carney ME, Natanzon Y, Robertson G, Sharma R, Gayther SA, Alsop J, Luk H, Karpinskyj C, Campbell I, Sinn P, Gentry-Maharaj A, Coulson P, Chang-Claude J, Shah M, Widschwendter M, Tang K, Schoemaker MJ, Koziak JM, Cook LS, Brenton JD, Daley F, Kristjansdottir B, Mateoiu C, Larson MC, Harnett PR, Jung A, deFazio A, Gorringer KL, Pharoah PDP, Minoo P, Stewart C, Bathe OF, Gui X, Cohen P, Ramus SJ and Köbel M (2019). A combination of the immunohistochemical markers CK7 and SATB2 is highly sensitive and specific for distinguishing primary ovarian mucinous tumors from colorectal and appendiceal metastases. *Mod Pathol* 32(12):1834-1846.
- 122 Zhao C, Bratthauer GL, Barner R and Vang R (2007). Comparative analysis of alternative and traditional immunohistochemical markers for the distinction of ovarian sertoli cell tumor from endometrioid tumors and carcinoid tumor: A study of 160 cases. *Am J Surg Pathol* 31(2):255-266.
- 123 Elishaev E, Gilks CB, Miller D, Srodon M, Kurman RJ and Ronnett BM (2005). Synchronous and metachronous endocervical and ovarian neoplasms: evidence supporting interpretation of the ovarian neoplasms as metastatic endocervical adenocarcinomas simulating primary ovarian surface epithelial neoplasms. *Am J Surg Pathol* 29(3):281-294.
- 124 Plaza JA, Ramirez NC and Nuovo GJ (2004). Utility of HPV analysis for evaluation of possible metastatic disease in women with cervical cancer. *Int J Gynecol Pathol* 23(1):7-12.
- 125 Espinosa I, Gallardo A, D'Angelo E, Mozos A, Lerma E and Prat J (2015). Simultaneous carcinomas of the breast and ovary: utility of Pax-8, WT-1, and GATA3 for distinguishing independent primary tumors from metastases. *Int J Gynecol Pathol* 34(3):257-265.
- 126 Chen W, Husain A, Nelson GS, Rambau PF, Liu S, Lee CH, Lee S, Duggan MA and Köbel M (2017). Immunohistochemical profiling of endometrial serous carcinoma. *Int J Gynecol Pathol* 36(2):128-139.
- 127 Chapel DB, Husain AN, Krausz T and McGregor SM (2017). PAX8 expression in a subset of malignant peritoneal mesotheliomas and benign mesothelium has diagnostic implications in the differential diagnosis of ovarian serous carcinoma. *Am J Surg Pathol* 41(12):1675-1682.
- 128 Xing D, Banet N, Sharma R, Vang R, Ronnett BM and Illei PB (2018). Aberrant Pax-8 expression in well-differentiated papillary mesothelioma and malignant mesothelioma of the peritoneum: a clinicopathologic study. *Hum Pathol* 72:160-166.
- 129 Xing D, Zheng G, Schoolmeester JK, Li Z, Pallavajjala A, Haley L, Conner MG, Vang R, Hung CF, Wu TC and Ronnett BM (2018). Next-generation sequencing reveals recurrent somatic mutations in small cell neuroendocrine carcinoma of the uterine cervix. *Am J Surg Pathol* 42(6):750-760.
- 130 McCluggage WG and Young RH (2007). Ovarian sertoli-leydig cell tumors with pseudoendometrioid tubules (pseudoendometrioid sertoli-leydig cell tumors). *Am J Surg Pathol* 31:592-597.
- 131 McCluggage WG (2000). Recent advances in immunohistochemistry in the diagnosis of ovarian neoplasms. *J Clin Pathol* 53:558-560.
- 132 McCluggage WG (2002). Recent advances in immunohistochemistry in gynaecological pathology. *Histopathology* 46:309-326.

- 133 McCluggage WG and Young RH (2005). Immunohistochemistry as a diagnostic aid in the evaluation of ovarian tumors. *Semin Diagn Pathol* 22:3-32.
- 134 Zhao C, Barner R, Vinh TN, McManus K, Dabbs D and Vang R (2008). SF-1 is a diagnostically useful immunohistochemical marker and comparable to other sex cord-stromal tumor markers for the differential diagnosis of ovarian Sertoli cell tumor. *Int J Gynecol Pathol* 27:507-514.
- 135 Zhao C, Vinh TN, McManus K, Dabbs D, Barner R and Vang R (2009). Identification of the most sensitive and robust immunohistochemical markers in different categories of ovarian sex cord-stromal tumors. *Am J Surg Pathol* 33:354-366.
- 136 Zaino R, Whitney C, Brady MF, DeGeest K, Burger RA and Buller RE (2001). Simultaneously detected endometrial and ovarian carcinoma: A prospective clinicopathologic study of 74 cases: a gynecologic oncology group study. *Gynecol Oncol* 83:355-362.
- 137 Ayhan A, Yalcin OT, Tuncer ZS, Gurgan T and Kucukali T (1992). Synchronous primary malignancies of the female genital tract. *Eur J Obstet Gynecol Reprod Biol* 45:63-66.
- 138 Niskakoski A, Pasanen A, Porkka N, Eldfors S, Lassus H, Renkonen-Sinisalo L, Kaur S, Mecklin JP, Bützow R and Peltomäki P (2018). Converging endometrial and ovarian tumorigenesis in Lynch syndrome: Shared origin of synchronous carcinomas. *Gynecol Oncol* 150(1):92-98.
- 139 Schultheis AM, Ng CK, De Filippo MR, Piscuoglio S, Macedo GS, Gatus S, Perez Mies B, Soslow RA, Lim RS, Viale A, Huberman KH, Palacios JC, Reis-Filho JS, Matias-Guiu X and Weigelt B (2016). Massively parallel sequencing-based clonality analysis of synchronous endometrioid endometrial and ovarian carcinomas. *J Natl Cancer Inst* 108(6):djv427.
- 140 Anglesio MS, Wang YK, Maassen M, Horlings HM, Bashashati A, Senz J, Mackenzie R, Grewal DS, Li-Chang H, Karnezis AN, Sheffield BS, McConechy MK, Kommos F, Taran FA, Staebler A, Shah SP, Wallwiener D, Brucker S, Gilks CB, Kommos S and Huntsman DG (2016). Synchronous endometrial and ovarian carcinomas: evidence of clonality. *J Natl Cancer Inst* 108(6):djv428.
- 141 Blake Gilks C and Singh N (2019). Synchronous carcinomas of endometrium and ovary: A pragmatic approach. *Gynecol Oncol Rep* 27:72-73.
- 142 Ji H, Isacson C, Seidman JD, Kurman RJ and Ronnett BM (2002). Cytokeratins 7 and 20, Dpc4 and MUC5AC in the distinction of metastatic mucinous carcinomas in the ovary from primary ovarian mucinous carcinomas: Dpc4 assists in identifying metastatic pancreatic carcinomas. *Int J Gynecol Pathol* 21:391-400.
- 143 Ronnett BM, Yemelyanova AV, Vang R, Gilks CB, Miller D, Gravitt PE and Kurman RJ (2008). Endocervical adenocarcinomas with ovarian metastases: analysis of 29 cases with emphasis on minimally invasive cervical tumors and the ability of the metastases to simulate primary ovarian neoplasms. *Am J Surg Pathol* 32:1835-1853.
- 144 Wentzensen N, du Bois A, Kommos S, Pfisterer J, von Knebel Doeberitz M, Schmidt D and Kommos F (2008). No metastatic cervical adenocarcinomas in a series of p16INK4a-positive mucinous or endometrioid advanced ovarian carcinomas: an analysis of the AGO Ovarian Cancer Study Group. *Int J Gynecol Pathol* 27(1):18-23.
- 145 Nonaka D, Chiriboga L and Soslow RA (2008). Expression of pax8 as a useful marker in distinguishing ovarian carcinomas from mammary carcinomas. *Am J Surg Pathol* 32:1566-1571.

- 146 Tornos C, Soslow R, Chen S, Akram M, Hummer AJ, Abu-Rustum N, Norton L and Tan LK (2005). Expression of WT1, CA125, and GCDP-15 as useful markers in the differential diagnosis of primary ovarian carcinomas versus metastatic breast cancer to the ovary. *Am J Surg Pathol* 29:1482-1489.
- 147 Liu H, Shi J, Wilkerson ML and Lin F (2012). Immunohistochemical evaluation of GATA3 expression in tumors and normal tissues: a useful immunomarker for breast and urothelial carcinomas. *Am J Clin Pathol* 138:57-64.
- 148 Hashi A, Yuminamochi T, Murata S, Iwamoto H, Honda T and Hoshi K (2003). Wilms' tumor gene immunoreactivity in primary serous carcinomas of the fallopian tube, ovary, endometrium, and peritoneum. *Int J Gynecol Pathol* 22:374-377.
- 149 Shimizu M, Toki T, Takagi Y, Konishi I and Fujii S (2000). Immunohistochemical detection of the Wilms' tumor gene (WT1) in epithelial ovarian tumors. *Int J Gynecol Pathol* 19:158-163.
- 150 Al-Hussaini M, Stockman A, Foster H and McCluggage WG (2004). WT-1 assists in distinguishing ovarian from uterine serous carcinoma and in distinguishing between serous and endometrioid ovarian carcinoma. *Histopathology* 44:109-115.
- 151 Goldstein NS and Uzieblo A (2002). WT1 immunoreactivity in uterine papillary serous carcinomas is different from ovarian serous carcinomas. *Am J Clin Pathol* 117:541-545.
- 152 Acs G, Pasha T and Zhang PJ (2004). WT1 is expressed in serous, but not in endometrioid, clear cell or mucinous carcinoma of the peritoneum, fallopian tube, ovaries and endometrium. *Int J Gynecol Pathol* 23:110-118.
- 153 Hirschowitz L, Ganesan R and McCluggage WG (2009). WT1, p53 and hormone receptor expression in uterine serous carcinoma. *Histopathology* 55:478-482.
- 154 Assem H, Rambau PF, Lee S, Ogilvie T, Sienko A, Kelemen LE and Köbel M (2018). High-grade endometrioid carcinoma of the ovary: a clinicopathologic study of 30 cases. *Am J Surg Pathol* 42(4):534-544.
- 155 Altman AD, Nelson GS, Ghatage P, McIntyre JB, Capper D, Chu P, Nation JG, Karnezis AN, Han G, Kalloger SE and Köbel M (2013). The diagnostic utility of TP53 and CDKN2A to distinguish ovarian high-grade serous carcinoma from low-grade serous ovarian tumors. *Mod Pathol* 26(9):1255-1263.
- 156 Köbel M, Kalloger SE, Carrick J, Huntsman D, Asad H, Oliva E, Ewanowich CA, Soslow RA and Gilks CB (2009). A limited panel of immunomarkers can reliably distinguish between clear cell and high-grade serous carcinoma of the ovary. *Am J Surg Pathol* 33(1):14-21.
- 157 Lim D, Ip PP, Cheung AN, Kiyokawa T and Oliva E (2015). Immunohistochemical comparison of ovarian and uterine endometrioid carcinoma, endometrioid carcinoma with clear cell change, and clear cell carcinoma. *Am J Surg Pathol* 39(8):1061-1069.
- 158 Vang R, Shih IM and Kurman RJ (2013). Fallopian tube precursors of ovarian low- and high-grade serous neoplasms. *Histopathology* 62:44-58.
- 159 Köbel M, Piskorz AM, Lee S, Lui S, LePage C, Marass F, Rosenfeld N, Mes Masson AM and Brenton JD (2016). Optimized p53 immunohistochemistry is an accurate predictor of TP53 mutation in ovarian carcinoma. *J Pathol Clin Res* 2(4):247-258.

- 160 Köbel M, Ronnett BM, Singh N, Soslow RA, Gilks CB and McCluggage WG (2019). Interpretation of p53 immunohistochemistry in endometrial carcinomas: toward increased reproducibility. *Int J Gynecol Pathol* 38 Suppl 1(Iss 1 Suppl 1):S123-s131.
- 161 Parra-Herran C, Lerner-Ellis J, Xu B, Khalouei S, Bassiouny D, Cesari M, Ismiil N and Nofech-Mozes S (2017). Molecular-based classification algorithm for endometrial carcinoma categorizes ovarian endometrioid carcinoma into prognostically significant groups. *Mod Pathol* 30(12):1748-1759.
- 162 Hollis RL, Stanley B, Iida Y, Thomson J, Churchman M, Rye T, Mackean M, Nussey F, Gourley C and Herrington CS (2019). Hormone receptor expression patterns define clinically meaningful subgroups of endometrioid ovarian carcinoma. *Gynecol Oncol* 155(2):318-323.
- 163 Hollis RL, Thomson JP, Stanley B, Churchman M, Meynert AM, Rye T, Bartos C, Iida Y, Croy I, Mackean M, Nussey F, Okamoto A, Semple CA, Gourley C and Herrington CS (2020). Molecular stratification of endometrioid ovarian carcinoma predicts clinical outcome. *Nat Commun* 11(1):4995.
- 164 Rambau PF, Vierkant RA, Intermaggio MP, Kelemen LE, Goodman MT, Herpel E, Pharoah PD, Kommos S, Jimenez-Linan M, Karlan BY, Gentry-Maharaj A, Menon U, Polo SH, Candido Dos Reis FJ, Doherty JA, Gayther SA, Sharma R, Larson MC, Harnett PR, Hatfield E, de Andrade JM, Nelson GS, Steed H, Schildkraut JM, Carney ME, Høgdall E, Whittemore AS, Widschwendter M, Kennedy CJ, Wang F, Wang Q, Wang C, Armasu SM, Daley F, Coulson P, Jones ME, Anglesio MS, Chow C, de Fazio A, García-Closas M, Brucker SY, Cybulski C, Harris HR, Hartkopf AD, Huzarski T, Jensen A, Lubiński J, Oszurek O, Benitez J, Mina F, Staebler A, Taran FA, Pasternak J, Talhouk A, Rossing MA, Hendley J, Edwards RP, Fereday S, Modugno F, Ness RB, Sieh W, El-Bahrawy MA, Winham SJ, Lester J, Kjaer SK, Gronwald J, Sinn P, Fasching PA, Chang-Claude J, Moysich KB, Bowtell DD, Hernandez BY, Luk H, Behrens S, Shah M, Jung A, Ghatage P, Alsop J, Alsop K, García-Donas J, Thompson PJ, Swerdlow AJ, Karpinskyj C, Cazorla-Jiménez A, García MJ, Deen S, Wilkens LR, Palacios J, Berchuck A, Koziak JM, Brenton JD, Cook LS, Goode EL, Huntsman DG, Ramus SJ and Köbel M (2018). Association of p16 expression with prognosis varies across ovarian carcinoma histotypes: an Ovarian Tumor Tissue Analysis consortium study. *J Pathol Clin Res* 4(4):250-261.
- 165 Sieh W, Köbel M, Longacre TA, Bowtell DD, deFazio A, Goodman MT, Høgdall E, Deen S, Wentzensen N, Moysich KB, Brenton JD, Clarke BA, Menon U, Gilks CB, Kim A, Madore J, Fereday S, George J, Galletta L, Lurie G, Wilkens LR, Carney ME, Thompson PJ, Matsuno RK, Kjær SK, Jensen A, Høgdall C, Kalli KR, Fridley BL, Keeney GL, Vierkant RA, Cunningham JM, Brinton LA, Yang HP, Sherman ME, García-Closas M, Lissowska J, Odunsi K, Morrison C, Lele S, Bshara W, Sucheston L, Jimenez-Linan M, Driver K, Alsop J, Mack M, McGuire V, Rothstein JH, Rosen BP, Bernardini MQ, Mackay H, Oza A, Wozniak EL, Benjamin E, Gentry-Maharaj A, Gayther SA, Tinker AV, Prentice LM, Chow C, Anglesio MS, Johnatty SE, Chenevix-Trench G, Whittemore AS, Pharoah PD, Goode EL, Huntsman DG and Ramus SJ (2013). Hormone-receptor expression and ovarian cancer survival: an Ovarian Tumor Tissue Analysis consortium study. *Lancet Oncol* 14(9):853-862.
- 166 Wang L, Rambau PF, Kelemen LE, Anglesio MS, Leung S, Talhouk A and Köbel M (2019). Nuclear  $\beta$ -catenin and CDX2 expression in ovarian endometrioid carcinoma identify patients with favourable outcome. *Histopathology* 74(3):452-462.
- 167 Kang EY, Cheasley D, LePage C, Wakefield MJ, da Cunha Torres M, Rowley S, Salazar C, Xing Z, Allan P, Bowtell DDL, Mes-Masson AM, Provencher DM, Rahimi K, Kelemen LE, Fasching PA, Doherty JA, Goodman MT, Goode EL, Deen S, Pharoah PDP, Brenton JD, Sieh W, Mateoiu C, Sundfeldt K, Cook LS, Le ND, Anglesio MS, Gilks CB, Huntsman DG, Kennedy CJ, Traficante N, DeFazio A, Kaufmann S, Churchman M, Gourley C, Stephens AN, Meagher NS, Ramus SJ, Antill YC, Campbell I, Scott CL, Köbel M and Gorringer KL (2021). Refined cut-off for TP53 immunohistochemistry improves prediction of TP53 mutation status in ovarian mucinous tumors: implications for outcome analyses. *Mod Pathol* 34(1):194-206.

- 168 Le Page C, Rahimi K, Köbel M, Tonin PN, Meunier L, Portelance L, Bernard M, Nelson BH, Bernardini MQ, Bartlett JMS, Bachvarov D, Gotlieb WH, Gilks B, McAlpine JN, Nachtigal MW, Piché A, Watson PH, Vanderhyden B, Huntsman DG, Provencher DM and Mes-Masson AM (2018). Characteristics and outcome of the COEUR Canadian validation cohort for ovarian cancer biomarkers. *BMC Cancer* 18(1):347.
- 169 Mirza MR, Monk BJ, Herrstedt J, Oza AM, Mahner S, Redondo A, Fabbro M, Ledermann JA, Lorusso D, Vergote I, Ben-Baruch NE, Marth C, Mądry R, Christensen RD, Berek JS, Dørum A, Tinker AV, du Bois A, González-Martín A, Follana P, Benigno B, Rosenberg P, Gilbert L, Rimel BJ, Buscema J, Balsler JP, Agarwal S and Matulonis UA (2016). Niraparib maintenance therapy in platinum-sensitive, recurrent ovarian cancer. *N Engl J Med* 375(22):2154-2164.
- 170 Gulhan DC, Lee JJ, Melloni GEM, Cortés-Ciriano I and Park PJ (2019). Detecting the mutational signature of homologous recombination deficiency in clinical samples. *Nat Genet* 51(5):912-919.
- 171 Rambau PF, Duggan MA, Ghatage P, Warfa K, Steed H, Perrier R, Kelemen LE and Köbel M (2016). Significant frequency of MSH2/MSH6 abnormality in ovarian endometrioid carcinoma supports histotype-specific Lynch syndrome screening in ovarian carcinomas. *Histopathology* 69(2):288-297.
- 172 Bennett JA, Morales-Oyarvide V, Campbell S, Longacre TA and Oliva E (2016). Mismatch repair protein expression in clear cell carcinoma of the ovary: incidence and morphologic associations in 109 cases. *Am J Surg Pathol* 40(5):656-663.
- 173 Chui MH, Ryan P, Radigan J, Ferguson SE, Pollett A, Aronson M, Semotiuk K, Holter S, Sy K, Kwon JS, Soma A, Singh N, Gallinger S, Shaw P, Arseneau J, Foulkes WD, Gilks CB and Clarke BA (2014). The histomorphology of Lynch syndrome-associated ovarian carcinomas: toward a subtype-specific screening strategy. *Am J Surg Pathol* 38(9):1173-1181.
- 174 Jensen KC, Mariappan MR, Putcha GV, Husain A, Chun N, Ford JM, Schrijver I and Longacre TA (2008). Microsatellite instability and mismatch repair protein defects in ovarian epithelial neoplasms in patients 50 years of age and younger. *Am J Surg Pathol* 32(7):1029-1037.
- 175 Vierkoetter KR, Ayabe AR, VanDrunen M, Ahn HJ, Shimizu DM and Terada KY (2014). Lynch Syndrome in patients with clear cell and endometrioid cancers of the ovary. *Gynecol Oncol* 135(1):81-84.
- 176 Tholander B, Koliadi A, Botling J, Dahlstrand H, Von Heideman A, Ahlström H, Öberg K and Ullenhag GJ (2020). Complete response with combined BRAF and MEK inhibition in BRAF mutated advanced low-grade serous ovarian carcinoma. *Ups J Med Sci* 125(4):325-329.
- 177 Cheasley D, Wakefield MJ, Ryland GL, Allan PE, Alsop K, Amarasinghe KC, Ananda S, Anglesio MS, Au-Yeung G, Böhm M, Bowtell DDL, Brand A, Chenevix-Trench G, Christie M, Chiew YE, Churchman M, DeFazio A, Demeo R, Dudley R, Fairweather N, Fedele CG, Fereday S, Fox SB, Gilks CB, Gourley C, Hacker NF, Hadley AM, Hendley J, Ho GY, Hughes S, Hunstman DG, Hunter SM, Jobling TW, Kalli KR, Kaufmann SH, Kennedy CJ, Köbel M, Le Page C, Li J, Lupat R, McNally OM, McAlpine JN, Mes-Masson AM, Mileskin L, Provencher DM, Pyman J, Rahimi K, Rowley SM, Salazar C, Samimi G, Saunders H, Semple T, Sharma R, Sharpe AJ, Stephens AN, Thio N, Torres MC, Traficante N, Xing Z, Zethoven M, Antill YC, Scott CL, Campbell IG and Goringe KL (2019). The molecular origin and taxonomy of mucinous ovarian carcinoma. *Nat Commun* 10(1):3935.
- 178 Tan DS, Iravani M, McCluggage WG, Lambros MB, Milanezi F, Mackay A, Gourley C, Geyer FC, Vatcheva R, Millar J, Thomas K, Natrajan R, Savage K, Fenwick K, Williams A, Jameson C, El-Bahrawy M, Gore ME, Gabra H, Kaye SB, Ashworth A and Reis-Filho JS (2011). Genomic analysis reveals the molecular heterogeneity of ovarian clear cell carcinomas. *Clin Cancer Res* 17(6):1521-1534.

- 179 Matias-Guiu X and Prat J (2013). Molecular pathology of endometrial carcinoma. *Histopathology* 62:111-123.
- 180 The Cancer Genome Atlas Research Network (2011). Integrated genomic analyses of ovarian carcinoma. *Nature* 474:609-615.
- 181 Coleman RL, Fleming GF, Brady MF, Swisher EM, Steffensen KD, Friedlander M, Okamoto A, Moore KN, Efrat Ben-Baruch N, Werner TL, Cloven NG, Oaknin A, DiSilvestro PA, Morgan MA, Nam JH, Leath CA, 3rd, Nicum S, Hagemann AR, Littell RD, Cella D, Baron-Hay S, Garcia-Donas J, Mizuno M, Bell-McGuinn K, Sullivan DM, Bach BA, Bhattacharya S, Ratajczak CK, Ansell PJ, Dinh MH, Aghajanian C and Bookman MA (2019). Veliparib with first-line chemotherapy and as maintenance therapy in ovarian cancer. *N Engl J Med* 381(25):2403-2415.
- 182 Ray-Coquard I, Pautier P, Pignata S, Pérol D, González-Martín A, Berger R, Fujiwara K, Vergote I, Colombo N, Mäenpää J, Selle F, Sehouli J, Lorusso D, Guerra Alía EM, Reinthaller A, Nagao S, Lefeuvre-Plesse C, Canzler U, Scambia G, Lortholary A, Marmé F, Combe P, de Gregorio N, Rodrigues M, Buderath P, Dubot C, Burges A, You B, Pujade-Lauraine E and Harter P (2019). Olaparib plus bevacizumab as first-line maintenance in ovarian cancer. *N Engl J Med* 381(25):2416-2428.
- 183 Cheasley D, Nigam A, Zethoven M, Hunter S, Etemadmoghadam D, Semple T, Allan P, Carey MS, Fernandez ML, Dawson A, Köbel M, Huntsman DG, Le Page C, Mes-Masson AM, Provencher D, Hacker N, Gao Y, Bowtell D, deFazio A, Goringe KL and Campbell IG (2021). Genomic analysis of low-grade serous ovarian carcinoma to identify key drivers and therapeutic vulnerabilities. *J Pathol* 253(1):41-54.
- 184 Maeda D and Shih I-M (2013). Pathogenesis and the role of ARID1A mutation in endometriosis-related ovarian neoplasms. *Adv Anat Pathol* 20:45-52.
- 185 Cuatrecasas M, Villanueva A, Matias-Guiu X and Prat J (1997). K-ras mutations in mucinous ovarian tumors. *Cancer* 79:1581-1586.
- 186 Hennessy BT, Coleman RL and Markman M (2009). Ovarian cancer. *Lancet* 374:1371-1382.
- 187 Siegel R, Ma J, Zou Z and Jemal A (2014). Cancer statistics, 2014. *CA Cancer J Clin* 64:9-29.
- 188 Amin MB, Edge SB, Greene FL, Byrd DR, Brookland RK, Washington MK, Gershenwald JE, Compton CC, Hess KR, Sullivan DC, Jessup JM, Brierley JD, Gaspar LE, Schilsky RL, Balch CM, Winchester DP, Asare EA, Madera M, Gress DM and Meyer LR (eds) (2017). *AJCC Cancer Staging Manual. 8th ed.*, Springer, New York.
- 189 Berek JS, Kehoe ST, Kumar L and Friedlander M (2018). Cancer of the ovary, fallopian tube, and peritoneum. *Int J Gynaecol Obstet* 143 Suppl 2:59-78.
- 190 Wittekind C, Brierley JD, Lee A and van Eycken E (eds) (2019). *TNM Supplement: A Commentary on Uniform Use, 5th Edition*, Wiley, USA.