



Family/Last name

Date of birth

Given name(s)

Patient identifiers

Date of request

Accession/Laboratory number

Elements in **black text** are **CORE**. Elements in **grey text** are **NON-CORE**.

indicates multi-select values indicates single select values

SCOPE OF THIS DATASET

CLINICAL INFORMATION (Note 1)

- Information not provided
- Information provided (select all that apply)
 - Previous therapy
 - Surgery
 - Targeted therapy, specify if available
 - Immunotherapy, specify if available
 - Other clinical information, specify
 - Chemotherapy
 - Radiotherapy

OPERATIVE PROCEDURE (select all that apply) (Note 2)

- Not specified
- Biopsy (excisional, incisional, core needle),^a specify
- Resection
 - Glossectomy, specify
 - Buccal mucosa, specify
 - Lip, specify
 - Mandibulectomy, specify
 - Maxillectomy, specify
 - Palatectomy, specify
 - Neck (lymph node) dissection,^b specify
 - Other, specify

^a Only for small T1 tumours.

^b If a neck (lymph node) dissection is submitted, then a separate dataset is used to record the information.

SPECIMEN(S) SUBMITTED (select all that apply) (Note 3)

- Not specified
- Lip
- Tongue
- Gingiva
- Floor of mouth
- Hard palate
- Buccal mucosa
- Buccal vestibule
- Retromolar trigone
- Alveolar process
- Mandible
- Maxilla
- Neck (lymph node) dissection,^b specify
- Other, specify

TUMOUR SITE (select all that apply) (Note 3)

- Not specified
- Lip**
 - Mucosal (wet), upper lip
 - Mucosal (wet), lower lip
- Oral cavity**
 - Lateral border of tongue
 - Ventral surface of tongue, NOS
 - Dorsal surface of tongue and anterior two-thirds of tongue, NOS
 - Floor of mouth, NOS
 - Hard palate
 - Buccal mucosa (inner cheek)
 - Retromolar trigone
 - Vestibule of mouth
 - Maxillary
 - Mandibular
 - Alveolar process and gingiva
 - Maxillary
 - Mandibular
 - Mandible
 - Maxilla
 - Other, specify

TUMOUR LATERALITY (select all that apply)

- Not specified
- Left
- Right
- Midline

TUMOUR FOCALITY (Note 4)

- Unifocal
- Bilateral
- Multifocal

Specify number of tumours

TUMOUR DIMENSIONS (select all that apply) (Note 5)

Maximum tumour dimension (largest tumour)
(pathology and/or imaging determination)

mm

Additional dimensions (largest tumour)

mm x mm

- Cannot be assessed, specify

BLOCK IDENTIFICATION KEY (Note 6)

(List overleaf or separately with an indication of the nature and origin of all tissue blocks)

HISTOLOGICAL TUMOUR TYPE (select all that apply) (Note 7)

(Value list based on the World Health Organization Classification of Head and Neck Tumours (2024))

- Squamous cell carcinomas and subtypes
 - Squamous cell carcinoma, conventional type
 - Spindle cell (sarcomatoid) squamous cell carcinoma
 - Basaloid squamous cell carcinoma
 - Acantholytic squamous cell carcinoma
 - Adenosquamous carcinoma
 - Papillary squamous cell carcinoma
 - Lymphoepithelial carcinoma
 - Verrucous carcinoma
 - Carcinoma cuniculatum

Salivary gland-type carcinoma,^c specify type

Neuroendocrine neoplasm, specify type

Other, specify

^c For histological type of salivary gland-type carcinomas, refer to the Carcinomas of the major salivary glands dataset.

HISTOLOGICAL TUMOUR GRADE^d (Note 8)

(Applicable to conventional squamous cell carcinoma, minor salivary gland tumours and neuroendocrine tumours only)

- Grade 1, well differentiated, low grade
- Grade 2, moderately differentiated, intermediate grade
- Grade 3, poorly differentiated, high grade
- Undifferentiated
- High grade transformation

Grading system used, specify

- Cannot be assessed, specify

^d Grading of neuroendocrine tumours is non-core. Use only Grade 1, 2 and 3 for neuroendocrine tumours; neuroendocrine carcinomas are considered high grade by definition and are therefore not graded.

DEPTH OF INVASION (Note 9)

(Resection specimens and excisional biopsies only; not applicable to incisional biopsies; applicable for squamous cell carcinoma only)

- ≤5 mm
- >5 mm and ≤10 mm
- >10 mm

- Cannot be assessed, specify

PATTERN OF INVASIVE FRONT (Note 10)

(Resection specimens and excisional biopsies only; not applicable to incisional biopsies; applicable for squamous cell carcinoma only)

- Cohesive
- Non-cohesive
- Widely dispersed

EXTENT OF INVASION (Note 11)

- Not identified
- Present (select all that apply)

Clinical observation and/or imaging Histologic

- ↓
- Bone invasion
 - Cortical bone erosion
 - Medullary bone involvement

- Involves skin of face/neck
- Involves floor of mouth
- Involves maxillary sinus
- Other, specify

- Cannot be assessed, specify

LYMPHOVASCULAR INVASION (Note 12)

- Not identified
- Present
- Indeterminate, specify reason

PERINEURAL INVASION (Note 13)

Not identified

Present

Nerve size, if known mm

Indeterminate, specify reason

MARGIN STATUS (Note 14)

Invasive carcinoma

Not involved

Distance of tumour from closest margin mm

Distance not assessable

Specify closest margin(s), if possible

Involved

Specify margin(s), if possible

Cannot be assessed, specify

Carcinoma in situ/high grade dysplasia^e

Not applicable

Not involved

Distance of carcinoma in situ/high grade dysplasia from closest margin mm

Distance not assessable

Specify closest margin(s), if possible

Involved

Specify margin(s), if possible

Cannot be assessed, specify

^e High grade dysplasia is synonymous with moderate/severe dysplasia.

COEXISTENT PATHOLOGY (select all that apply) (Note 15)

None identified

Proliferative verrucous leukoplakia

Fungal infection

Dysplasia, specify grade

HPV-associated dysplasia

Submucous fibrosis

Other, specify

ANCILLARY STUDIES (Note 16)

Neuroendocrine neoplasms (select all that apply)

Not applicable

Neuroendocrine markers, specify

Cytokeratin(s), specify

Ki-67 proliferation index %

Rb

Retained

Deficient

p53

Abnormal, specify

Other, record test(s), methodology and results

Other tumours

Not performed

Performed, record test(s), methodology and results

Representative blocks for ancillary studies, specify those blocks best representing tumour and/or normal tissue for further study

PATHOLOGICAL STAGING (UICC TNM 8th edition)^f (Note 17)

TNM Descriptors (only if applicable) (select all that apply)

m - multiple primary tumours

r - recurrent

y - during or following multimodality therapy

Primary tumour (pT)^g

TX^h Primary tumour cannot be assessed

Tis Carcinoma in situ

T1 Tumour 2 cm or less in greatest dimension and 5 mm or less depth of invasionⁱ

T2 Tumour 2 cm or less in greatest dimension and more than 5 mm depth of invasion or tumour more than 2 cm but not more than 4 cm in greatest dimension and depth of invasion no more than 10 mm

T3 Tumour more than 2 cm but not more than 4 cm in greatest dimension and depth of invasion more than 10 mm or tumour more than 4 cm in greatest dimension and not more than 10 mm depth of invasion

T4a (Lip) Tumour more than 4 cm in greatest dimension and more than 10 mm depth of invasion or tumour invades through cortical bone, inferior alveolar nerve, floor of mouth, or skin (of the chin or the nose)

T4a (Oral cavity) Tumour more than 4 cm in greatest dimension and more than 10 mm depth of invasion or tumour invades through the cortical bone of the mandible or maxilla or involves the maxillary sinus, or invades the skin of the face

T4b (Lip and oral cavity) Tumour invades masticator space, pterygoid plates, or skull base, or encases internal carotid artery

^f Reproduced with permission. Source: UICC TNM Classification of Malignant Tumours, 8th Edition, eds by James D. Brierley, Mary K. Gospodarowicz, Christian Wittekind. 2016, Publisher Wiley (incorporating any errata published up until 12th July 2024).

^g Note that the results of neck (lymph node) dissection are derived from a separate dataset.

^h TX should be used only if absolutely necessary.

ⁱ Superficial erosion alone of bone/tooth socket by gingival primary is not sufficient to classify a tumour as T4a.

Definitions

CORE elements

CORE elements are those which are essential for the clinical management, staging or prognosis of the cancer. These elements will either have evidentiary support at Level III-2 or above (based on prognostic factors in the National Health and Medical Research Council (NHMRC) levels of evidence¹). In rare circumstances, where level III-2 evidence is not available an element may be made a CORE element where there is unanimous agreement in the Dataset Authoring Committee (DAC). An appropriate staging system e.g., Pathological TNM staging would normally be included as a CORE element.

Molecular and immunohistochemical testing is a growing feature of cancer reporting. However, in many parts of the world this type of testing is limited by the available resources. In order to encourage the global adoption of ancillary tests for patient benefit, International Collaboration on Cancer Reporting (ICCR) includes the most relevant ancillary testing in ICCR Datasets as CORE elements, especially when they are necessary for the diagnosis. Where the technical capability does not yet exist, laboratories may consider temporarily using these data elements as NON-CORE items.

The summation of all Core elements is considered to be the minimum reporting standard for a specific cancer.

NON-CORE elements

NON-CORE elements are those which are unanimously agreed should be included in the dataset but are not supported by level III-2 evidence. These elements may be clinically important and recommended as good practice but are not yet validated or regularly used in patient management.

Key information other than that which is essential for clinical management, staging or prognosis of the cancer such as macroscopic observations and interpretation, which are fundamental to the histological diagnosis and conclusion e.g., macroscopic tumour details, may be included as either CORE or NON-CORE elements by consensus of the DAC.

Scope

The dataset has been developed for the reporting of resection and excisional biopsy specimens of malignancies of the oral cavity, including mucosal lip and tongue (mucosal carcinomas, minor salivary gland malignancies, and neuroendocrine tumours). For resections of recurrent disease, the reporting guide may be used pragmatically although some data elements may be not applicable nor assessable. Incisional biopsies and other biopsy specimens are not included in this dataset. Mucosal melanoma, lymphomas and sarcomas are dealt with in separate ICCR datasets.² In addition, neck dissections and nodal excisions are dealt with in a separate ICCR dataset, and this dataset should be used in conjunction, where applicable.³

For additional independent (multicentric) tumours, complete a separate dataset for each.

The second edition of this dataset includes changes to align the dataset with the World Health Organization (WHO) Classification of Head and Neck Tumours, 5th edition, 2024.⁴

A list of changes in this dataset edition can be accessed [here](#).

The authors of this dataset can be accessed [here](#).



Back

Note 1 – Clinical information (Core and Non-core)

There is no agreed upon system for grading tumour regression in oral squamous cell carcinomas (OSCC) that have been treated with previous therapy.⁵

However, a history of previous radiotherapy and/or chemotherapy should be included as histologic changes related to the therapy such as necrosis may affect interpretation of the tumour.⁶

↑ Back

Note 2 – Operative procedure (Core)

It is important to correlate the type of procedure (excisional biopsy or resection) with the material received for patient safety. Site-specific designations are required for accurate staging and for cancer registration. Modification of the resection, for example, partial, total should be described (e.g., hemi-glossectomy, partial glossectomy, hemi-mandibulectomy, segmental (partial) mandibulectomy, partial maxillectomy, selective neck dissection).^{7,8}

The exact surgical procedure may require discussion between the pathologist and surgeon.

↑ Back

Note 3 – Specimen(s) submitted (Core) and Tumour site (Core)

The anatomy and surgical interventions of the oral cavity are complex, and it is important to ensure accurate and precise communication between the pathologists and the treating and diagnostic team with respect to exact anatomic site of involvement, tumour laterality and specific operative procedures.⁹⁻¹¹

The protocol applies to all carcinomas arising at these sites (see Figure 1). For large cancers that involve more than one site, the primary site of involvement should be recorded.

Mucosal Lip. Begins at the junction of the wet and dry mucosa (vermilion border) that comes in contact with the opposing lip. The dry vermilion lip and vermilion border are staged using the cutaneous dataset.¹²

Buccal Mucosa (Inner Cheek). Mucous membrane lining of the inner surface of the cheeks and lips of contact of the opposing lips to the line of attachment of mucosa of the upper and lower alveolar ridge and pterygomandibular raphe.

Lower Alveolar Ridge. Mucosa overlying the alveolar process of the mandible, which extends from the line of attachment of mucosa in the buccal vestibule to the line of free mucosa of the floor of the mouth. Posteriorly it extends to the ascending ramus of the mandible.

Upper Alveolar Ridge. Mucosa overlying the alveolar process of the maxilla, which extends from the line of attachment of mucosa in the upper gingival buccal vestibule to the junction of the hard palate. The posterior margin is the upper end of the pterygopalatine arch.

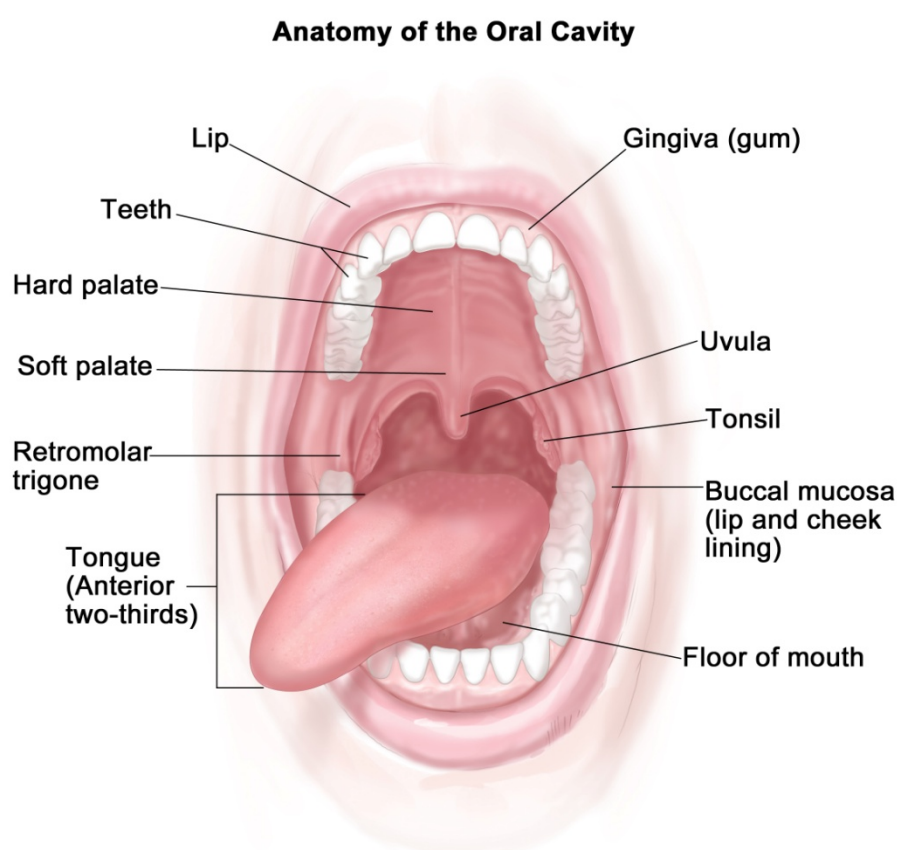
Floor of the Mouth. Semilunar space over the mylohyoid and hyoglossus muscles, extending from the inner surface of the lower alveolar ridge to the undersurface of the tongue. The posterior boundary is the base of the anterior pillar of the tonsil. It is divided into two sides of the submaxillary and sublingual salivary glands.

Hard Palate. This is the semilunar area between the upper alveolar ridge and the mucous membrane covering the palatine process of the maxillary palatine bones. It extends from the inner surface of the superior alveolar ridge to the posterior edge of the palatine bone.

Anterior Two-Thirds of the Tongue (Oral Tongue). The freely mobile portion of the tongue that extends anteriorly from the line of circumvallate papillae to the undersurface (ventral) of the tongue at the junction of the floor of the mouth. It includes the tip of tongue, lateral borders, dorsal surface and ventral tongue. The ventral tongue is listed as a separate tumour site in the ICCR reporting guide.

Retromolar trigone. A triangular shaped region extending distal from the mandibular third molar as the base and attaches to the hamulus of the medial pterygoid process of the sphenoid bone as the apex.

'Not specified' should be used rarely and only after good effort has been employed to obtain the requisite information.



© 2012 Terese Winslow LLC
U.S. Govt. has certain rights

Figure 1: Anatomic sites and subsites for lip and oral cavity.

- **The vermilion/dry lip is considered cutaneous.**
- **The uvula and soft palate and tonsil are considered oropharynx.**

↑ Back

Note 4 – Tumour focality (Non-core)

True multifocal or synchronous oral cavity carcinomas are rare. Patients with OSCC have an increased incidence (2-3%) of developing a second primary lesion. However, these are usually metachronous lesions. The theory of field cancerization whereby contiguous genetically altered areas of mucosa lead to the development of neoplasms have been supported by studies evaluating clonality and other molecular markers. Proliferative verrucous leukoplakia has the propensity for developing multifocal tumours. It is rare to have multiple tumours disconnected but not uncommon to have more than one squamous cell carcinoma (SCC) connected via dysplasia. The location, proximity to dysplastic epithelium, depth and nodal status remain important. Tumour focality is used for staging as well as clinical trials and treatment considerations.¹³⁻¹⁵

 **Back**

Note 5 – Tumour dimensions (Core and Non-core)

Tumour dimension is an important component in pathologic staging.^{16,17} If available, measurements are made on fresh tissue. The macroscopic diameter (in millimetres) should be used unless the histological extent is greater than macroscopically apparent, in which case the microscopic dimension is used. At times only microscopic evaluation differentiates what clinically appears to be tumour from what is actual invasion (not dysplasia or inflammation). At least the greatest tumour dimension should be reported; preferably all three dimensions should be evaluated. Measurements are made pragmatically, acknowledging distortion of tissues by fixation and processing.¹⁸

 **Back**

Note 6 – Block identification key (Non-core)

The origin/designation of all tissue blocks should be recorded. This information should ideally be documented in the final pathology report and is particularly important should the need for internal or external review arise. The reviewer needs to be clear about the origin of each block in order to provide an informed specialist opinion. If this information is not included in the final pathology report, it should be available on the laboratory computer system and relayed to the reviewing pathologist. It may be useful to have a digital image of the specimen and record of the origin of the tumour blocks in some cases.

Recording the origin/designation of tissue blocks also facilitates retrieval of blocks for further immunohistochemical or molecular analysis, research studies or clinical trials.

 **Back**

Note 7 – Histological tumour type (Core)

All tumours of the oral cavity should be given a type based on the most recent edition of the WHO Classification of Head and Neck Tumours, 5th edition, 2024 (Table 1).⁴ The major histologic tumour types of SCC as recognised by the WHO classification are SCC, conventional type, basaloid, papillary, spindle, adenosquamous, acantholytic, lymphoepithelial, verrucous carcinoma and carcinoma cuniculatum. Hybrid lesions such as verrucous carcinoma and SCC exist and should be recognised as it may affect prognosis. Subtypes should be assigned for both prognosis and cancer registry.^{19,20}

Salivary gland carcinoma histologic type essentially defines its biologic behaviour and thus influences prognosis, patterns of recurrence and thus clinical management.²¹ Some carcinoma types (i.e., basal cell adenocarcinoma, conventional acinic cell carcinoma) are more indolent with locoregional recurrence but low nodal and distant metastatic rates.²² For guidance on histological typing of minor salivary gland carcinomas, please refer to the ICCR Carcinomas of the major salivary gland dataset.²³

The classification and grading of neuroendocrine carcinomas (NEC) is discussed in **Note 8 HISTOLOGICAL TUMOUR GRADE**.

Table 1: World Health Organization classification of subtypes of squamous cell carcinoma of the oral cavity and mobile tongue.⁴

Descriptor	ICD-O codes ^a
Epithelial tumours and lesions	
Squamous cell carcinoma, conventional type	8070/3
Spindle cell (sarcomatoid) squamous cell carcinoma	8074/3
Basaloid squamous cell carcinoma	8083/3
Acantholytic squamous cell carcinoma	8075/3
Adenosquamous carcinoma	8560/3
Papillary squamous cell carcinoma	8052/3
Lymphoepithelial carcinoma	8082/3
Verrucous carcinoma	8051/3
Carcinoma cuniculatum	8051/3
Epithelial neuroendocrine neoplasms	
Small cell neuroendocrine carcinoma	8041/3
Large cell neuroendocrine carcinoma	8013/3
Carcinoma mixed with small cell neuroendocrine carcinoma ^b	8045/3
Carcinoma mixed with large cell neuroendocrine carcinoma ^b	8013/3

^a These morphology codes are from the International Classification of Diseases for Oncology, third edition, second revision (ICD-O-3.2).²⁴ Behaviour is coded /0 for benign tumours; /1 for unspecified, borderline, or uncertain behaviour; /2 for carcinoma in situ and grade III intraepithelial neoplasia; /3 for malignant tumours, primary site; and /6 for malignant tumours, metastatic site. Behaviour code /6 is not generally used by cancer registries.

^b This terminology is synonymous with the ICD-O terminology of combined small/large cell neuroendocrine carcinomas.

© World Health Organization/International Agency for Research on Cancer. Reproduced with permission.

 [Back](#)

Note 8 – Histological tumour grade (Core and Non-core)

Based on the WHO classifications, three histologic grades of SCC, conventional type are used: well, moderately or poorly differentiated.⁴ The most aggressive or highest grade should be recorded if the tumour has a varied histology. Grading requires the assessment of keratinisation, mitotic activity, cellular and nuclear pleomorphism, pattern of invasion and host response.^{7,25-27} SCC subtypes are not graded. Still, several grading systems for each tumour type are available, with differing merits, and as such, recording which system has been applied is more clinically meaningful (use ‘specify’ to state the system used), with the ICCR deferring to the WHO classification current edition for grading guidance and preference.⁴

Grading of minor salivary gland tumours follows the criteria for major salivary gland tumours.^{22,23}

Neuroendocrine neoplasms, as newly defined,⁴ include paraganglioma/pheochromocytoma, neuroendocrine tumours, and NECs. Neuroendocrine tumours are separated into grades (1, 2, and 3) based on mitotic rate and Ki-67 proliferation indices, but these criteria are not yet fully developed for each of the anatomic sites in the head and neck. At present, the general cutoffs are: grade 1: <2 mitoses/2 millimetre (mm)² and <2% Ki-67 proliferation index; grade 2: ≥2-10 mitoses/2 mm² and 2-20% Ki-67 proliferation index; grade 3: ≥11 mitoses/2 mm² and >20% Ki-67 proliferation index.^{28,29} Further, NECs are separated into small cell and large cell categories, showing tumour necrosis, >10 mitoses/2 mm² and >20% Ki-67 proliferation index,^{28,30-32} with universal Rb1 loss and common p53 overexpression.³³ At present, the site, tumour category, and grade (non-core) should be reported, with additional advances in this field incorporated when validated further.

↑ Back

Note 9 – Depth of invasion (Core)

Depth of invasion (DOI) in OSCC, particularly of the tongue, has been identified as an important prognostic indicator, and is therefore a core element. The Union for International Cancer Control (UICC)/American Joint Committee on Cancer (AJCC) TNM staging systems incorporate DOI in determining the tumour stage (T).^{16,17,34} DOI increases T by 1 step for every 5 mm, whereby T1 is tumour ≤20 mm (≤2 centimetres (cm)) and DOI ≤5 mm, T2 is tumour ≤20 mm (≤2 cm) and DOI >5 mm and ≤10 mm, T3 tumour is >20 mm (>2 cm) and ≤40 mm (≤4 cm) and >10 mm DOI and T4a is tumour >40 mm (>4 cm) or any tumour >10 mm DOI. DOI measures the invasiveness of the carcinoma. To measure DOI, the basement membrane is identified, and an imaginary line is drawn across the tumour. A vertical or ‘plumb line’ extends to the deepest part of the tumour which represents the DOI. When the tumour is widely dispersed (see **Note 10 – PATTERN OF INVASIVE FRONT**), the measurement should be from the most distance tumour nest. It is important to note that DOI is not synonymous with tumour thickness. An exophytic tumour (Figure 2A) may be thicker than an ulcerative tumour (Figure 2B), but the DOI of the ulcerative lesion may be greater.^{35,36}

The maximum DOI should be recorded as core and the discussion should include how/why DOI is different than tumour thickness.^{18,37-39}

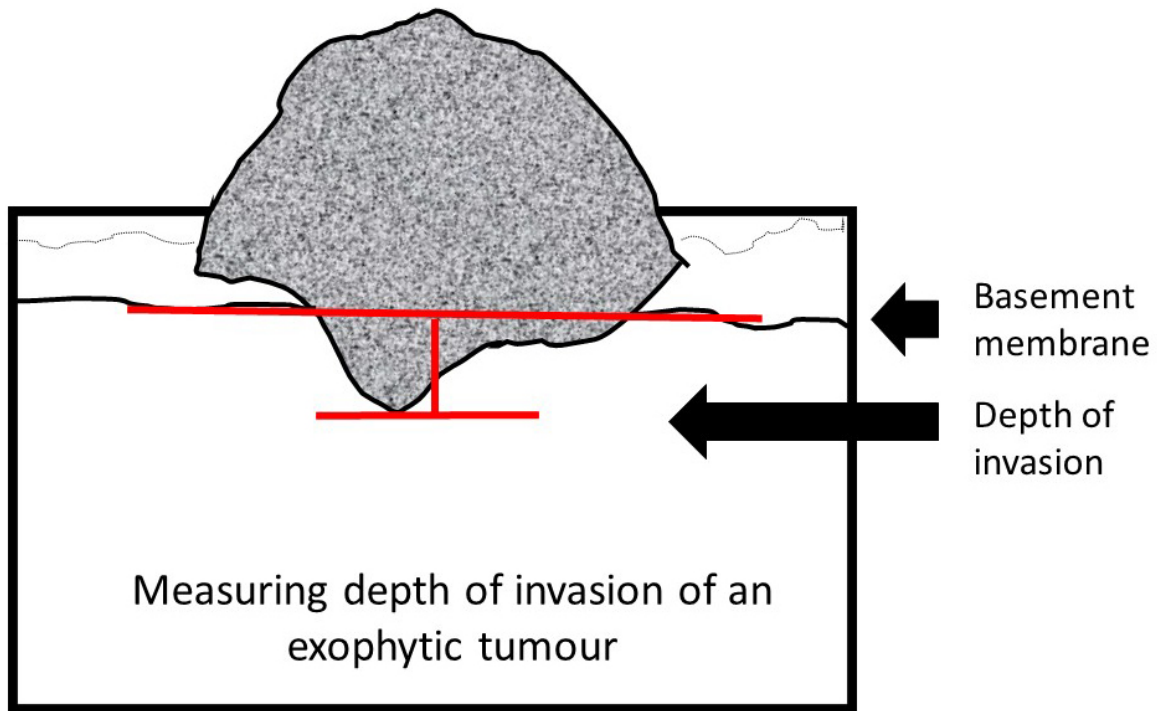


Figure 2A: Measuring depth of invasion.

© 2024 International Collaboration on Cancer Reporting Limited (ICCR).

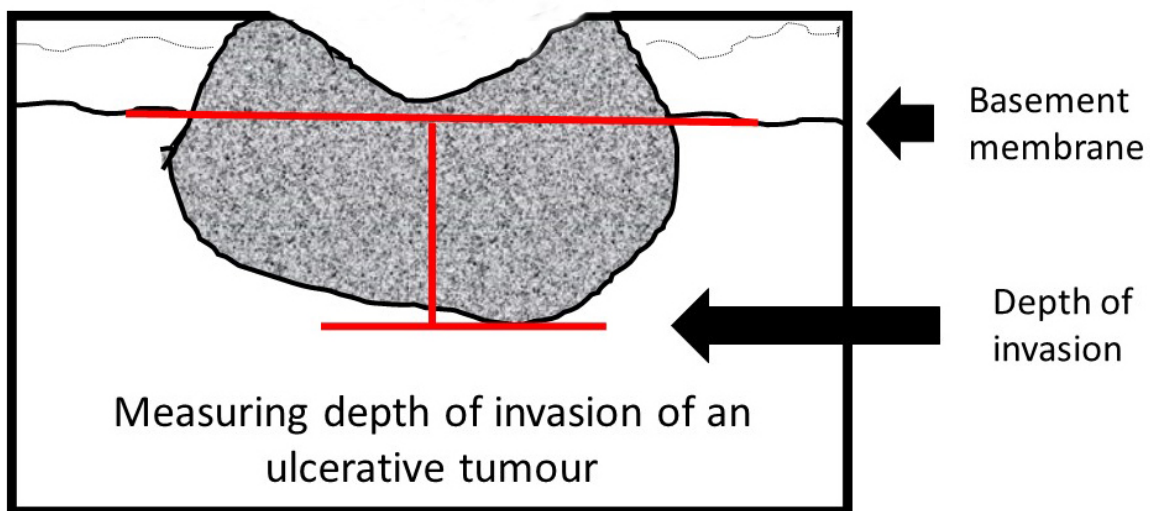


Figure 2B: Measuring depth of invasion.

© 2024 International Collaboration on Cancer Reporting Limited (ICCR).

↑ Back

Note 10 – Pattern of invasive front (Core)

The pattern of invasion in OSCC has proven prognostic value and should be reported as cohesive or non-cohesive (Figure 3).^{25,40-43} It is important to evaluate the most complex area of tumour-stroma interface ('worst' area), usually at the advancing edge, and ideally assessment should only be made on resection specimens or excisional biopsies. Acknowledgement is made that at times non-surgical treatment decisions are made on incisional biopsy specimens only and consequently the best assessment of pattern of invasion should be noted. Cohesive invasion is defined as broad sheets of cancer cells and/or tumour nests of >15 tumour cells. Non-cohesive invasion shows a spectrum of appearances that includes narrow strands, small groups of ≤15 tumour cells and single infiltrating tumour cells.^{35,36} For stage T1/T2 OSCC, particularly those arising in the tongue, there is evidence that tumour satellites localised ≥1 mm away from the main tumour or nearest satellite (worst pattern of invasion WPOI-5) is a valid adverse prognostic factor.^{25,40-42,44}

Additionally, tumour budding has emerged as a promising biomarker in various carcinomas, with early evidence suggesting that it is an independent adverse prognostic factor in carcinoma of the oral cavity.⁴⁵⁻⁵²

Tumour budding is defined as single tumour cells or clusters of up to four tumour cells at the invasive tumour front. There is no consensus yet how it should be assessed and graded in oral carcinoma. It has been recommended to count the number of buds in 2 mm² high power field (HPF) (x40) after scanning 10 HPFs in areas showing maximal budding.⁵³ Budding activity is graded as low if 1 to 14 buds per 2mm² and high if ≥15 buds per 2 mm² are counted.

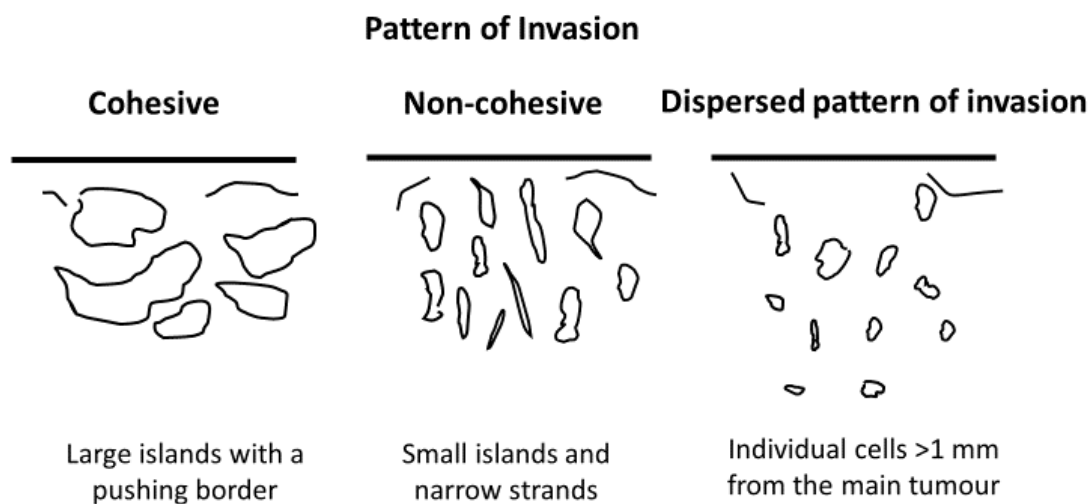


Figure 3: Pattern of Invasive front.

© 2024 International Collaboration on Cancer Reporting Limited (ICCR).

[↑ Back](#)

Note 11 – Extent of invasion (Core)

Infiltrative bone involvement by SCC correlates with a worse prognosis. Bone invasion may be a macroscopic feature, however sampling through the involved bone for histologic examination should be performed to obtain histologic evidence. The presence of bone invasion affects tumour staging and patients with bone invasion often have a worse prognosis. It is important to distinguish superficial cortical bone erosion from infiltrative invasion to the medullary bone as this is critical in accurate tumour staging. If bone is resected, then bone margins should be recorded.⁵⁴ Tumour involvement of the maxillary sinus, and skin of the face and neck increases the pathological stage and should be noted.

↑ Back

Note 12 – Lymphovascular invasion (Core)

There is a need to distinguish between intravascular tumour embolization and retraction artefact. Positive lymphovascular invasion is a risk factor for decreased overall survival and should be reported only when tumour emboli are identified within endothelial lined spaces. No distinction between venous channels and small lymphatics is required.^{27,55,56}

Cases that are still equivocal after taking additional steps may be reported as ‘indeterminate’ for lymphovascular invasion, but this designation should be sparingly used, and it is useful to provide the reason in a comment in the report.

↑ Back

Note 13 – Perineural invasion (Core and Non-core)

Perineural invasion is associated with a worse prognosis, regardless of nerve size and should be recorded. The presence or absence of perineural and/or endoneural/intraneural invasion may impact subsequent therapy and prognosis.^{7,25,27,57}

↑ Back

Note 14 – Margin status (Core)

All surgical margins should be measured in millimetres histologically for both mucosal and deep margins. In the comments section, acknowledgement should be made how the surgical margin was measured. For example, if the margin was submitted from the tumour bed margin at the time of the operative procedure rather than from the surgical specimen.⁵⁸⁻⁶⁰ The presence of severe dysplasia/carcinoma in situ at the margin is associated with an increased risk of local recurrence and this should be recorded. The definition of a ‘close’ margin is not standardised but in the oral cavity from a surgical point of view >5 mm is clear, and 1-5 mm is close, while <1 mm is involved. Acknowledgement is made of fixation and processing distortion on measurements which may cause tissue shrinkage including the surgical margin.⁶¹ Acknowledgement is also made of any laser or electrocautery associated tissue distortion such as cellular and nuclear polymorphism, nuclear hyperchromatism, epithelial cell separation, collagen denaturation, etc. on measurements including the surgical margin.⁶² Any bone resection margins should be identified and comment on the presence or absence of carcinoma at these margins should be provided.^{7,54} Dysplastic changes include abnormal cellular

organisation, increased mitotic activity, and nuclear enlargement with pleomorphism.^{7,25,63,64} Although terminology varies, using the 2024 WHO criteria for oral dysplasia,⁴ dysplasia limited to the lower one-third of the epithelium is generally referred to as mild dysplasia. However, this can undercall higher dysplasia grades when both the architectural and cytological features of dysplasia are confined to the lower third depending on the individual features, such as tumour budding, bulbous rete and pleomorphism.^{4,9,65-67} Moderate dysplasia is defined as cytological atypia extending to the middle third of the epithelium and severe dysplasia extends to the upper third of the epithelium. Carcinoma in situ is considered synonymous with severe dysplasia.

Reporting of surgical margins for carcinomas of the minor salivary glands should follow those used for SCC of oral cavity.

 **Back**

Note 15 – Coexistent pathology (Non-core)

The most common sites of dysplasia with the highest risk of malignant transformation are lateral and ventral tongue, floor of mouth, and lower lip. Dysplastic changes include abnormal cellular organisation, increased mitotic activity including abnormal forms, and nuclear enlargement with pleomorphism. Although terminology varies, dysplasia limited to the lower one-third of the epithelium is generally referred to as mild dysplasia (low grade dysplasia), dysplasia limited to the lower two-thirds as moderate dysplasia and dysplasia involving the full thickness as severe dysplasia/carcinoma in situ. However, when moderate dysplasia has marked cytologic atypia, then often the lesion will be upgraded to severe dysplasia.⁶⁵⁻⁶⁷ A subset of oral dysplasia is positive for high risk human papillomavirus (HPV). The epithelium exhibits full-thickness dysplastic changes with karyorrhexis, and apoptosis and the cells are strongly positive for p16 by immunohistochemistry but this should not be used as a surrogate marker for HPV in the oral cavity.¹⁹

Proliferative verrucous leukoplakia (PVL) is a distinct form of oral potentially malignant disorder (OPMD) of unknown etiology with a multifocal presentation and a progressive course with high recurrence rates and malignant transformation in as many as 70% of cases.^{15,19} This diagnosis requires adequate clinical information.

Subepithelial fibrosis is a characteristic of oral submucous fibrosis and increased fibrosis is associated with an increased risk of epithelial dysplasia.⁶⁸

Some inherited genetic mutations are associated with a higher risk of oral cancer development, including Fanconi anemia, Li-Fraumeni syndrome and dyskeratosis congenita.⁴

Patients with graft versus host disease resulting from allogenic hematopoietic stem cell transplantation have an increased risk of developing oral cancer.⁶⁹

Care must be taken to rule out reactive atypia which can be seen in epithelium adjacent to ulcers and with fungal infections.

 **Back**

Note 16 – Ancillary studies (Core and Non-core)

For neuroendocrine neoplasms core elements are neuroendocrine markers, epithelial markers, and Ki-67 proliferation index. The diagnosis of neuroendocrine neoplasms (specifically NETs and NECs) must be confirmed immunohistochemically, with positive reaction for neuroendocrine markers (synaptophysin, chromogranin, INSM1) and for epithelial markers (pancytokeratin, cytokeratin). A proliferation index as determined by KI-67 immunohistochemical analysis is recommended for grading all NETs, and helping to confirm NECs. Both p53 and Rb1 may be helpful in distinguishing between NET and NEC, especially G3 NET from NEC.^{29,33,70}

In most cases, further studies are not required for diagnosis of other tumours. Epithelial immunohistochemical markers may be required for poorly differentiated or spindle cell carcinoma including AE1/AE3, CK5/6, p63 and p40.⁷¹ Lymphoepithelial SCC in the oral cavity is rare and although not all cases are Epstein-Barr virus (EBV)-positive, EBV-encoded small RNAs (EBERs) studies are indicated.⁷² There is currently no role for routine HPV high risk type testing in OSCC.^{19,71} HPV-associated epithelial dysplasia requires in-situ hybridization/PCR confirmation.¹⁹

Programmed cell death-ligand 1 (PD-L1) expression has been used as predictive biomarker for checkpoint inhibitor therapy since the anti-programmed cell death-1 receptor (PD-1) antibodies, nivolumab and pembrolizumab, have been approved for the treatment of patients with recurrent and/or unresectable metastatic head and neck SSC,⁷³⁻⁷⁶ with various cutoffs of expression associated with better responses, although not in all patients.⁷⁷

↑ Back

Note 17 – Pathological staging (Core)

By UICC/AJCC convention,^{16,17} the designation 'T' refers to a primary tumour that has not been previously treated. The symbol 'p' refers to the pathologic classification of the stage, as opposed to the clinical classification, and is based on gross and microscopic examination. pT entails a resection of the primary tumour adequate to evaluate the highest pT category, pN entails removal of nodes adequate to validate lymph node metastasis, and pM implies microscopic examination of distant lesions. There is no pathologic M0 category as this designation requires clinical evaluation and imaging. Clinical classification (cTNM) is usually carried out by the evaluating clinician before treatment during initial evaluation of the patient or when pathologic classification is not possible.

Pathological staging is usually performed after surgical resection of the primary tumour and depends on documentation of the anatomic extent of disease, whether or not the primary tumour has been completely removed. If a biopsied tumour is not resected for any reason (e.g., when technically unfeasible) and if the highest T and N categories or the M1 category of the tumour can be confirmed microscopically, the criteria for pathologic classification and staging have been satisfied even though total removal of the primary cancer was not performed.

TNM Descriptors

For identification of special cases of TNM or pTNM classifications, the 'm' suffix and 'y' and 'r' prefixes are used. Although they do not affect the stage grouping, they indicate cases needing separate analysis.

The 'm' suffix indicates the presence of multiple primary tumours in a single site and is recorded in parentheses: pT(m)NM.

The 'y' prefix indicates those cases in which classification is performed during or following initial multimodality therapy (i.e., neoadjuvant chemotherapy, radiation therapy, or both chemotherapy and radiation therapy). The cTNM or pTNM category is identified by a 'y' prefix. The ycTNM or ypTNM categorises the extent of tumour actually present at the time of that examination. The 'y' categorisation is not an estimate of tumour prior to multimodality therapy (i.e., before initiation of neoadjuvant therapy).

The 'r' prefix indicates a recurrent tumour when staged after a documented disease-free interval, and is identified by the 'r' prefix: rTNM.

For the pN classification of regional lymph nodes, see ICCR Nodal excisions and neck dissection specimens dataset.³

Reporting of pathological staging categories (pT, pN, pM) is based on the evidence available to the pathologist at the time of reporting. As indicated in UICC TNM8 and AJCC TNM8,^{16,17} the final stage grouping of a patient's tumour is based on a combination of pathological staging and other clinical and imaging information.

Pathological staging should not be reported if the submitted specimen is insufficient for definitive staging, especially with biopsy samples (core needle, incisional or excisional). Staging is based on the submitted resection, and even if there is grossly residual disease or there is tumour at the margin, pT staging should only be reported on findings in the resection specimen and/or at operation.^{16,17}

The reference document TNM Supplement: A commentary on uniform use, 5th Edition (C Wittekind et al. editors) may be of assistance when staging.⁷⁸

↑ Back

References

- 1 Merlin T, Weston A and Tooher R (2009). Extending an evidence hierarchy to include topics other than treatment: revising the Australian 'levels of evidence'. *BMC Med Res Methodol* 9:34.
- 2 International Collaboration on Cancer Reporting (2024). *ICCR Datasets*. Available from: <https://www.iccr-cancer.org/datasets/published-datasets/> (Accessed 15th January 2024).
- 3 International Collaboration on Cancer Reporting (2024). *Nodal Excisions and Neck Dissection Specimens for Head & Neck Tumours Histopathology Reporting Guide. 2nd edition*. Available from: <https://www.iccr-cancer.org/datasets/published-datasets/head-neck/nodal-excisions/> (Accessed 31st July 2024).
- 4 WHO Classification of Tumours Editorial Board (2024). *Head and Neck Tumours, WHO Classification of Tumours, 5th Edition, Volume 10*. IARC Press, Lyon.

- 5 Koike K, Ohashi N, Nishiyama K, Okamoto J, Sasaki T, Ogi K, Dehari H, Hirokawa N, Someya M, Saito M, Okuda H, Otani A, Sonoda T, Sugawara T, Hasegawa T, Hiratsuka H, Sakata KI and Miyazaki A (2022). Clinical and histopathologic effects of neoadjuvant intra-arterial chemoradiotherapy with cisplatin in combination with oral S-1 on stage III and IV oral cancer. *Oral Surg Oral Med Oral Pathol Oral Radiol* 134(3):347-353.
- 6 Olmos M, Glajzer J, Büntemeyer TO, Frohwitter G, Ries J, Eckstein M, Hecht M, Lutz R, Kesting MR and Weber M (2021). Neoadjuvant Immunotherapy of Oral Squamous Cell Carcinoma: Case Report and Assessment of Histological Response. *Front Oncol* 11:720951.
- 7 Bonert M, Zafar U, Williams P, El-Shinnawy I, Juergens RA, Naqvi A, Cutz JC, Finley C, Major P and Kapoor A (2022). Physician and Surgeon Communication Assessed via the Pathology Requisition in a Regional Laboratory Over Ten Years. *Cureus* 14(8):e27714.
- 8 Rapidis AD, Gullane P, Langdon JD, Lefebvre JL, Scully C and Shah JP (2009). Major advances in the knowledge and understanding of the epidemiology, aetiopathogenesis, diagnosis, management and prognosis of oral cancer. *Oral Oncol* 45(4-5):299-300.
- 9 Shah JP and Gil Z (2009). Current concepts in management of oral cancer--surgery. *Oral Oncol* 45(4-5):394-401.
- 10 Nakhleh RE (2011). Quality in surgical pathology communication and reporting. *Arch Pathol Lab Med* 135(11):1394-1397.
- 11 Nakhleh RE, Myers JL, Allen TC, DeYoung BR, Fitzgibbons PL, Funkhouser WK, Mody DR, Lynn A, Fatheree LA, Smith AT, Lal A and Silverman JF (2012). Consensus statement on effective communication of urgent diagnoses and significant, unexpected diagnoses in surgical pathology and cytopathology from the College of American Pathologists and Association of Directors of Anatomic and Surgical Pathology. *Arch Pathol Lab Med* 136(2):148-154.
- 12 Yung AE, Que MS, Lo S, Aggarwal S, Hong AM, Tin MM, Clark JR, Gupta R and Ch'ng S (2021). Validation of the American Joint Committee on Cancer Staging in Squamous Cell Carcinoma of the Vermilion Lip. *Ann Surg Oncol* 28(6):3092-3099.
- 13 Bresadola L, Weber D, Ritzel C, Löwer M, Bukur V, Akilli-Öztürk Ö, Becker J, Mehanna H, Schrörs B, Vascotto F, Sahin U and Kong A (2021). Comprehensive Genomic and Transcriptomic Analysis of Three Synchronous Primary Tumours and a Recurrence from a Head and Neck Cancer Patient. *Int J Mol Sci* 22(14):7583.
- 14 Feng Z, Xu QS, Niu QF, Qin LZ, Li JZ, Su M, Li H and Han Z (2016). Risk factors for patients with multiple synchronous primary cancers involving oral and oropharyngeal subsites. *Oral Surg Oral Med Oral Pathol Oral Radiol* 121(4):360-366.
- 15 Thompson LDR, Fitzpatrick SG, Müller S, Eisenberg E, Upadhyaya JD, Lingen MW, Vigneswaran N, Woo SB, Bhattacharyya I, Bilodeau EA, Carlos R, Islam MN, Leon ME, Lewis JS, Jr., Magliocca KR, Mani H, Mehrad M, Purgina B, Richardson M, Wenig BM and Cohen DM (2021). Proliferative Verrucous Leukoplakia: An Expert Consensus Guideline for Standardized Assessment and Reporting. *Head Neck Pathol* 15(2):572-587.
- 16 Brierley JD, Gospodarowicz MK and Wittekind C (eds) (2016). *Union for International Cancer Control. TNM Classification of Malignant Tumours, 8th Edition*, Wiley, USA.

- 17 Amin MB, Edge SB, Greene FL, Byrd DR, Brookland RK, Washington MK, Gershenwald JE, Compton CC, Hess KR, Sullivan DC, Jessup JM, Brierley JD, Gaspar LE, Schilsky RL, Balch CM, Winchester DP, Asare EA, Madera M, Gress DM and Meyer LR (eds) (2017). *AJCC Cancer Staging Manual. 8th ed.*, Springer, New York.
- 18 Burns C and Gorina Faz M (2021). An Analysis of Tumor Margin Shrinkage in the Surgical Resection of Squamous Cell Carcinoma of the Oral Cavity. *Cureus* 13(5):e15329.
- 19 Muller S and Tilakaratne WM (2022). Update from the 5th Edition of the World Health Organization Classification of Head and Neck Tumors: Tumours of the Oral Cavity and Mobile Tongue. *Head Neck Pathol* 16(1):54-62.
- 20 Abé T, Yamazaki M, Maruyama S, Ikeda N, Sumita Y, Tomihara K and Tanuma JI (2022). Adenosquamous Carcinoma with the Acantholytic Feature in the Oral Cavity: A Case Report and Comprehensive Literature Review. *Diagnostics (Basel)* 12(10):2398.
- 21 Dos Santos ES, Rodrigues-Fernandes CI, Speight PM, Khurram SA, Alsanie I, Costa Normando AG, Prado-Ribeiro AC, Brandão TB, Kowalski LP, Silva Guerra EN, Lopes MA, Vargas PA, Santos-Silva AR and Leme AFP (2021). Impact of tumor site on the prognosis of salivary gland neoplasms: A systematic review and meta-analysis. *Crit Rev Oncol Hematol* 162:103352.
- 22 Ihrler S, Agaimy A, Guntinas-Lichius O, Haas CJ, Mollenhauer M, Sandison A and Greber L (2021). Why is the histomorphological diagnosis of tumours of minor salivary glands much more difficult? *Histopathology* 79(5):779-790.
- 23 International Collaboration on Cancer Reporting (2024). *Carcinomas of the major salivary glands Histopathology Reporting Guide. 2nd edition*. Available from: <https://www.iccr-cancer.org/datasets/published-datasets/head-neck/salivary-glands/> (Accessed 31st July 2024).
- 24 Fritz A, Percy C, Jack A, Shanmugaratnam K, Sobin L, Parkin DM and Whelan S (eds) (2020). *International Classification of Diseases for Oncology, Third edition, Second revision ICD-O-3.2*. Available from: http://www.iacr.com.fr/index.php?option=com_content&view=category&layout=blog&id=100&Itemid=577 (Accessed 16th March 2024).
- 25 Elseragy A, Bello IO, Wahab A, Coletta RD, Mäkitie AA, Leivo I, Almangush A and Salo T (2022). Emerging histopathologic markers in early-stage oral tongue cancer: A systematic review and meta-analysis. *Head Neck* 44(6):1481-1491.
- 26 Choi YS, Kim MG, Lee JH, Park JY and Choi SW (2022). Analysis of prognostic factors through survival rate analysis of oral squamous cell carcinoma patients treated at the National Cancer Center: 20 years of experience. *J Korean Assoc Oral Maxillofac Surg* 48(5):284-291.
- 27 Dolens EDS, Dourado MR, Almangush A, Salo TA, Gurgel Rocha CA, da Silva SD, Brennan PA and Coletta RD (2021). The Impact of Histopathological Features on the Prognosis of Oral Squamous Cell Carcinoma: A Comprehensive Review and Meta-Analysis. *Front Oncol* 11:784924.
- 28 Bal M, Sharma A, Rane SU, Mittal N, Chaukar D, Prabhash K and Patil A (2022). Neuroendocrine Neoplasms of the Larynx: A Clinicopathologic Analysis of 27 Neuroendocrine Tumors and Neuroendocrine Carcinomas. *Head Neck Pathol* 16(2):375-387.

- 29 Asa SL, Arkun K, Tischler AS, Qamar A, Deng FM, Perez-Ordonez B, Weinreb I, Bishop JA, Wenig BM and Mete O (2021). Middle Ear "Adenoma": a Neuroendocrine Tumor with Predominant L Cell Differentiation. *Endocr Pathol* 32(4):433-441.
- 30 Rivero A and Liang J (2016). Sinonasal small cell neuroendocrine carcinoma: a systematic review of 80 patients. *Int Forum Allergy Rhinol* 6(7):744-751.
- 31 Kuan EC, Alonso JE, Tajudeen BA, Arshi A, Mallen-St Clair J and St John MA (2017). Small cell carcinoma of the head and neck: A comparative study by primary site based on population data. *Laryngoscope* 127(8):1785-1790.
- 32 van der Laan TP, Iepma R, Witjes MJ, van der Laan BF, Plaat BE and Halmos GB (2016). Meta-analysis of 701 published cases of sinonasal neuroendocrine carcinoma: The importance of differentiation grade in determining treatment strategy. *Oral Oncol* 63:1-9.
- 33 Uccella S, La Rosa S, Metovic J, Marchiori D, Scoazec JY, Volante M, Mete O and Papotti M (2021). Genomics of High-Grade Neuroendocrine Neoplasms: Well-Differentiated Neuroendocrine Tumor with High-Grade Features (G3 NET) and Neuroendocrine Carcinomas (NEC) of Various Anatomic Sites. *Endocr Pathol* 32(1):192-210.
- 34 Bresciani L, Giannini L, Paderno A, Incandela F, Fontanella W, Mattavelli D and Piazza C (2021). Comparison of Different Staging Systems Applied to a Cohort of Patients With Oral Tongue and Floor of the Mouth Cancer. *Front Oral Health* 2:737329.
- 35 Almangush A, Bello IO, Coletta RD, Makitie AA, Makinen LK, Kauppila JH, Pukkila M, Hagstrom J, Laranne J, Soini Y, Kosma VM, Koivunen P, Kelner N, Kowalski LP, Grenman R, Leivo I, Laara E and Salo T (2015). For early-stage oral tongue cancer, depth of invasion and worst pattern of invasion are the strongest pathological predictors for locoregional recurrence and mortality. *Virchows Arch* 467(1):39-46.
- 36 Almangush A, Bello IO, Keski-Santti H, Makinen LK, Kauppila JH, Pukkila M, Hagstrom J, Laranne J, Tommola S, Nieminen O, Soini Y, Kosma VM, Koivunen P, Grenman R, Leivo I and Salo T (2014). Depth of invasion, tumor budding, and worst pattern of invasion: prognostic indicators in early-stage oral tongue cancer. *Head Neck* 36(6):811-818.
- 37 Dhanda J, Uppal N, Chowlia H, Opie N, Al-Qamachi L, Shelat D, Aslam A, Yuffa A, Martin T, Risk J, Triantafyllou A, Shaw R, Parmar S and Mehanna H (2016). Features and prognostic utility of biopsy in oral squamous cell carcinoma. *Head Neck* 38 Suppl 1:E1857-1862.
- 38 Dang RR, Kim J, Qureshi MM, Fazeli SR, Zhao Q, Noonan VL, Sundararajan D, Salama A and Truong MT (2023). Impact of depth of invasion on local recurrence in R0 resected node-negative oral tongue squamous cell carcinoma. *Head Neck* 45(3):561-566.
- 39 Kligerman MP, Moon PK, Tusty M, Cloutier JM, Ma Y, Holsinger CF and Divi V (2023). Impact of Histologic Risk Factors on Recurrence Rates for Oral Cavity Squamous Cell Carcinoma. *Ann Otol Rhinol Laryngol* 132(7):731-737.
- 40 Xu B, Salama AM, Valero C, Yuan A, Khimraj A, Saliba M, Zaroni DK, Ganly I, Patel SG, Katabi N and Ghossein R (2021). The prognostic role of histologic grade, worst pattern of invasion, and tumor budding in early oral tongue squamous cell carcinoma: a comparative study. *Virchows Arch* 479(3):597-606.

- 41 Chatterjee D, Bansal V, Malik V, Bhagat R, Punia RS, Handa U, Gupta A and Dass A (2019). Tumor Budding and Worse Pattern of Invasion Can Predict Nodal Metastasis in Oral Cancers and Associated With Poor Survival in Early-Stage Tumors. *Ear Nose Throat J* 98(7):E112-e119.
- 42 Mäkitie AA, Almangush A, Rodrigo JP, Ferlito A and Leivo I (2019). Hallmarks of cancer: Tumor budding as a sign of invasion and metastasis in head and neck cancer. *Head Neck* 41(10):3712-3718.
- 43 Beute JE, Greenberg LA, Wein LE, Kapustin DA, Fan J, Dowling EM, Samankan S, Matloob A, Xing M, Modica I, Chung D, Carroll W, Rosenthal EL, Khan MN, Chai RL, Brandwein-Weber MS and Urken ML (2023). WPOI-5: Accurately Identified at Intraoperative Consultation and Predictive of Occult Cervical Metastases. *Head Neck Pathol* 17(2):479-486.
- 44 Mishra A, Das A, Dhal I, Shankar R, Bhavya BM, Singh N, Tripathi P, Daga D, Rai A, Gupta M and Sahu GC (2022). Worst pattern of invasion in oral squamous cell carcinoma is an independent prognostic factor. *J Oral Biol Craniofac Res* 12(6):771-776.
- 45 Sarode GS, Sarode SC, Deshmukh R, Anand R and Patil S (2017). Tumor Budding in Oral Squamous Cell Carcinoma. *J Contemp Dent Pract* 18(9):743-744.
- 46 Shimizu S, Miyazaki A, Sonoda T, Koike K, Ogi K, Kobayashi JI, Kaneko T, Igarashi T, Ueda M, Dehari H, Miyakawa A, Hasegawa T and Hiratsuka H (2018). Tumor budding is an independent prognostic marker in early stage oral squamous cell carcinoma: With special reference to the mode of invasion and worst pattern of invasion. *PLoS One* 13(4):e0195451.
- 47 Hong KO, Oh KY, Shin WJ, Yoon HJ, Lee JI and Hong SD (2018). Tumor budding is associated with poor prognosis of oral squamous cell carcinoma and histologically represents an epithelial-mesenchymal transition process. *Hum Pathol* 80:123-129.
- 48 Xie N, Yu P, Liu H, Liu X, Hou J, Chen X, Huang H and Wang C (2019). Validation of the International Tumor Budding Consensus Conference (2016) recommendations in oral tongue squamous cell carcinoma. *J Oral Pathol Med* 48(6):451-458.
- 49 Bjerkli IH, Laurvik H, Nginamau ES, Sjøland TM, Costea D, Hov H, Uhlin-Hansen L, Hadler-Olsen E and Steigen SE (2020). Tumor budding score predicts lymph node status in oral tongue squamous cell carcinoma and should be included in the pathology report. *PLoS One* 15(9):e0239783.
- 50 Hori Y, Kubota A, Yokose T, Furukawa M, Matsushita T, Katsumata N and Oridate N (2021). Prognostic Role of Tumor-Infiltrating Lymphocytes and Tumor Budding in Early Oral Tongue Carcinoma. *Laryngoscope* 131(11):2512-2518.
- 51 Joshi P, Pol J, Chougule M, Jadhav K, Patil S and Patil S (2020). Tumor budding - A promising prognostic histopathological parameter in oral squamous cell carcinoma - A comparative immunohistochemical study. *J Oral Maxillofac Pathol* 24(3):587.
- 52 Noda Y, Ishida M, Ueno Y, Fujisawa T, Iwai H and Tsuta K (2022). Novel pathological predictive factors for extranodal extension in oral squamous cell carcinoma: a retrospective cohort study based on tumor budding, desmoplastic reaction, tumor-infiltrating lymphocytes, and depth of invasion. *BMC Cancer* 22(1):402.

- 53 Boxberg M, Kuhn PH, Reiser M, Erb A, Steiger K, Pickhard A, Straßen U, Koob I, Kolk A, Warth A, Jesinghaus M and Weichert W (2019). Tumor Budding and Cell Nest Size Are Highly Prognostic in Laryngeal and Hypopharyngeal Squamous Cell Carcinoma: Further Evidence for a Unified Histopathologic Grading System for Squamous Cell Carcinomas of the Upper Aerodigestive Tract. *Am J Surg Pathol* 43(3):303-313.
- 54 Singh A, Mair M, Singhvi H, Mahuvakar A, Nair D, Nair S and Chaturvedi P (2019). Incidence, predictors and impact of positive bony margins in surgically treated T4 stage cancers of the oral cavity. *Oral Oncol* 90:8-12.
- 55 Comer JC, Harris AB, Hess AO, Hitchcock KE, Mendenhall WM, Bates JE and Dziegielewski PT (2023). Does lymphovascular invasion predict survival in oral cancer? A population-based analysis. *Oral Oncol* 140:106387.
- 56 Mascitti M, Togni L, Caponio VCA, Zhurakivska K, Bizzoca ME, Contaldo M, Serpico R, Lo Muzio L and Santarelli A (2022). Lymphovascular invasion as a prognostic tool for oral squamous cell carcinoma: a comprehensive review. *Int J Oral Maxillofac Surg* 51(1):1-9.
- 57 Mäkitie AA, Agaimy A and Almangush A (2022). Insight into Classification and Risk Stratification of Head and Neck Squamous Cell Carcinoma in Era of Emerging Biomarkers with Focus on Histopathologic Parameters. *Cancers (Basel)* 14(22):5514.
- 58 Higginson JA, Breik O, Thompson AH, Ashrafian H, Hardman JC, Takats Z, Paleri V and Dhanda J (2023). Diagnostic accuracy of intraoperative margin assessment techniques in surgery for head and neck squamous cell carcinoma: A meta-analysis. *Oral Oncol* 142:106419.
- 59 MacKay C, Turner B, Bullock M, Taylor SM, Trites J, Corsten M, Geldenhuys L and Rigby MH (2022). Margin Sampling and Survival Outcomes in Oral Cavity and p16-Positive Oropharyngeal Squamous Cell Carcinoma. *OTO Open* 6(3):2473974x221101024.
- 60 Chiosea SI (2017). Intraoperative Margin Assessment in Early Oral Squamous Cell Carcinoma. *Surg Pathol Clin* 10(1):1-14.
- 61 K K, Kamboj V, Sreedharan S, S VS, Rai T and Kabekkodu S (2022). Effect of formalin fixation on tumour size and margins in head and neck cancer specimens. *Acta Otorhinolaryngol Ital* 42(5):434-440.
- 62 Tenore G, Mohsen A, Nuvoli A, Palaia G, Rocchetti F, Di Gioia CRT, Cicconetti A, Romeo U and Del Vecchio A (2023). The Impact of Laser Thermal Effect on Histological Evaluation of Oral Soft Tissue Biopsy: Systematic Review. *Dent J (Basel)* 11(2):28.
- 63 Puram SV, Mays AC, Bayon R, Bell D, Chung J, Fundakowski CE, Johnson BT, Massa ST, Sharma A and Varvares MA (2023). Margins in Stage I and II Oral Cavity Squamous Cell Carcinoma: A Review From the American Head and Neck Society. *JAMA Otolaryngol Head Neck Surg* 149(7):636-642.
- 64 Long SM, McLean T, Valero Mayor C, Fitzgerald CWR, Feit NZ, Katabi N, Xu B, Cohen MA, Ganly I, Ghossein RA and Patel SG (2022). Use of Intraoperative Frozen Section to Assess Final Tumor Margin Status in Patients Undergoing Surgery for Oral Cavity Squamous Cell Carcinoma. *JAMA Otolaryngol Head Neck Surg* 148(10):911-917.

- 65 Wolk R and Lingen MW (2023). Proceedings of the North American Society of Head and Neck Pathology Companion Meeting, New Orleans, LA, March 12, 2023: Oral Cavity Dysplasia: Why Does Histologic Grading Continue to be Contentious? *Head Neck Pathol* 17(2):292-298.
- 66 Sperandio M, Warnakulasuriya S, Soares AB, Passador-Santos F, Mariano FV, Lima CSP, Scarini JF, Dominguet MHL, de Camargo Moraes P, Montalli VAM, Hellmeister L and de Araújo VC (2023). Oral epithelial dysplasia grading: Comparing the binary system to the traditional 3-tier system, an actuarial study with malignant transformation as outcome. *J Oral Pathol Med* 52(5):418-425.
- 67 Odell E, Kujan O, Warnakulasuriya S and Sloan P (2021). Oral epithelial dysplasia: Recognition, grading and clinical significance. *Oral Dis* 27(8):1947-1976.
- 68 Kujan O, Mello FW and Warnakulasuriya S (2021). Malignant transformation of oral submucous fibrosis: A systematic review and meta-analysis. *Oral Dis* 27(8):1936-1946.
- 69 Gervazio TC, Silva JK, Evangelista K, Cavalcanti MGP, Silva M, Yamamoto-Silva FP and Silva BSF (2022). Risk of oral cancer in patients with graft-vs-host disease: A systematic review and meta-analysis. *Oral Surg Oral Med Oral Pathol Oral Radiol* 133(6):650-662.
- 70 Rindi G, Klimstra DS, Abedi-Ardekani B, Asa SL, Bosman FT, Brambilla E, Busam KJ, de Krijger RR, Dietel M, El-Naggar AK, Fernandez-Cuesta L, Klöppel G, McCluggage WG, Moch H, Ohgaki H, Rakha EA, Reed NS, Rous BA, Sasano H, Scarpa A, Scoazec JY, Travis WD, Tallini G, Trouillas J, van Krieken JH and Cree IA (2018). A common classification framework for neuroendocrine neoplasms: an International Agency for Research on Cancer (IARC) and World Health Organization (WHO) expert consensus proposal. *Mod Pathol* 31(12):1770-1786.
- 71 Zidar N and Gale N (2022). Update from the 5th Edition of the World Health Organization Classification of Head and Neck Tumors: Hypopharynx, Larynx, Trachea and Parapharyngeal Space. *Head Neck Pathol* 16(1):31-39.
- 72 Wenig BM (2015). Lymphoepithelial-like carcinomas of the head and neck. *Semin Diagn Pathol* 32(1):74-86.
- 73 Ferris RL, Blumenschein G, Jr., Fayette J, Guigay J, Colevas AD, Licitra L, Harrington K, Kasper S, Vokes EE, Even C, Worden F, Saba NF, Iglesias Docampo LC, Haddad R, Rordorf T, Kiyota N, Tahara M, Monga M, Lynch M, Geese WJ, Kopit J, Shaw JW and Gillison ML (2016). Nivolumab for Recurrent Squamous-Cell Carcinoma of the Head and Neck. *N Engl J Med* 375(19):1856-1867.
- 74 Cohen EEW, Soulières D, Le Tourneau C, Dinis J, Licitra L, Ahn MJ, Soria A, Machiels JP, Mach N, Mehra R, Burtness B, Zhang P, Cheng J, Swaby RF and Harrington KJ (2019). Pembrolizumab versus methotrexate, docetaxel, or cetuximab for recurrent or metastatic head-and-neck squamous cell carcinoma (KEYNOTE-040): a randomised, open-label, phase 3 study. *Lancet* 393(10167):156-167.
- 75 Seiwert TY, Burtness B, Mehra R, Weiss J, Berger R, Eder JP, Heath K, McClanahan T, Lunceford J, Gause C, Cheng JD and Chow LQ (2016). Safety and clinical activity of pembrolizumab for treatment of recurrent or metastatic squamous cell carcinoma of the head and neck (KEYNOTE-012): an open-label, multicentre, phase 1b trial. *Lancet Oncol* 17(7):956-965.

- 76 Burtneß B, Harrington KJ, Greil R, Soulières D, Tahara M, de Castro G, Jr., Psyrri A, Basté N, Neupane P, Bratland Å, Fueeder T, Hughes BGM, Mesía R, Ngamphaiboon N, Rordorf T, Wan Ishak WZ, Hong RL, González Mendoza R, Roy A, Zhang Y, Gumuscu B, Cheng JD, Jin F and Rischin D (2019). Pembrolizumab alone or with chemotherapy versus cetuximab with chemotherapy for recurrent or metastatic squamous cell carcinoma of the head and neck (KEYNOTE-048): a randomised, open-label, phase 3 study. *Lancet* 394(10212):1915-1928.
- 77 Litchfield K, Reading JL, Puttick C, Thakkar K, Abbosh C, Bentham R, Watkins TBK, Rosenthal R, Biswas D, Rowan A, Lim E, Al Bakir M, Turati V, Guerra-Assunção JA, Conde L, Furness AJS, Saini SK, Hadrup SR, Herrero J, Lee SH, Van Loo P, Enver T, Larkin J, Hellmann MD, Turajlic S, Quezada SA, McGranahan N and Swanton C (2021). Meta-analysis of tumor- and T cell-intrinsic mechanisms of sensitization to checkpoint inhibition. *Cell* 184(3):596-614.e514.
- 78 Wittekind C, Brierley JD, van Eycken AL and van Eycken E (eds) (2019). *TNM Supplement: A Commentary on Uniform Use, 5th Edition*, Wiley, USA.