

Sponsored by



# Nodal Excisions and Neck Dissection Specimens for Head & Neck Tumours Histopathology Reporting Guide



Family/Last name

Date of birth

Given name(s)

Patient identifiers

Date of request

Accession/Laboratory number

Elements in **black text** are CORE. Elements in **grey text** are NON-CORE.

[SCOPE OF THIS DATASET](#)

## OPERATIVE PROCEDURE (select all that apply) (Note 1)

- Not specified
- Selective neck dissection
  - Supraomohyoid
  - Lateral
  - Posterolateral
  - Central (anterior) compartment
- Comprehensive neck dissection
  - Modified radical neck dissection
  - Radical neck dissection
  - Extended radical neck dissection

Lymph node biopsy, *specify site*

Other, *specify*

Left

- Lymph nodes
  - Not specified
  - Submental (IA)
  - Submandibular (IB)
  - Upper jugular (II)
  - Middle jugular (III)
  - Lower jugular (IV)
  - Posterior triangle (V)
  - Retropharyngeal
  - Parotid/periparotid
  - Perifacial
  - Other, *specify*

- Non-lymphoid tissue
  - Nerve
  - Muscle
  - Vein
  - Salivary gland
  - Other, *specify*

## SPECIMENS SUBMITTED (select all that apply) (Note 2)

Right

- Lymph nodes
  - Not specified
  - Submental (IA)
  - Submandibular (IB)
  - Upper jugular (II)
  - Middle jugular (III)
  - Lower jugular (IV)
  - Posterior triangle (V)
  - Retropharyngeal
  - Parotid/periparotid
  - Perifacial
  - Other, *specify*

- Non-lymphoid tissue
  - Nerve
  - Muscle
  - Vein
  - Salivary gland
  - Other, *specify*

Central compartment (VI +/- VII)

- Non-lymphoid tissue
  - Thymus
  - Parathyroid
  - Other, *specify*

**HISTOLOGICAL TUMOUR TYPE** (select all that apply) (Note 3)  
 (Value list from the World Health Organization Classification of Head and Neck Tumours (2017))

**Squamous cell carcinoma (SCC)**

- Squamous cell carcinoma, conventional
- HPV-mediated/p16 positive oropharyngeal carcinoma
- Basaloid squamous cell carcinoma
- Papillary squamous cell carcinoma
- Spindle cell squamous carcinoma (sarcomatoid carcinoma)
- Adenosquamous cell carcinoma
- Acantholytic squamous cell carcinoma
- Carcinoma cuniculatum
- Undifferentiated (lymphoepithelial) carcinoma

**Salivary gland carcinoma**

- Acinic cell carcinoma
- Secretory carcinoma
- Mucoepidermoid carcinoma
  - Low grade mucoepidermoid carcinoma
  - Intermediate grade mucoepidermoid carcinoma
  - High grade mucoepidermoid carcinoma
- Adenoid cystic carcinoma
  - Tubular/cribriform pattern predominant
  - Solid pattern >30%
- Polymorphous adenocarcinoma
  - Classic
  - Cribriform

Grade, specify

- Epithelial-myoepithelial carcinoma
- (Hyalinizing) Clear cell carcinoma
- Basal cell adenocarcinoma
- Sebaceous adenocarcinoma
- Intraductal carcinoma
  - Low grade
  - High grade
- Cystadenocarcinoma
- Adenocarcinoma, not otherwise specified (NOS)
- Salivary duct carcinoma
- Myoepithelial carcinoma
- Carcinoma ex pleomorphic adenoma

Type(s), specify

- Carcinosarcoma
- Poorly differentiated carcinoma: Neuroendocrine and non-neuroendocrine
  - Undifferentiated carcinoma
  - Large cell neuroendocrine carcinoma
  - Small cell neuroendocrine carcinoma

- Lymphoepithelial carcinoma
- Squamous cell carcinoma
- Oncocytic carcinoma
- Other, specify

**Neuroendocrine carcinoma**

- Well-differentiated (typical carcinoid)
- Moderately differentiated (atypical carcinoid)
- Poorly differentiated (high grade neuroendocrine carcinoma), large cell type
- Poorly differentiated (high grade neuroendocrine carcinoma), small cell type

**Mucosal melanoma**

**Nasopharyngeal carcinoma**

- Squamous cell carcinoma, keratinizing
- Squamous cell carcinoma, non-keratinizing, differentiated
- Squamous cell carcinoma, non-keratinizing, undifferentiated
- Squamous cell carcinoma, basaloid
- Nasopharyngeal papillary adenocarcinoma

Other (e.g. primary adnexal skin cancers), specify type

**Primary tumour site**

- Not specified/unknown
- Specify site (e.g. oral cavity, larynx)

**MARGIN STATUS** (Note 5)

**Involvement of perinodal surgical margin**

- Not involved by carcinoma
- Involved by carcinoma
  - Left
  - Right
  - Central
  - Laterality not specified
- Cannot be assessed, specify

**ANCILLARY STUDIES** (Note 6)

- Not performed
- Performed, specify test, result, method

**LYMPH NODE STATUS** (Note 4)

**Right sided lymph nodes**

Node level	Number of nodes examined*	Number of nodes positive*	Extranodal extension (ENE)** <input type="radio"/> Not identified <input type="radio"/> ENEmi ( $\leq 2$ mm) <input type="radio"/> ENEmi ( $> 2$ mm)	Number of nodes with ENE*
Submental IA				
Submandibular IB				
Upper jugular II				
Middle jugular III				
Lower jugular IV				
Posterior triangle V				

\* Insert "cannot be determined" when applicable.

\*\* Non-core item for HPV-related/p16 positive oropharyngeal cancer and nasopharyngeal cancer.

**Maximum dimension of largest lymph node metastasis** (if applicable)  mm

**Maximum dimension of largest involved lymph node** (if applicable)  mm

Specify site (level)

**Greatest extent of ENE** (if applicable)  mm

Specify site (level)

**Soft tissue metastasis**

- Not identified  
 Present, specify site (level)

**Non-lymphatic structures involved**

- Not identified  
 Present, specify

**Left sided lymph nodes**

Node level	Number of nodes examined*	Number of nodes positive*	ENE** <input type="radio"/> Not identified <input type="radio"/> ENEmi ( $\leq 2$ mm) <input type="radio"/> ENEmi ( $> 2$ mm)	Number of nodes with ENE*
Submental IA				
Submandibular IB				
Upper jugular II				
Middle jugular III				
Lower jugular IV				
Posterior triangle V				

\* Insert "cannot be determined" when applicable.

\*\* Non-core item for HPV-related/p16 positive oropharyngeal cancer and nasopharyngeal cancer.

**Maximum dimension of largest lymph node metastasis** (if applicable)  mm

**Maximum dimension of largest involved lymph node** (if applicable)  mm

Specify site (level)

**Greatest extent of ENE** (if applicable)  mm

Specify site (level)

**Soft tissue metastasis**

- Not identified  
 Present, specify site (level)

**Non-lymphatic structures involved**

- Not identified  
 Present, specify

**Central compartment lymph nodes**

**Number of lymph nodes examined\***

**Number of lymph nodes positive\***

**ENE\*\***

- Not identified  
 ENEmi ( $\leq 2$  mm)  
 ENEMA ( $> 2$  mm)

**Number of lymph nodes with ENE\***

**Maximum dimension of largest lymph node metastasis** (if applicable)  mm

**Maximum dimension of largest involved lymph node** (if applicable)  mm

*Specify site (level)*

**Greatest extent of ENE** (if applicable)  mm

*Specify site (level)*

**Soft tissue metastasis**

- Not identified  
 Present, *specify site (level)*

**Non-lymphatic structures involved**

- Not identified  
 Present, *specify*

\* *Insert "cannot be determined" when applicable.*

\*\* *Non-core item for HPV-related/p16 positive oropharyngeal cancer and nasopharyngeal cancer.*

**REGIONAL LYMPH NODE CATEGORISATION (Note 7) (UICC TNM 8th edition)\*\***

**TNM Descriptors** (only if applicable) (select all that apply)

- r - recurrent  
 y - post-therapy

*For primary carcinomas of the lip and oral cavity, major salivary glands, nasal cavity and paranasal sinuses, oropharynx (p16 negative), hypopharynx, larynx, cutaneous head and neck carcinomas (with the exception of Merkel cell carcinoma) and unknown primary squamous cell carcinomas that are p16 and EBV-negative.*

- NX Regional lymph nodes cannot be assessed  
 N0 No regional lymph node metastasis  
 N1 Metastasis in a single ipsilateral lymph node, 3 cm or less in greatest dimension without ENE  
N2 Metastasis described as:  
 N2a Metastasis in a single ipsilateral lymph node, 3 cm or less in greatest dimension with ENE or more than 3 cm but not more than 6 cm in greatest dimension without ENE  
 N2b Metastasis in multiple ipsilateral nodes, none more than 6 cm in greatest dimension, without ENE  
 N2c Metastasis in bilateral lymph nodes, none more than 6 cm in greatest dimension, without ENE  
 N3a Metastasis in a lymph node more than 6 cm in greatest dimension without ENE  
 N3b Metastasis in a lymph node more than 3 cm in greatest dimension with ENE or, multiple ipsilateral, or any contralateral or bilateral node(s) with ENE

**HPV-mediated (p16+) oropharyngeal carcinoma**

- NX Regional lymph nodes cannot be assessed  
 N0 No regional lymph node metastasis  
 N1 Metastasis in 1 to 4 lymph node(s)  
 N2 Metastasis in 5 or more lymph node(s)

**Nasopharyngeal carcinoma**

- NX Regional lymph nodes cannot be assessed  
 N0 No regional lymph node metastasis  
 N1 Unilateral metastasis in cervical lymph node(s) and/or unilateral or bilateral metastasis in retropharyngeal lymph node(s), 6 cm or smaller in greatest dimension, above the caudal border of cricoid cartilage  
 N2 Bilateral metastasis in cervical lymph node(s), 6 cm or smaller in greatest dimension, above the caudal border of cricoid cartilage  
 N3 Metastasis in cervical lymph node(s), greater than 6 cm in dimension, and/or extension below the caudal border of the cricoid cartilage

**Mucosal melanoma**

- NX Regional lymph nodes cannot be assessed  
 N0 No regional lymph node metastasis  
 N1 Regional lymph node metastasis present

## Reproduced with permission. Source: UICC TNM Classification of Malignant Tumours, 8th Edition, eds James D. Brierley, Mary K. Gospodarowicz, Christian Wittekind. 2017, Publisher Wiley-Blackwell.

## Scope

The dataset has been developed for the reporting of lymph node resections from patients with carcinomas and melanomas of the head and neck. This excludes nodal resections for lymphoma and sarcomas. It is not intended for use in reporting lymph node core biopsy or fine needle aspirations. Carcinomas covered by the dataset include squamous cell carcinomas, sinonasal carcinomas, salivary and non-salivary type adenocarcinomas and neuroendocrine tumours. Pathologists may also apply the dataset to metastatic non-Merkel cutaneous squamous cell carcinomas and other cutaneous carcinomas.<sup>1</sup>

This dataset is to be used in conjunction with other datasets in the Head and Neck Series. Lymph node excisional biopsies or neck dissections may precede, accompany or follow the biopsy or resection of a primary tumour. Concurrent reporting of the lymph node and primary tumour dataset elements - ideally in the same report - is preferable, as it provides clinicians with the most comprehensive information for tumour stage categorisation. Pathologists should consider the impact of prior intervention (e.g. prior diagnostic lymph node excisional biopsy in a patient with a neck mass) on the pN category, making reference to the previous surgical pathology specimen, if available. Similarly, neck dissections may be performed as “salvage surgery” following radiation and/or chemotherapy. These adjuvant or non-adjuvant interventions may affect pN category by reducing the bulk of tumour, or perhaps eliminating it altogether.

## Note 1 – Operative procedure (Non-core)

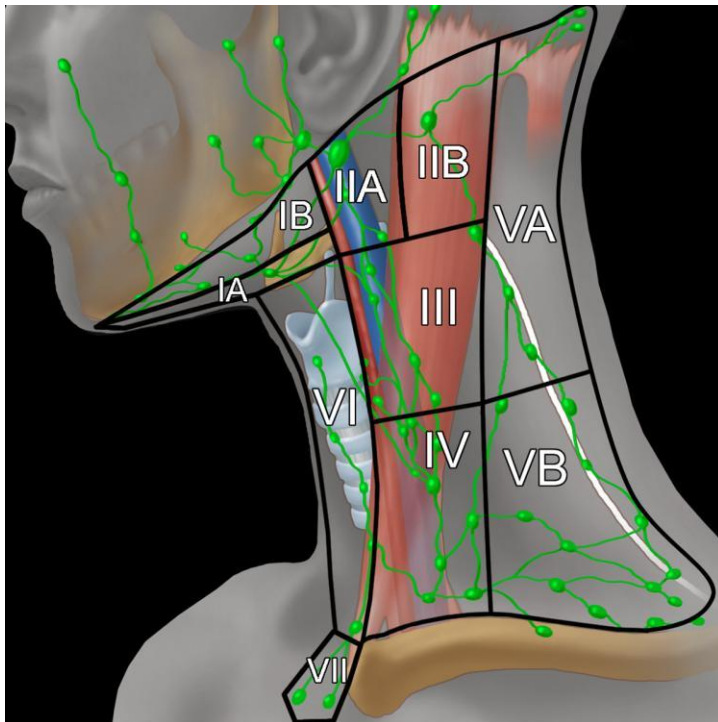
### Reason/Evidentiary Support:

Accurate designation of the operative procedure requires appropriate information from the head and neck surgeon, ideally with specimen orientation. A single operation may encompass more than one of the above-designated procedures, and the terminology may vary by institution. Some experts have proposed eliminating the above terminology, in favour of a more simplistic designation that includes the lymph node levels received and a listing of non-lymphatic structures that accompany them.<sup>2</sup> In some cases, it is not possible to specify or be certain of the operative procedure, and thus this element is considered non-core.

### NECK DISSECTION TERMINOLOGY

The best known classification of lymph node groups in the neck is the so-called Robbins’ classification, originally proposed by the American Academy of Otolaryngology – Head and Neck Surgery<sup>3</sup> in which the lymph node basins of the neck are divided into levels I to VI, as per the anatomical boundaries described further below and illustrated in Figure 1. This classification only includes lymph nodes commonly removed during neck dissection procedures, and therefore it does not include all the head and neck node groups such as the facial nodes. Level VII (the superior mediastinal lymph node compartment) is included in the illustration for completeness, but except for thyroid cancer, it is rarely involved by head and neck cancer. Additional node groups are described in the TNM atlas terminology, which divides the nodes into 12 groups, including

retropharyngeal, parotid, buccal, retroauricular and occipital nodes (see Figure 2).<sup>4</sup> Further subdivisions of several node levels, based on specific anatomical landmarks, has clinical significance because they tend to be involved preferentially by tumours of specific primary sites. For instance, level IIb is more commonly involved by primary tumours of the oropharynx or nasopharynx, than by primaries of the oral cavity, hypopharynx or larynx.<sup>5</sup>



**Figure 1. Illustration of the major neck lymph node levels, with anatomical boundaries, that are resected during neck dissections.** This figure was published in *Imaging Anatomy: Brain, Head and Neck, Spine. Diagnostic and Surgical Imaging Anatomy, Cervical Lymph nodes, 2006, Gordon H and Harsnberger HR, page 253, Copyright Amirsys/Elsevier (2006). Reproduced with permission.*

The boundaries of the lymph node groups found within the levels and sublevels of the neck are as follows:<sup>1</sup>

**Submental (sublevel IA)**

Lymph nodes within the triangular boundary of the anterior belly of the digastric muscles and the hyoid bone. These nodes are at greatest risk for harbouring metastases from cancers arising from the floor of mouth, anterior oral tongue, anterior mandibular alveolar ridge, and lower lip.

**Submandibular (sublevel IB)**

Lymph nodes within the boundaries of the anterior belly of the digastric muscle, the stylohyoid muscle, and the body of the mandible. It includes the preglangular and the postglangular nodes and the prevascular and postvascular nodes. The submandibular gland is included in the specimen when the lymph nodes within the triangle are removed. These nodes are at greatest risk for harbouring

metastases from cancers arising from the oral cavity, anterior nasal cavity, soft tissue structures of the midface, and submandibular gland.

### **Upper jugular (includes sublevels IIA and IIB)**

Lymph nodes located around the upper third of the internal jugular vein and adjacent spinal accessory nerve extending from the level of the skull base (above) to the level of the inferior border of the hyoid bone (below). The anterior (medial) boundary is the stylohyoid muscle (the radiologic correlate is the vertical plane defined by the posterior surface of the submandibular gland) and the posterior (lateral) boundary is the posterior border of the sternocleidomastoid muscle. Sublevel IIA nodes are located anterior (medial) to the vertical plane defined by the spinal accessory nerve. Sublevel IIB nodes are located posterior (lateral) to the vertical plane defined by the spinal accessory nerve. The upper jugular nodes are at greatest risk for harbouring metastases from cancers arising from the oral cavity, nasal cavity, nasopharynx, oropharynx, hypopharynx, larynx, and parotid gland.

### **Middle jugular (level III)**

Lymph nodes located around the middle third of the internal jugular vein extending from the inferior border of the hyoid bone (above) to the inferior border of the cricoid cartilage (below). The anterior (medial) boundary is the lateral border of the sternohyoid muscle, and the posterior (lateral) boundary is the posterior border of the sternocleidomastoid muscle. These nodes are at greatest risk for harbouring metastases from cancers arising from the oral cavity, nasopharynx, oropharynx, hypopharynx, and larynx.

### **Lower jugular (level IV)**

Lymph nodes located around the lower third of the internal jugular vein extending from the inferior border of the cricoid cartilage (above) to the clavicle below. The anterior (medial) boundary is the lateral border of the sternohyoid muscle and the posterior (lateral) boundary is the posterior border of the sternocleidomastoid muscle. These nodes are at greatest risk for harbouring metastases from cancers arising from the hypopharynx, thyroid, cervical oesophagus, and larynx.

### **Posterior triangle group (includes sub levels VA and VB)**

The group is composed predominantly of the lymph nodes located along the lower half of the spinal accessory nerve and the transverse cervical artery. The supraclavicular nodes are also included in posterior triangle group. The superior boundary is the apex formed by convergence of the sternocleidomastoid and trapezius muscles, the inferior boundary is the clavicle, the anterior (medial) boundary is the posterior border of the sternocleidomastoid muscle, and the posterior (lateral) boundary is the anterior border of the trapezius muscle. Sublevel VA is separated from sublevel VB by a horizontal plane marking the inferior border of the anterior cricoid arch. Thus, sublevel VA includes the spinal accessory nodes, whereas sublevel VB includes the nodes following the transverse cervical vessels and the supraclavicular nodes with the exception of the Virchow node, which is located in level IV. The posterior triangle nodes are at greatest risk for harbouring metastases from cancers arising from the nasopharynx, oropharynx, and cutaneous structures of the posterior scalp and neck.

### **Anterior compartment group (level VI)**

Lymph nodes in this compartment include the pretracheal and paratracheal nodes, precricoid (Delphian) node, and the perithyroidal nodes including the lymph nodes along the recurrent laryngeal nerves. The superior boundary is the hyoid bone, the inferior boundary is the suprasternal notch, and the lateral boundaries are the common carotid arteries. These nodes are at greatest risk for harbouring metastases from cancers arising from the thyroid gland, glottic and subglottic larynx, apex of the piriform sinus, and cervical oesophagus.

### **Superior mediastinal (level VII)**

Lymph nodes in this group include pretracheal, paratracheal and oesophageal groove lymph nodes, extending from the level of suprasternal notch cephalad and up to the innominate artery caudad. These nodes are at greatest risk of involvement by thyroid cancer and cancer of the oesophagus.

The most widely used classification of neck dissection procedures is based on the original system proposed by the Committee for Head and Neck Surgery and Oncology of the American Academy of Otolaryngology-Head and Neck Surgery in 1991.<sup>3</sup> This was revised in 2002<sup>6</sup> and updated in 2008.<sup>7</sup> The classification includes 4 basic procedures: *radical* neck dissection, *modified radical* neck dissection, *extended* neck dissection and *selective* neck dissection. The term *comprehensive* neck dissection refers to any neck dissection in which all nodes in levels I to V are removed, and therefore it includes *radical*, *modified radical* and *extended* neck dissections, as explained below.<sup>8</sup>

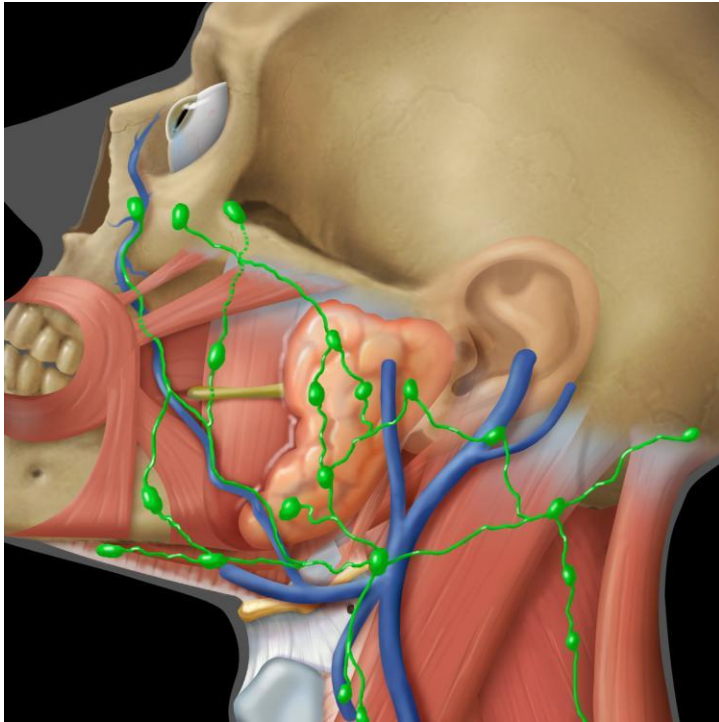
A *radical* neck dissection involves removal of levels I-V, as well the sternocleidomastoid muscle, spinal accessory nerve and internal jugular vein. A *modified radical* neck dissection spares at least one of the above non-lymphatic structures. An *extended* neck dissection involves removal of additional lymph nodes or non-lymphatic structures, beyond those removed as part of a radical neck dissection.

A *selective* neck dissection is a more limited procedure, in which one or more of the level I to V lymph node groups are spared, typically for malignancies of specific locations and with no or limited clinical evidence of lymph node involvement (N0 or N1).<sup>9</sup> *Supraomohyoid* neck dissection refers to removal of levels I to III, and is commonly performed for tumours of the oral cavity. *Lateral* neck dissection refers to removal of levels II to IV, performed for tumours of the larynx, oropharynx and hypopharynx. *Posterolateral* neck dissection refers to removal of levels II to V, for example for skin malignancies of the posterior scalp or upper, posterolateral neck.

*Central* or *anterior compartment* neck dissection removes level VI nodes (pretracheal, paratracheal, precricoid/Delphian and perithyroidal nodes) and is most commonly performed during surgery for thyroid carcinoma. Level VI lymph nodes are uncommonly received as neck dissections for head and neck skin or mucosal malignancies, but these nodes may be involved by primary cancers of the larynx or hypopharynx. Superior mediastinal nodes (level VII) may also be removed in central neck dissections, particularly for thyroid cancer.

A conspicuous member of the “other” category is the parotid lymph node basin, which is usually received as part of a parotidectomy specimen for primary salivary gland tumours or for metastatic skin cancers of the face and scalp (see Figure 2).





**Figure 2.** Head and neck lymph node groups of the facial area, including the parotid, bucco-facial, retroauricular and occipital groups. These nodes are more commonly involved with tumours of the head and neck skin and parotid gland. This figure was published in *Imaging Anatomy: Brain, Head and Neck, Spine. Diagnostic and Surgical Imaging Anatomy, Cervical Lymph nodes*, 2006, Gordon H and Harsnberger HR, page 253, Copyright Amirsys/Elsevier (2006). Reproduced with permission.

This dataset does not specifically address the issue of sentinel lymph node biopsy (SLNB) for head and neck cancers. The experience with SLNB is greatest for melanoma and breast cancer. While SLNB is a valid diagnostic technique to correctly predict the stage of regional nodes in head and neck cancer, it is not yet standard of care in most countries.<sup>10,11</sup> In general, the same principles of lymph node reporting as listed in this dataset can be applied to sentinel lymph nodes, except where additional information is required by local convention or study protocols. A negative sentinel lymph node supports the cN0 category, assuming a formal neck dissection has not been performed.<sup>1</sup>

↑ Back

## Note 2 – Specimens submitted (Core)

### Reason/Evidentiary Support

This section provides a listing of all lymph node groups and the associated non-lymphoid tissue received as part of a single surgery, and should correlate with the “operative procedure” designation. Accurate identification of the lymph node levels requires orientation of the specimen(s) by the surgeon, either with the use of sutures, a diagram, or by submitting each level in a separate specimen container.<sup>9</sup> In cases in which orientation is not possible, it is recommended to review the

specimen with the surgeon prior to gross submission of the lymph nodes. The designation of non-lymphoid tissue is non-specific, but more accurate naming of these tissues is desirable, when possible.

The lymph node groups may be received as multiple specimens from a single operative procedure. It is of benefit to combine the nodes from multiple specimens into one comprehensive report, rather than creating multiple sections for a single report. If a patient is known to have had a prior lymph node excisional biopsy (for example for diagnostic purposes), a comment to this effect is suggested. The result should be considered in the pN category assigned, with reference to the surgical pathology report number, when possible.

**↑ Back**

### **Note 3 – Histological tumour type (Core and Non-core)**

#### **Reason/Evidentiary Support**

Identification of the histological tumour type is crucial for several reasons, including: 1) confirmation that a metastasis is of the same type as the resected primary tumour 2) facilitating a clinical search in cases of unknown primary tumours 3) determining the correct T and N categories (see below) 4) guiding treatment, which varies by tumour type and lymph node status.<sup>12</sup>

Histological type and grade is typically determined from the histology of the primary site, but this is not possible for tumours of unknown origin. Tissue from a neck metastasis may be required for ancillary testing (e.g. p16 immunohistochemistry, in situ hybridization for high-risk human papilloma virus (HPV), in situ hybridization for Epstein Barr virus encoded RNA/EBER). For patients with occult primary squamous cell carcinoma in level II or III, the cN or pN categories are influenced by EBV and HPV status.<sup>13</sup> EBV-related and HPV-related carcinomas are given the N category that applies to nasopharyngeal and HPV-related oropharyngeal carcinomas, respectively.<sup>1</sup>

Note that verrucous carcinoma is not included in the above list of squamous cell carcinoma variants, as it has no capacity to metastasise to lymph nodes.

A classification for Neuroendocrine tumours is included, which applies to tumours of the hypopharynx, larynx, trachea and parapharyngeal space as per the latest World Health Organization (WHO) head and neck tumour classification. Neuroendocrine tumours elsewhere in the head and neck (for example the nasal cavity and salivary glands) tend to be high grade.<sup>14</sup> In most cases, an appropriate choice can be made from the list provided, but sites may choose to use the “other” category, as per local needs or convention.

Primary tumour site has been included at the end of this section for cases in which the neck dissection is received as a separate surgical specimen from the primary tumour. As this is not always the case, it is deemed a non-core item.

**↑ Back**

## Note 4 – Lymph node status (Core and Non-core)

### Reason/Evidentiary Support

Lymph node status may be presented in tabular form for ease of interpretation as follows:

Level and side	Number of nodes examined	Number of nodes positive	ENE minor or major	Number of nodes with ENE
II right	12	3	ENEmi	1
III right	14	2	ENEma	0
etc				

For cases in which an involved lymph node or tumour deposit straddles more than one lymph node level, it is recommended to include it in the level in which the bulk of the deposit is found, with an explanatory comment. In other cases, it may not be possible to precisely divide the neck dissection into individual levels and more than one level may need to be combined. If a neck dissection is received without any level designation, clarification from the surgeon involved is suggested. If this is not obtained, the data may be reported without further qualification, such as “right neck dissection, not further specified”.

“Soft tissue metastasis” refers to a deposit of tumour in connective tissue, without a microscopically identifiable residual lymph node. This may represent venous invasion, lymphatic invasion or, most likely, a totally replaced node or nodes. It does not refer to intralymphatic tumour emboli in adipose tissue surrounding the lymph nodes. In many cases, a soft tissue metastasis is the largest focus of tumour in the specimen. Rarely, very small soft tissue metastases (e.g. < 1 mm in greatest dimension) are identified that appear unlikely to be of nodal origin. Special stains and deeper levels may help to identify a vascular origin for these deposits, and the pathologist may use his/her discretion as to their designation as positive lymph nodes, perhaps with the use of a clarifying comment.

For tumour deposits in which there is residual lymph node tissue with widespread extranodal extension, a combined gross and microscopic estimate of the number of involved lymph nodes is suggested. Correlation with pre-surgical imaging studies may also be of benefit.

The largest metastatic focus may be an intranodal or a soft tissue metastasis. Determination of the size of the largest metastasis may be difficult in cases where multiple tumour deposits are identified in a single lymph node. Options including measuring the greatest dimension of the largest deposit, combining the sizes of the deposits to give an aggregate dimension, and measuring the greatest dimension “end-to-end” from a single slide, including discontinuous tumour deposits. The latter is recommended.

The size of the largest involved lymph node is the basis upon which clinicians determine N category and thereby the stage. Although there is some debate about whether the greatest dimension of the largest tumour deposit or that of the largest involved lymph node is the more relevant measurement, both are considered “core” items in this dataset. This is so as to provide the maximum amount of data that may be relevant for clinical decision-making. The greatest dimension

of the largest involved lymph node should be used to determine the pN category. In some cases, the largest node in a specimen may be a reactive node with no tumour. Therefore, the measurement must be of the largest node involved by metastatic tumour.

The prognostic significance of isolated tumour cells (foci <0.2 mm diameter or <200 cells) and micrometastases (foci 2 mm or less in greatest dimension) is currently unknown for head and neck cancers, and their designation is not required as part of the TNM staging.<sup>1,15,16</sup> Isolated tumour cells are uncommon in metastatic squamous cell carcinoma, but may occur in some less common primary tumours (e.g. Small cell carcinoma of salivary origin). As such, any-sized tumour deposit is considered a positive lymph node for staging purposes.<sup>1,17</sup> Specific identification of tumour deposits as isolated tumour cells or micrometastases and cytokeratin positive non-nucleated cells is not required as part of this dataset, but can be recorded as per local requirements for data collection. Mummified cells and keratin debris may be found and should not be regarded as viable metastatic disease.

Neck dissections may be performed as salvage surgery for a persistent neck mass following adjuvant radiation therapy. In this circumstance, only viable tumour - not necrotic keratinous debris or keratin granulomas - should be considered as a positive lymph node. Extra sampling of residual neck deposits may be required to evaluate these specimens. The prefix “yp” should be added to the TNM category.

### ***Extranodal extension***

Extranodal extension (ENE) refers to extension of tumour outside the capsule of a lymph node and into the perinodal soft tissue. It is also known as “extracapsular extension/spread”, but the term “extranodal extension” has been adopted in the 8th edition of the American Joint Committee on Cancer (AJCC) Staging Manual<sup>1</sup> and the Union for International Cancer Control (UICC)<sup>18</sup> and therefore is used here. ENE is a poor prognostic factor in cervical node positive head and neck carcinoma. In HPV-mediated oropharyngeal cancer, the exact clinical significance of ENE has yet to be established, and so it is considered a “non-core” item, with reporting up to local discretion.<sup>19-21</sup>

The presence of ENE in other head and neck cancers correlates with the risk of regional recurrence and outcome. It is an important factor for oncologists when considering treatment with postoperative radiotherapy or chemoradiotherapy.<sup>21,22</sup> ENE is subcategorised pathologically as microscopic (ENE<sub>mi</sub>, less than or equal to 2 mm in extent) and major (ENE<sub>ma</sub>, more than 2 mm in extent). These subcategories are not required for N categorisation but are recommended for data collection and future analysis.<sup>1</sup> The 5-point grading system for ENE (Lewis et al) is not validated and is not currently recommended.<sup>23</sup>

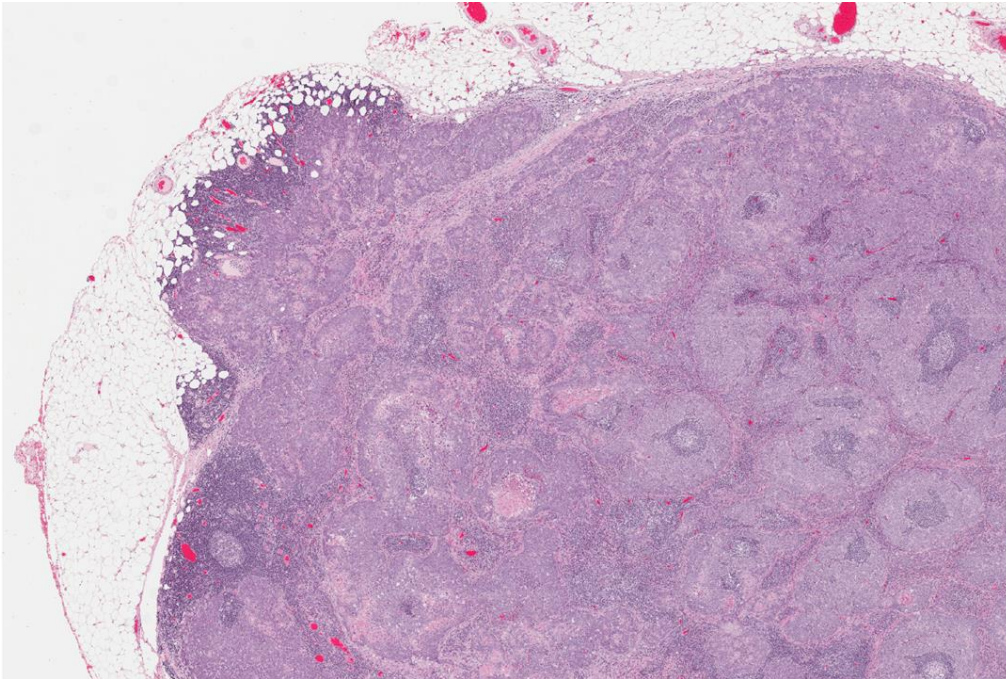
Interobserver variation in the determination of ENE may be minimised if the following guidance is used.

- 1) Lymph nodes, especially smaller nodes and those in the parotid area, may not have a complete capsule. The node hilum may merge with adipose tissue, or there may be a rim of lymphoid tissue external to the capsule. Generally speaking, a conservative approach is recommended. For instance, tumour within fat near the hilum of a node should be considered intranodal if benign lymphoid tissue is identified nearby. Tumour within

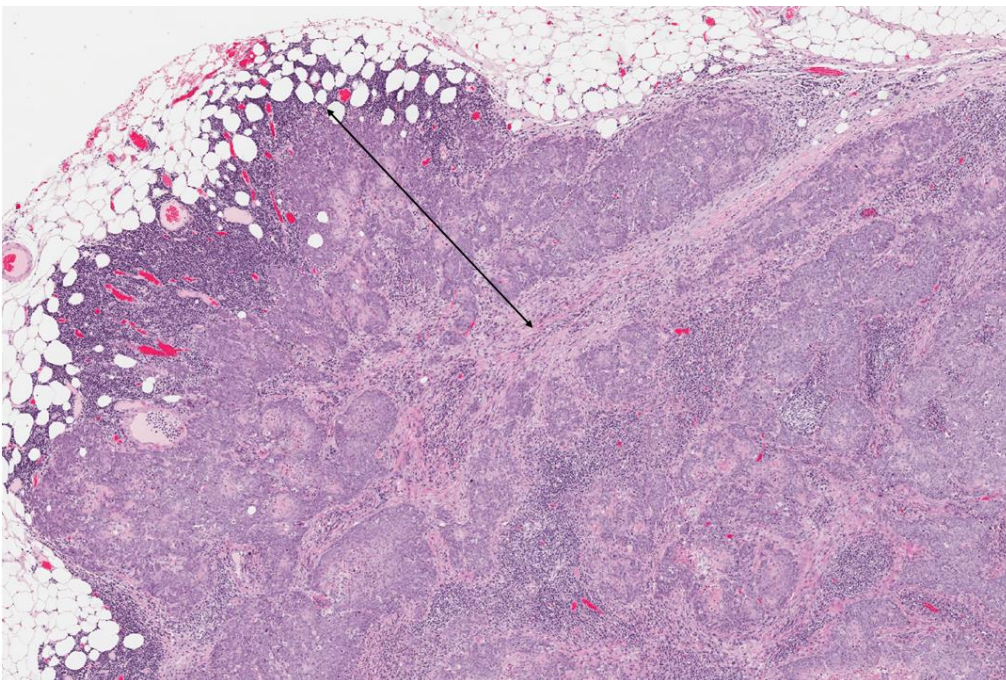
lymphatics near an involved lymph node should not be considered ENE. However, tumour extending beyond a clearly identifiable node capsule is extranodal, even if there is a surrounding lymphoid response. A stromal desmoplastic reaction is not necessarily required.<sup>1</sup>

- 2) Grossly “matted” lymph nodes. Grossly adherent lymph nodes may represent true macroscopic ENE or several closely-aggregated lymph nodes with thickened nodal capsules without microscopic evidence of ENE. Additional levels and sections are recommended to exclude ENE. The presence of matted nodes, their site, size and an estimated of the number involved, should be included in the gross description and may be mentioned in a comment. At least one study has shown that radiographically matted lymph nodes are a risk factor for distant metastases and decreased survival in oropharyngeal cancer.<sup>24</sup>
- 3) Lymphatic spread to lymph nodes versus direct extension from the primary tumour. Some tumours may extend directly into lymph nodes without intervening normal tissue. This is not uncommon in parotid tumours as there are multiple lymph nodes within the parotid parenchyma itself, but it also occurs with large oral and oropharyngeal primaries. Direct extension into lymph nodes is staged in the same manner as discontinuous metastases.<sup>1</sup> Determination of ENE should be based on any component of the capsule that is discontinuous with the primary tumour. A comment is recommended for clarity.
- 4) The lymph node capsule is often markedly thickened and altered by large metastases with obliteration of the subcapsular sinus. ENE is measured as the greatest extent of tumour spread perpendicular to the external aspect of the node capsule. The exact site of the latter is subjective, but may be estimated by examination of the remaining intact capsule and contour of the node (Figures 3 and 4). If the greatest extent of ENE is provided, the measurement can be rounded to the nearest millimetre or tenth of a millimetre, as per local convention (keeping in mind that if ENE is more than 2 mm, the measurement should not be rounded down to 2mm). More precise measurements are not warranted due to the subjectivity required and lack of known clinical relevance.





**Figure 3.** Low power image of a lymph node containing metastatic squamous cell carcinoma, with extranodal extension into perinodal adipose tissue (20x). Copyright Dr Martin Bullock. Reproduced with permission.



**Figure 4.** The extent of extranodal extension should be measured from external aspect of the capsule, or estimated site thereof, to the furthest point of tumour extension into the surrounding tissue. Copyright Dr Martin Bullock. Reproduced with permission.

↑ Back

## Note 5 – Margin status (Non-core)

### Reason/Evidentiary Support

Although neck dissections are not typically “margin” surgeries, tumours with extranodal extension must be excised with a clear margin. Margin positivity increases the risk of local recurrence and is an indication for additional radiotherapy to that site.<sup>25,26</sup> The site of margin positivity can be used by the radiation oncologist to direct treatment to the area of greatest risk.

↑ Back

## Note 6 – Ancillary studies (Non-core)

### Reason/Evidentiary Support

Ancillary testing for head and neck cancers most commonly refers to testing for high-risk HPV status in tumours of the oropharynx (typically using the surrogate marker of p16 immunohistochemistry or in situ hybridization) and EBV status in tumours of the nasopharynx (typically using in situ hybridization for EBV-encoded RNA or EBER). If ancillary testing is performed, it is recommended to include the type of testing, the result and interpretive guidelines if applicable.<sup>27</sup>

Oropharyngeal carcinoma is frequently human papillomavirus associated, with these tumours having improved survival versus HPV-negative cases.<sup>28</sup> Testing for p16 status in oropharyngeal squamous cell carcinoma is a requirement of the 8<sup>th</sup> edition of the AJCC TNM staging system<sup>1</sup> and UICC TNM staging system,<sup>18</sup> and separate staging categories have been devised for p16 – and p16+ tumours.<sup>1</sup>

p16 overexpression by immunohistochemical analysis is a reliable surrogate for high-risk HPV associated squamous cell carcinomas of the oropharynx (including types 16, 18 and others). Overexpression of p16 is defined as diffuse, strong nuclear and often cytoplasmic expression (2-3+ intensity) in ≥70% of tumour cells. P16 expression is not applicable as a surrogate for HPV in other head and neck subsites (i.e. oral cavity, sinonasal, hypopharynx skin, etc.) as HPV is infrequent and p16 expression is non-specific.

Strong p16 expression in non-HPV associated squamous cell carcinoma of non-oropharyngeal sites does occur with unclear significance. Thus while HPV specific testing would be ideal in the assessment of neck nodes in patients with unknown primary squamous cell carcinoma, the lack of testing availability and cost makes this impractical. p16 status should be reported in all oropharyngeal primary squamous cell carcinomas (testing either the primary site or from a metastatic focus). Additionally, metastatic squamous cell carcinomas to cervical upper– or mid–jugular chain neck lymph nodes (levels II and III) with an unknown primary site should also be tested for p16 over expression by immunohistochemistry.<sup>13</sup> In situ hybridisation for EBER is recommended for p16-negative, non-keratinizing or undifferentiated carcinomas, or if there is clinical suspicion of a nasopharyngeal primary.

↑ Back

## **Note 7 – Regional lymph node categorisation (Core)**

### **Reason/Evidentiary Support**

Note that (i) Midline nodes are considered ipsilateral nodes and (ii) ENE detected on histopathologic examination is designated as ENE<sub>mi</sub> (microscopic ENE ≤2 mm) or ENE<sub>ma</sub> (major ENE >2 mm). Both ENE<sub>mi</sub> and ENE<sub>ma</sub> qualify as ENE(+) for definition of pN.

Note that a designation of “U” or “L” may be used for any N category to indicate metastasis above the lower border of the cricoid (U) or below the lower border of the cricoid (L). Similarly, clinical and pathological ENE should be recorded as ENE(-) or ENE(+).

Information on lymph node status is crucial for the staging and treatment of head and neck malignancies. Assignment of a pN category is applicable for patients who are treated surgically with a cervical lymph node dissection, rather than single lymph node excisional biopsy, in which case the cN category is used.<sup>1</sup>

The above staging conforms to the 8<sup>th</sup> edition of the AJCC<sup>1</sup> and the UICC<sup>18</sup> cancer staging manuals. The new TNM system (AJCC Cancer Staging Manual 8<sup>th</sup> edition) became effective 1 January 2018, and introduced considerable changes to the staging of head and neck cancers.<sup>1</sup> These changes include, among others: 1) restructuring pharyngeal carcinoma by separating p16+ oropharyngeal carcinoma from p16- oropharyngeal and hypopharyngeal carcinoma, 2) inclusion of extranodal extension in the N category for p16- oropharyngeal, unknown primary, hypopharyngeal, oral cavity, larynx, skin, major salivary gland, nasal cavity and paranasal sinus cancers, 3) introduction of a separate category for occult primary tumours of the head and neck, with p16 and EBV tumour testing recommended in patients who remain an unknown primary squamous or undifferentiated carcinoma after clinical and radiographic evaluation 4) introduction of a separate chapter for cutaneous squamous cell carcinoma and other carcinomas, with the exception of Merkel cell carcinoma.

Nasopharyngeal carcinoma (NPC) commonly presents with bulky nodal neck disease, and a lymph node biopsy may occasionally precede biopsy of the primary site. However, nasopharyngeal carcinoma is not a surgically-treated disease<sup>29</sup> and therefore pathologists are rarely called upon to provide a pN category for NPC. A single positive lymph node biopsy would contribute to the cN categorisation.

### **Notes on submission of neck dissection specimens**

Correct submission of neck dissection specimens is required to obtain the most accurate and clinically useful information. Although there is no defined minimum number of lymph nodes required to utilize the term “neck dissection”, a selective neck dissection should normally contain 10 or more nodes and a comprehensive neck dissection should contain 15 or more nodes.<sup>14</sup> There are multiple good references available with grossing guidelines for neck dissection specimens. However, several points are emphasized here.



- 1) Inking of neck dissection specimens. Most neck dissections without lymph node involvement or with limited involvement (in which nodes are freely mobile and not matted or grossly involving non-lymphatic structures), will not need to be inked. However, as margin assessment is recommended, specimens with large tumour deposits, in which extranodal extension is considered likely, should be inked (at least surrounding the mass itself).
- 2) Grossly negative lymph nodes should be submitted in toto. Nodes 5 mm or more should be bisected or multisectioned to give tissue sections of 2-3 mm thickness. Grossly involved lymph node and soft tissue metastases need not be submitted in toto, but 1 section per cm in greatest dimension is a reasonable approach. Sections should focus on potential areas of extranodal extension, involvement of non-lymphatic structures and the margin.
- 3) When submitting lymph nodes that cannot be removed from the surrounding tissue (e.g. parotidectomy specimens), care should be taken not to “double count” nodes that may be bisected and present in two cassettes. Careful gross description, with an estimate of the number of nodes in each section, is recommended. In general, the gross estimate of the number of lymph nodes is most accurate, except when tissue originally designated as node is clearly another tissue (e.g. parathyroid gland).

↑ Back

## References

- 1 Amin MB, Edge S, Greene FL, Byrd DR, Brookland RK, Washington MK, Gershenwald JE, Compton CC, Hess KR, Sullivan DC, Jessup JM, Brierley JD, Gaspar LE, Schilsky RL, Balch CM, Winchester DP, Asare EA, Madera M, Gress DM, Meyer LR (eds) (2017). *AJCC Cancer Staging Manual 8th ed.* Springer, New York.
- 2 Ferlito A, Robbins KT, Shah JP, Medina JE, Silver CE, Al-Tamimi S, Fagan JJ, Paleri V, Takes RP, Bradford CR, Devaney KO, Stoeckli SJ, Weber RS, Bradley PJ, Suarez C, Leemans CR, Coskun HH, Pitman KT, Shaha AR, de Bree R, Hartl DM, Haigentz M, Jr., Rodrigo JP, Hamoir M, Khafif A, Langendijk JA, Owen RP, Sanabria A, Strojanc P, Vander Poorten V, Werner JA, Bien S, Woolgar JA, Zbaren P, Betka J, Folz BJ, Genden EM, Talmi YP, Strome M, Gonzalez Botas JH, Olofsson J, Kowalski LP, Holmes JD, Hisa Y and Rinaldo A (2011). Proposal for a rational classification of neck dissections. *Head Neck* 33(3):445-450.
- 3 Robbins KT, Medina JE, Wolfe GT, Levine PA, Sessions RB and Pruet CW (1991). Standardizing neck dissection terminology. Official report of the Academy's Committee for Head and Neck Surgery and Oncology. *Arch Otolaryngol Head Neck Surg* 117(6):601-605.
- 4 Spiessl B (1992). *TNM Atlas: Illustrated Guide to the TNM/pTNM Classification of Malignant Tumours (UICC International Union Against Cancer)*. Springer, Germany.

- 5 Gregoire V, Coche E, Cosnard G, Hamoir M and Reychler H (2000). Selection and delineation of lymph node target volumes in head and neck conformal radiotherapy. Proposal for standardizing terminology and procedure based on the surgical experience. *Radiother Oncol* 56(2):135-150.
- 6 Robbins KT, Clayman G, Levine PA, Medina J, Sessions R, Shaha A, Som P and Wolf GT (2002). Neck dissection classification update: revisions proposed by the American Head and Neck Society and the American Academy of Otolaryngology-Head and Neck Surgery. *Arch Otolaryngol Head Neck Surg* 128(7):751-758.
- 7 Robbins KT, Shaha AR, Medina JE, Califano JA, Wolf GT, Ferlito A, Som PM and Day TA (2008). Consensus statement on the classification and terminology of neck dissection. *Arch Otolaryngol Head Neck Surg* 134(5):536-538.
- 8 Medina JE (1989). A rational classification of neck dissections. *Otolaryngol Head Neck Surg* 100(3):169-176.
- 9 Paleri V, Urbano TG, Mehanna H, Repanos C, Lancaster J, Roques T, Patel M and Sen M (2016). Management of neck metastases in head and neck cancer: United Kingdom National Multidisciplinary Guidelines. *J Laryngol Otol* 130(S2):S161-s169.
- 10 Pitman KT, Ferlito A, Devaney KO, Shaha AR and Rinaldo A (2003). Sentinel lymph node biopsy in head and neck cancer. *Oral Oncol* 39(4):343-349.
- 11 Thompson CF, St John MA, Lawson G, Grogan T, Elashoff D and Mendelsohn AH (2013). Diagnostic value of sentinel lymph node biopsy in head and neck cancer: a meta-analysis. *Eur Arch Otorhinolaryngol* 270(7):2115-2122.
- 12 Edge SE, Byrd DR, Compton CC, Fritz AG, Greene FL and Trotti A (eds) (2010). *AJCC Cancer Staging Manual 7th ed.*, New York, NY.: Springer.
- 13 Lewis JS, Jr., Beadle B, Bishop JA, Chernock RD, Colasacco C, Lacchetti C, Moncur JT, Rocco JW, Schwartz MR, Seethala RR, Thomas NE, Westra WH and Faquin WC (2017). Human Papillomavirus Testing in Head and Neck Carcinomas: Guideline From the College of American Pathologists. *Arch Pathol Lab Med*.
- 14 El-Naggar AK, Chan JKC, Grandis JR, Takata T, Slotweg PJ Eds. (2017). *WHO Classification of Head and Neck Tumours (4th Edition)*. IARC, Lyon, France.
- 15 Ferlito A, Shaha AR and Rinaldo A (2001). Evolution in the philosophy of neck dissection. *Acta Otolaryngol* 121(8):963-966.

- 16 Devaney KO, Rinaldo A and Ferlito A (2007). Micrometastases in cervical lymph nodes from patients with squamous carcinoma of the head and neck: should they be actively sought? Maybe. *Am J Otolaryngol* 28(4):271-274.
- 17 Alkureishi LW, Burak Z, Alvarez JA, Ballinger J, Bilde A, Britten AJ, Calabrese L, Chiesa C, Chiti A, de Bree R, Gray HW, Hunter K, Kovacs AF, Lassmann M, Leemans CR, Mamelle G, McGurk M, Mortensen J, Poli T, Shoaib T, Sloan P, Sorensen JA, Stoeckli SJ, Thomsen JB, Trifiro G, Werner J and Ross GL (2009). Joint practice guidelines for radionuclide lymphoscintigraphy for sentinel node localization in oral/oropharyngeal squamous cell carcinoma. *Ann Surg Oncol* 16(11):3190-3210.
- 18 International Union against Cancer (UICC) (2016). *TNM Classification of Malignant Tumours (8<sup>th</sup> Edition)* [Incorporating corrections see [https://www.uicc.org/sites/main/files/atoms/files/UICC%208th%20Edition%20Errata\\_25May2018%20final.pdf](https://www.uicc.org/sites/main/files/atoms/files/UICC%208th%20Edition%20Errata_25May2018%20final.pdf)]. Brierley JD, Gospodarowicz MK, Wittekind C (eds). New York: Wiley-Blackwell.
- 19 Johnson JT, Barnes EL, Myers EN, Schramm VL, Jr., Borochoviz D and Sigler BA (1981). The extracapsular spread of tumors in cervical node metastasis. *Arch Otolaryngol* 107(12):725-729.
- 20 Ferlito A, Shaha AR and Rinaldo A (2002). The incidence of lymph node micrometastases in patients pathologically staged N0 in cancer of oral cavity and oropharynx. *Oral Oncol* 38(1):3-5.
- 21 Cooper JS, Pajak TF, Forastiere AA, Jacobs J, Campbell BH, Saxman SB, Kish JA, Kim HE, Cmelak AJ, Rotman M, Machtay M, Ensley JF, Chao KS, Schultz CJ, Lee N and Fu KK (2004). Postoperative concurrent radiotherapy and chemotherapy for high-risk squamous-cell carcinoma of the head and neck. *N Engl J Med* 350(19):1937-1944.
- 22 Bernier J, Dommene C, Ozsahin M, Matuszewska K, Lefebvre JL, Greiner RH, Giralt J, Maingon P, Rolland F, Bolla M, Cognetti F, Bourhis J, Kirkpatrick A and van Glabbeke M (2004). Postoperative irradiation with or without concomitant chemotherapy for locally advanced head and neck cancer. *N Engl J Med* 350(19):1945-1952.
- 23 Lewis JS, Jr., Carpenter DH, Thorstad WL, Zhang Q and Haughey BH (2011). Extracapsular extension is a poor predictor of disease recurrence in surgically treated oropharyngeal squamous cell carcinoma. *Mod Pathol* 24(11):1413-1420.
- 24 Spector ME, Chinn SB, Bellile E, Gallagher KK, Ibrahim M, Vainshtein J, Chanowski EJ, Walline HM, Moyer JS, Prince ME, Wolf GT, Bradford CR, McHugh JB, Carey T, Worden FP, Eisbruch A and Chepeha DB (2016). Matted nodes as a predictor of distant metastasis in advanced-stage III/IV oropharyngeal squamous cell carcinoma. *Head Neck* 38(2):184-190.

- 25 Leemans CR, Tiwari R, van der Waal I, Karim AB, Nauta JJ and Snow GB (1990). The efficacy of comprehensive neck dissection with or without postoperative radiotherapy in nodal metastases of squamous cell carcinoma of the upper respiratory and digestive tracts. *Laryngoscope* 100(11):1194-1198.
- 26 Smeele LE, Leemans CR, Langendijk JA, Tiwari R, Slotman BJ, van Der Waal I and Snow GB (2000). Positive surgical margins in neck dissection specimens in patients with head and neck squamous cell carcinoma and the effect of radiotherapy. *Head Neck* 22(6):559-563.
- 27 Singhi AD and Westra WH (2010). Comparison of human papillomavirus in situ hybridization and p16 immunohistochemistry in the detection of human papillomavirus-associated head and neck cancer based on a prospective clinical experience. *Cancer* 116(9):2166-2173.
- 28 Maxwell JH, Ferris RL, Gooding W, Cunningham D, Mehta V, Kim S, Myers EN, Johnson J and Chiosea S (2013). Extracapsular spread in head and neck carcinoma: impact of site and human papillomavirus status. *Cancer* 119(18):3302-3308.
- 29 Yoshizaki T, Ito M, Muro S, Wakisaka N, Kondo S and Endo K (2012). Current understanding and management of nasopharyngeal carcinoma. *Auris Nasus Larynx* 39(2):137-144.