

Nodal Excisions and Neck Dissection Specimens for Head and Neck Tumours Histopathology Reporting Guide

Family/Last name Date of birth Given name(s) Patient identifiers Date of request Accession/Laboratory number Elements in **black text** are **CORE**. Elements in **grey text** are **NON-CORE**. indicates multi-select values indicates single select values

SCOPE OF THIS DATASET

CLINICAL INFORMATION (Note 1)

- Information not provided
 Information provided (select all that apply)

 Previous therapy

- Surgery
 Chemotherapy
 Radiotherapy

 Targeted therapy, *specify if available* Immunotherapy, *specify if available* Clinical staging, *specify* Other clinical information, *specify***OPERATIVE PROCEDURE** (Note 2)

- Not specified
 Lymph node biopsy, *specify site*

 Selective neck dissection

- Supraomohyoid
 Lateral
 Posterolateral
 Central (anterior) compartment

 Comprehensive neck dissection

- Modified radical neck dissection
 Radical neck dissection
 Extended radical neck dissection

 Other, *specify***SPECIMEN(S) SUBMITTED** (select all that apply) (Note 3) Left Lymph nodes

- Not specified
 Submental (IA)
 Submandibular (IB)
 Upper jugular (II)
 Middle jugular (III)
 Other, *specify*
- Lower jugular (IV)
 Posterior triangle (V)
 Retropharyngeal
 Parotid/periparotid
 Perifacial

 Non-lymphoid tissue

- Nerve
 Muscle
 Vein
 Salivary gland
 Other, *specify*

 Right Lymph nodes

- Not specified
 Submental (IA)
 Submandibular (IB)
 Upper jugular (II)
 Middle jugular (III)
 Other, *specify*
- Lower jugular (IV)
 Posterior triangle (V)
 Retropharyngeal
 Parotid/periparotid
 Perifacial

 Non-lymphoid tissue

- Nerve
 Muscle
 Vein
 Salivary gland
 Other, *specify*

 Central compartment lymph nodes (VI +/- VII) Non-lymphoid tissue

- Thymus
 Parathyroid
 Other, *specify*

BLOCK IDENTIFICATION KEY (Note 4)

(List overleaf or separately with an indication of the nature and origin of all tissue blocks)

HISTOLOGICAL TUMOUR TYPE (select all that apply) (Note 5)

(Value list based on the World Health Organization Classification of Head and Neck Tumours (2024))

Primary tumour site

- Not specified/Not known
- Known (e.g., oral cavity, larynx), specify

Squamous cell carcinoma

- Squamous cell carcinoma, conventional
- HPV-associated oropharyngeal carcinoma
- Basaloid squamous cell carcinoma
- Papillary squamous cell carcinoma
- Spindle cell squamous carcinoma (sarcomatoid carcinoma)
- Adenosquamous cell carcinoma
- Acantholytic squamous cell carcinoma
- Undifferentiated (lymphoepithelial) carcinoma

Nasopharyngeal carcinoma

- Squamous cell carcinoma, keratinising
- Squamous cell carcinoma, non-keratinising (undifferentiated)
- Squamous cell carcinoma, basaloid
- Nasopharyngeal papillary adenocarcinoma

Neuroendocrine neoplasm, specify type

Mucosal melanoma, specify

Salivary gland carcinoma

- Mucoepidermoid carcinoma
- Adenoid cystic carcinoma
- Acinic cell carcinoma
- Secretory carcinoma
- Microsecretory adenocarcinoma
- Polymorphous adenocarcinoma
 - Classic
 - Cribriform
- Epithelial-myoeplithelial carcinoma
- Hyalinising clear cell carcinoma
- Basal cell adenocarcinoma
- Sebaceous adenocarcinoma
- Intraductal carcinoma
- Salivary duct carcinoma
- Myoepithelial carcinoma
- Carcinoma ex pleomorphic adenoma, specify type(s)

- Lymphoepithelial carcinoma
- Squamous cell carcinoma
- Oncocytic carcinoma
- Carcinosarcoma
- Adenocarcinoma, NOS

Other (e.g., primary adnexal skin cancers), specify

Comments

HISTOLOGICAL TUMOUR GRADE^a (Note 6)

(Not applicable to all tumours)

- Not applicable
- Grade 1, well differentiated, low grade
- Grade 2, moderately differentiated, intermediate grade
- Grade 3, poorly differentiated, high grade
- Undifferentiated
- High grade transformation

Grading system used, specify

- Cannot be assessed, specify

^a Grading of neuroendocrine tumours is non-core. Use only Grade 1, 2 and 3 for neuroendocrine tumours; neuroendocrine carcinomas are considered high grade by definition and are therefore not graded.

MARGIN STATUS (Note 7)

Involvement of perinodal surgical margin

- Not involved by carcinoma

Specify closest margin(s), if possible

- Involved by carcinoma (select all that apply)

- Left
- Right
- Central
- Laterality not specified

Lymph node level/compartments, specify

- Cannot be assessed, specify

See page 3 for LYMPH NODE STATUS (Note 8) and page 4 for SENTINEL LYMPH NODE BIOPSY (Note 9)

OTHER PATHOLOGY (Note 10)

ANCILLARY STUDIES (Note 11)

- Not performed
- Performed (select all that apply)

HPV testing,^b specify method and results

EBV testing,^c specify method and results

Other, record test(s), methodology and results

Representative blocks for ancillary studies, specify those blocks best representing tumour and/or normal tissue for further study

^b Core for metastases of squamous cell carcinoma to level II or III lymph nodes, with an unknown primary.

^c Core for carcinomas with a lymphoepithelial pattern.

LYMPH NODE STATUS (select all that apply) (Note 8)

Left sided lymph nodes

Node level	Number of nodes examined ^d	Number of nodes positive ^d	Extranodal extension (ENE) ^e o Not identified o ENEmi (≤2 mm) o ENEma (>2 mm)
Submental IA			
Submandibular IB			
Upper jugular II			
Middle jugular III			
Lower jugular IV			
Posterior triangle V			

^d Insert 'cannot be determined' when applicable. ^e Non-core element for HPV-associated oropharyngeal cancer and nasopharyngeal cancer.

Maximum dimension of largest lymph node metastasis

 mm

Maximum dimension of largest involved lymph node

 mm

Specify site (level)

Greatest extent of extranodal extension (ENE)

 mm

Specify site (level)

Soft tissue metastasis

- Not identified
 Present, specify site (level)

Non-lymphatic structures involved (select all that apply)

- Not identified
 Vessel
 Named vessel, specify
 Nerve
 Named nerve, specify
 Skeletal muscle
 Named skeletal muscle, specify
 Other, specify

Right sided lymph nodes

Node level	Number of nodes examined ^d	Number of nodes positive ^d	Extranodal extension (ENE) ^e o Not identified o ENEmi (≤2 mm) o ENEma (>2 mm)
Submental IA			
Submandibular IB			
Upper jugular II			
Middle jugular III			
Lower jugular IV			
Posterior triangle V			

^d Insert 'cannot be determined' when applicable. ^e Non-core element for HPV-associated oropharyngeal cancer and nasopharyngeal cancer.

Maximum dimension of largest lymph node metastasis

 mm

Maximum dimension of largest involved lymph node

 mm

Specify site (level)

Greatest extent of ENE

 mm

Specify site (level)

Soft tissue metastasis

- Not identified
 Present, specify site (level)

Non-lymphatic structures involved (select all that apply)

- Not identified
 Vessel
 Named vessel, specify
 Nerve
 Named nerve, specify
 Skeletal muscle
 Named skeletal muscle, specify
 Other, specify

LYMPH NODE STATUS (select all that apply) (Note 8) continued

Central compartment lymph nodes

Number of nodes examined^d

Number of nodes positive^d

ENE^e

Not identified

ENEmi (≤2 mm)

ENEMA (>2 mm)

Maximum dimension of largest lymph node metastasis mm

Maximum dimension of largest involved lymph node mm

Specify site (level)

Greatest extent of ENE mm

Specify site (level)

Soft tissue metastasis

Not identified

Present, *specify site (level)*

Non-lymphatic structures involved (select all that apply)

Not identified

Vessel

Named vessel, *specify*

Nerve

Named nerve, *specify*

Skeletal muscle

Named skeletal muscle, *specify*

Other, *specify*

^d Insert 'cannot be determined' when applicable.

^e Non-core element for HPV-associated oropharyngeal cancer and nasopharyngeal cancer.

SENTINEL LYMPH NODE BIOPSY (Note 9)

Side

Left Right

Specific site, if known

Number of nodes examined

Number of nodes positive

Status of positivity of largest metastatic deposit

Metastasis (>2 mm)

Micrometastasis (0.2-2 mm)

Isolated tumour cells (<0.2 mm or isolated cell clusters)

ENE

Not identified Present

Go back to page 2 for OTHER PATHOLOGY (Note 10) and ANCILLARY STUDIES (Note 11)

REGIONAL LYMPH NODE CATEGORISATION (Note 12) (UICC TNM 8th edition)^f

TNM Descriptors (only if applicable) (select all that apply)

- r - recurrent
- y - during or following multimodality therapy

Regional lymph nodes (pN)

Primary carcinomas of the lip and oral cavity, major salivary glands, nasal cavity and paranasal sinuses, p16 negative oropharynx (HPV-independent), hypopharynx, larynx, cutaneous head and neck carcinomas (with the exception of Merkel cell carcinoma) and unknown primary squamous cell carcinomas that are p16 and EBV-negative

- NX^g Regional lymph nodes cannot be assessed
- N0 No regional lymph node metastasis
- N1 Metastasis in a single ipsilateral lymph node, 3 cm or less in greatest dimension without ENE
- N2 Metastasis described as:
- N2a Metastasis in a single ipsilateral lymph node, 3 cm or less in greatest dimension with ENE or more than 3 cm but not more than 6 cm in greatest dimension without ENE
- N2b Metastasis in multiple ipsilateral nodes, none more than 6 cm in greatest dimension, without ENE
- N2c Metastasis in bilateral or contralateral lymph nodes, none more than 6 cm in greatest dimension, without ENE
- N3a Metastasis in a lymph node more than 6 cm in greatest dimension without ENE
- N3b Metastasis in a lymph node more than 3 cm in greatest dimension with ENE, or multiple ipsilateral, or any contralateral or bilateral node(s) with ENE

HPV-MEDIATED (p16 POSITIVE) OROPHARYNGEAL (HPV-ASSOCIATED)

- NX^g Regional lymph nodes cannot be assessed
- N0 No regional lymph node metastasis
- N1 Metastasis in 1 to 4 lymph node(s)
- N2 Metastasis in 5 or more lymph node(s)

NASOPHARYNGEAL CARCINOMA

- NX^g Regional lymph nodes cannot be assessed
- N0 No regional lymph node metastasis
- N1 Unilateral metastasis in cervical lymph node(s), and/or unilateral or bilateral metastasis in retropharyngeal lymph nodes, 6 cm or less in greatest dimension, above the caudal border of cricoid cartilage
- N2 Bilateral metastasis in cervical lymph node(s), 6 cm or less in greatest dimension, above the caudal border of cricoid cartilage
- N3 Metastasis in cervical lymph node(s) greater than 6 cm in dimension and/or extension below the caudal border of the cricoid cartilage

MUCOSAL MELANOMA

- NX^g Regional lymph nodes cannot be assessed
- N0 No regional lymph node metastasis
- N1 Regional lymph node metastasis present

^f Reproduced with permission. Source: UICC TNM Classification of Malignant Tumours, 8th Edition, eds by James D. Brierley, Mary K. Gospodarowicz, Christian Wittekind. 2016, Publisher Wiley (incorporating any errata published up until 12th July 2024).

^g NX should be used only if absolutely necessary.

Definitions

CORE elements

CORE elements are those which are essential for the clinical management, staging or prognosis of the cancer. These elements will either have evidentiary support at Level III-2 or above (based on prognostic factors in the National Health and Medical Research Council (NHMRC) levels of evidence¹). In rare circumstances, where level III-2 evidence is not available an element may be made a CORE element where there is unanimous agreement by the Dataset Authoring Committee (DAC). An appropriate staging system e.g., Pathological TNM staging would normally be included as a CORE element.

Molecular and immunohistochemical testing is a growing feature of cancer reporting. However, in many parts of the world this type of testing is limited by the available resources. In order to encourage the global adoption of ancillary tests for patient benefit, International Collaboration on Cancer Reporting (ICCR) includes the most relevant ancillary testing in ICCR Datasets as CORE elements, especially when they are necessary for the diagnosis. Where the technical capability does not yet exist, laboratories may consider temporarily using these data elements as NON-CORE items.

The summation of all CORE elements is considered to be the minimum reporting standard for a specific cancer.

NON-CORE elements

NON-CORE elements are those which are unanimously agreed should be included in the dataset but are not supported by level III-2 evidence. These elements may be clinically important and recommended as good practice but are not yet validated or regularly used in patient management.

Key information other than that which is essential for clinical management, staging or prognosis of the cancer such as macroscopic observations and interpretation, which are fundamental to the histological diagnosis and conclusion e.g., macroscopic tumour details, may be included as either core or non-core elements by consensus of DAC.

 [Back](#)

Scope

The dataset has been developed for the reporting of lymph node resections from patients with primary carcinomas and mucosal melanomas of the head and neck. This excludes nodal resections for lymphoma and sarcomas. It is not intended for use in reporting lymph node core biopsy or fine needle aspirations. Carcinomas covered by the dataset include sinonasal tract, nasopharynx, oral cavity, oropharynx, hypopharynx, larynx and trachea, salivary glands (major and minor), and ear and temporal bone. Neuroendocrine tumours (grade 1, 2 and 3) and neuroendocrine carcinomas are also included in this dataset, along with mucosal melanoma and cutaneous carcinomas (except Merkel cell carcinoma). For resections of recurrent disease, the reporting guide may be used pragmatically although some data elements may be not applicable nor assessable.

Neuroendocrine neoplasms, as newly defined,² include paraganglioma/pheochromocytoma, neuroendocrine tumours, and neuroendocrine carcinomas. Neuroendocrine tumours are separated into grades (1, 2, and 3) based on mitotic rate and Ki-67 proliferation indices, but these criteria are not yet fully developed for each of the anatomic sites in the head and neck. At present, the general cutoffs are: grade 1: <2 mitoses/2 millimetre (mm)² and <2% Ki-67 proliferation index; grade 2: ≥2-10 mitoses/2 mm² and 2-20% Ki-67 proliferation index; grade 3: ≥11 mitoses/2 mm² and >20% Ki-67 proliferation index.^{3,4} Further, neuroendocrine carcinomas are separated into small cell and large cell categories, showing tumour necrosis, >10 mitoses/2 mm² and >20% Ki-67 proliferation index,^{3,5-7} with universal Rb1 loss and common p53 overexpression.⁸ At present, the site, tumour category, and grade should be reported, with additional advances in this field incorporated when validated further. Salivary gland neoplasms in minor sites are sufficiently uncommon as to make prognostication challenging. As such, reporting of the histologic tumour type and grade based on the ICCR Carcinomas of the major salivary glands dataset is recommended,⁹ while still reporting the additional findings based on anatomic centring of the tumour.

This dataset is to be used in conjunction with other ICCR datasets in the Head and Neck Series.¹⁰ Lymph node excisional biopsies or neck dissections may precede, accompany, or follow the biopsy or resection of a primary tumour. Concurrent reporting of the lymph node and primary tumour dataset elements – ideally in the same report – is preferable, as it provides clinicians with the most comprehensive information for tumour stage categorisation.

Pathologists should consider the impact of prior intervention (e.g., prior diagnostic lymph node excisional biopsy in a patient with a neck mass) on the pN category, and make reference to the previous surgical pathology specimen, if available. Similarly, neck dissections may be performed as ‘salvage surgery’ following radiation and/or chemotherapy. These adjuvant or neoadjuvant interventions may affect pN category by reducing the bulk of tumour, or perhaps eliminating it altogether.

The second edition of this dataset includes changes to align the dataset with the World Health Organization (WHO) Classification of Head and Neck Tumours, 5th edition, 2024.²

A list of changes in this dataset edition can be accessed [here](#).

The authors of this dataset can be accessed [here](#).

↑ Back

Note 1 – Clinical information (Core and Non-core)

In general adjuvant or neoadjuvant therapy are not employed before sampling of lymph nodes, but as this field develops, it is recommended to include any previous surgery, chemotherapy, radiotherapy, targeted or immunotherapy which may have been used to manage the patient prior to the biopsy/dissection.

↑ Back

Note 2 – Operative procedure (Non-core)

Accurate designation of the operative procedure requires appropriate information from the head and neck surgeon, ideally with specimen orientation. A single operation may encompass more than one of the above-designated procedures, and the terminology may vary by institution. Some experts have proposed

eliminating the above terminology, in favour of a more simplistic designation that includes the lymph node levels received and a listing of non-lymphatic structures that accompany them.¹¹ In some cases, it is not possible to specify or be certain of the operative procedure, and thus this element is considered non-core.

Neck dissection terminology

The best known classification of lymph node groups in the neck is the so-called Robbins' classification, originally proposed by the American Academy of Otolaryngology – Head and Neck Surgery,¹² in which the lymph node basins of the neck are divided into levels I to VI, as per the anatomical boundaries described further below and illustrated in Figure 1. This classification only includes lymph nodes commonly removed during neck dissection procedures, and therefore it does not include all the head and neck node groups such as the facial nodes. Level VII (the superior mediastinal lymph node compartment) is included in the illustration for completeness, but except for thyroid cancer, it is rarely involved by head and neck cancer. Additional node groups are described in the TNM Atlas terminology, which divides the nodes into 12 groups, including retropharyngeal, parotid, buccal, retroauricular and occipital nodes (see Figure 2).¹³ Further subdivisions of several node levels, based on specific anatomical landmarks, have clinical significance because they tend to be involved preferentially by tumours of specific primary sites. For instance, level IIb is more commonly involved by primary tumours of the oropharynx or nasopharynx, than by primaries of the oral cavity, hypopharynx or larynx.¹⁴⁻¹⁷

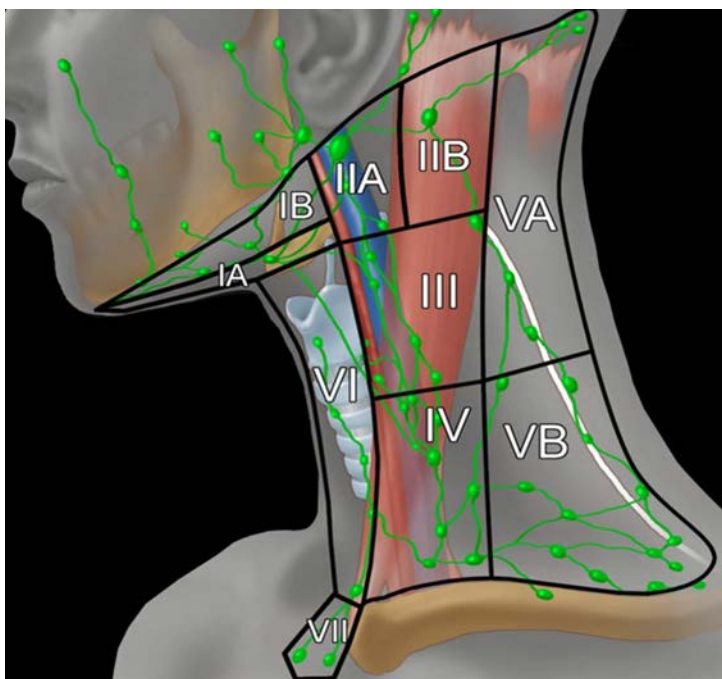


Figure 1: Illustration of the major neck lymph node levels, with anatomical boundaries, that are resected during neck dissections. This figure was published in *Imaging Anatomy: Brain, Head and Neck, Spine. Diagnostic and Surgical Imaging Anatomy, Cervical Lymph nodes*, 2006, Gordon H and Harsnberger HR, page 253, Copyright Amirsys/Elsevier (2006). Reproduced with permission.

The boundaries of the lymph node groups found within the levels and sublevels of the neck are as follows:^{18,19}

Submental (sublevel IA)

Lymph nodes within the triangular boundary of the anterior belly of the digastric muscles and the hyoid bone. These nodes are at greatest risk for harbouring metastases from cancers arising from the floor of mouth, anterior oral tongue, anterior mandibular alveolar ridge, and lower lip.

Submandibular (sublevel IB)

Lymph nodes within the boundaries of the anterior belly of the digastric muscle, the stylohyoid muscle, and the body of the mandible. It includes the pre glandular and the post glandular nodes and the prevascular and postvascular nodes. The submandibular gland is included in the specimen when the lymph nodes within the triangle are removed. These nodes are at greatest risk for harbouring metastases from cancers arising from the oral cavity, anterior nasal cavity, soft tissue structures of the midface, and submandibular gland.

Upper jugular (includes sublevels IIA and IIB)

Lymph nodes located around the upper third of the internal jugular vein and adjacent spinal accessory nerve extending from the level of the skull base (above) to the level of the inferior border of the hyoid bone (below). The anterior (medial) boundary is the stylohyoid muscle (the radiologic correlate is the vertical plane defined by the posterior surface of the submandibular gland) and the posterior (lateral) boundary is the posterior border of the sternocleidomastoid muscle. Sublevel IIA nodes are located anterior (medial) to the vertical plane defined by the spinal accessory nerve. Sublevel IIB nodes are located posterior (lateral) to the vertical plane defined by the spinal accessory nerve. Sublevel IIB may be submitted and/or reported as a separate specimen, depending on local practice. The upper jugular nodes are at greatest risk for harbouring metastases from cancers arising from the oral cavity, nasal cavity, nasopharynx, oropharynx, hypopharynx, larynx, and parotid gland.

Middle jugular (level III)

Lymph nodes located around the middle third of the internal jugular vein extending from the inferior border of the hyoid bone (above) to the inferior border of the cricoid cartilage (below). The anterior (medial) boundary is the lateral border of the sternohyoid muscle, and the posterior (lateral) boundary is the posterior border of the sternocleidomastoid muscle. These nodes are at greatest risk for harbouring metastases from cancers arising from the oral cavity, nasopharynx, oropharynx, hypopharynx, and larynx.

Lower jugular (level IV)

Lymph nodes located around the lower third of the internal jugular vein extending from the inferior border of the cricoid cartilage (above) to the clavicle below. The anterior (medial) boundary is the lateral border of the sternohyoid muscle and the posterior (lateral) boundary is the posterior border of the sternocleidomastoid muscle. These nodes are at greatest risk for harbouring metastases from cancers arising from the hypopharynx, thyroid, cervical oesophagus, and larynx.

Posterior triangle group (includes sub levels VA and VB)

The group is composed predominantly of the lymph nodes located along the lower half of the spinal accessory nerve and the transverse cervical artery. The supraclavicular nodes are also included in posterior triangle group. The superior boundary is the apex formed by convergence of the sternocleidomastoid and trapezius muscles, the inferior boundary is the clavicle, the anterior (medial) boundary is the posterior border of the sternocleidomastoid muscle, and the posterior (lateral) boundary is the anterior border of the trapezius muscle. Sublevel VA is separated from sublevel VB by a horizontal plane marking the inferior border of the anterior cricoid arch. Thus, sublevel VA includes the spinal accessory nodes, whereas sublevel VB includes the nodes following the transverse cervical vessels and the supraclavicular nodes with the exception of the Virchow node, which is located in level IV. The posterior triangle nodes are at greatest risk for harbouring metastases from cancers arising from the nasopharynx, oropharynx, and cutaneous structures of the posterior scalp and neck.

Anterior compartment group (level VI)

Lymph nodes in this compartment include the pretracheal and paratracheal nodes, precricoid (Delphian) node, and the perithyroidal nodes including the lymph nodes along the recurrent laryngeal nerves. The superior boundary is the hyoid bone, the inferior boundary is the suprasternal notch, and the lateral boundaries are the common carotid arteries. These nodes are at greatest risk for harbouring metastases from cancers arising from the thyroid gland, glottic and subglottic larynx, apex of the piriform sinus, and cervical oesophagus.

Superior mediastinal (level VII)

Lymph nodes in this group include pretracheal, paratracheal and oesophageal groove lymph nodes, extending from the level of suprasternal notch cephalad and up to the innominate artery caudad. These nodes are at greatest risk of involvement by thyroid cancer and cancer of the oesophagus.

The most widely used classification of neck dissection procedures is based on the original system proposed by the Committee for Head and Neck Surgery and Oncology of the American Academy of Otolaryngology-Head and Neck Surgery in 1991.¹² This was revised in 2002²⁰ and updated in 2008.²¹ The classification includes four basic procedures: *radical* neck dissection, *modified radical* neck dissection, *extended* neck dissection, and *selective* neck dissection. The term *comprehensive* neck dissection refers to any neck dissection in which all nodes in levels I to V are removed, and therefore it includes *radical*, *modified radical* and *extended* neck dissections, as explained below.²²

A *radical* neck dissection involves removal of levels I-V, as well the sternocleidomastoid muscle, spinal accessory nerve and internal jugular vein. A *modified radical* neck dissection spares at least one of the above non-lymphatic structures. An *extended* neck dissection involves removal of additional lymph nodes or non-lymphatic structures, beyond those removed as part of a radical neck dissection.

A *selective* neck dissection is a more limited procedure, in which one or more of the level I to V lymph node groups are spared, typically for malignancies of specific locations and with no or limited clinical evidence of lymph node involvement (N0 or N1).²³ *Supraomohyoid* neck dissection refers to removal of levels I to III, and is commonly performed for tumours of the oral cavity. *Lateral* neck dissection refers to removal of levels II to IV, performed for tumours of the larynx, oropharynx and hypopharynx. *Posterolateral* neck dissection refers to removal of levels II to V, for example, for skin malignancies of the posterior scalp or upper, posterolateral neck.

Central or anterior compartment neck dissection removes level VI nodes (pretracheal, paratracheal, precricoid/Delphian and perithyroidal nodes) and is most commonly performed during surgery for thyroid carcinoma. Level VI lymph nodes are uncommonly received as neck dissections for head and neck skin or mucosal malignancies, but these nodes may be involved by primary cancers of the larynx or hypopharynx. Superior mediastinal nodes (level VII) may also be removed in central neck dissections, particularly for thyroid cancer.

A conspicuous member of the 'other' category is the parotid lymph node basin, which is usually received as part of a parotidectomy specimen for primary salivary gland tumours or for metastatic skin cancers of the face and scalp (see Figure 2).

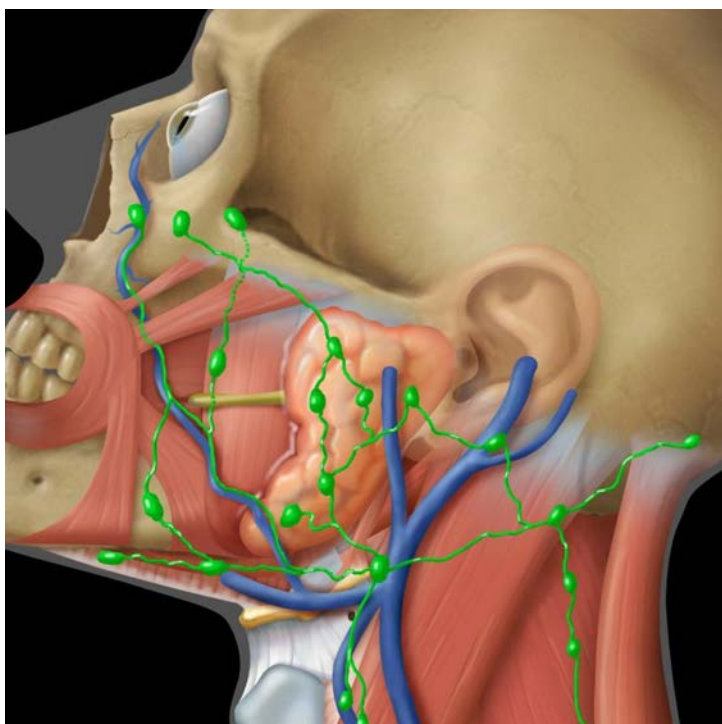


Figure 2: Head and neck lymph node groups of the facial area, including the parotid, bucco-facial, retroauricular and occipital groups. These nodes are more commonly involved with tumours of the head and neck skin and parotid gland. This figure was published in *Imaging Anatomy: Brain, Head and Neck, Spine. Diagnostic and Surgical Imaging Anatomy, Cervical Lymph nodes*, 2006, Gordon H and Harsnberger HR, page 253, Copyright Amirsys/Elsevier (2006). Reproduced with permission.

↑ Back

Note 3 – Specimen(s) submitted (Core)

This section provides a listing of all lymph node groups and the associated non-lymphoid tissue received as part of a single surgery and should correlate with the 'operative procedure' designation. Accurate identification of the lymph node levels requires orientation of the specimen(s) by the surgeon, either with the use of sutures, a diagram, or by submitting each level in a separate specimen container.²³ In cases in which orientation is not possible, it is recommended to review the specimen with the surgeon prior to gross submission of the lymph nodes. The designation of non-lymphoid tissue is non-specific, but more accurate naming of these tissues is desirable, when possible.

The lymph node groups may be received as multiple specimens from a single operative procedure. It is of benefit to combine the node findings from multiple specimens into one comprehensive report. If a patient is known to have had a prior lymph node excisional biopsy (for example, for diagnostic purposes), a comment to this effect is suggested. The result should be considered in the pN category assigned, with reference to the surgical pathology report number, when possible.

↑ Back

Note 4 – Block identification key (Non-core)

The origin/designation of all tissue blocks should be recorded. This information should ideally be documented in the final pathology report and is particularly important when further internal or external review arises. The reviewer needs to have unequivocal description of the origin of each block in order to provide an informed specialist opinion. If this information is not included in the final pathology report, it should be available on the laboratory computer system and relayed to the reviewing pathologist. It is highly encouraged to have a digital image (photograph) of the specimen and record of the key of the tumour blocks.

Recording the origin/designation of tissue blocks also facilitates retrieval of blocks for further immunohistochemical or molecular analysis, research studies, or clinical trials.

 **Back**

Note 5 – Histological tumour type (Core and Non-core)

Primary tumour site is a core item as it is relevant to both treatment and prognosis. Identification of the histological tumour type is crucial for several reasons, including: 1) confirmation that a metastasis is of the same type as the resected primary tumour; 2) facilitating a clinical search in cases of unknown primary tumours; 3) determining the correct T and N categories; and 4) guiding treatment, which varies by tumour type and lymph node status.^{18,19}

Histological type is typically determined from the histology at the primary site, but this is not possible for tumours of unknown origin. Tissue from a neck metastasis may be required for ancillary testing (e.g., p16 immunohistochemistry, in situ hybridisation for high risk human papillomavirus (HPV), in situ hybridisation for Epstein Barr virus (EBV) encoded RNA/EBER). For patients with occult primary SSC in level II or III, the cN or pN categories are influenced by EBV and HPV status.²⁴ EBV-associated and HPV-associated carcinomas are given the N category that applies to nasopharyngeal and HPV-associated oropharyngeal carcinomas, respectively.^{18,19}

Verrucous carcinoma and carcinoma cuniculatum are not included in the above list of squamous cell carcinoma (SSC) subtypes, as they are not considered SCC subtypes in the WHO Classification and they have no capacity to metastasise to lymph nodes.

The classification system for Neuroendocrine neoplasms (subdivided into tumours and carcinomas) is included, as per the most recent edition of the WHO Classification of Head and Neck Tumours, 5th edition, 2024.²

 **Back**

Note 6 – Histological tumour grade (Core)

When possible, tumour grade should be determined from the primary tumour, not from a metastasis. Some tumours are high grade or undifferentiated by definition (e.g., non-keratinising nasopharyngeal carcinoma (NPC)), while others do not require grading because behaviour is defined by pathogenesis and is not apparently influenced by morphology (e.g., HPV-associated oropharyngeal carcinoma). For most malignancies, the WHO grading system is most practical and widely utilised. Still, several grading systems are

available for many tumours (e.g., mucoepidermoid carcinoma), with differing merits, and as such, recording which system has been applied is more clinically meaningfully (use 'specify' to state the system used).

↑ Back

Note 7 – Margin status (Core)

Margin status of the neck dissection is typically only relevant when extranodal extension (ENE) is present, as nodes without ENE are presumed to be removed in toto. Clinical correlation and orientation by the surgeon is required if the neck dissection is received as multiple specimens, so as to avoid a misinterpretation of the location of the true surgical margin.

Margin positivity increases the risk of local recurrence and is an indication for additional radiotherapy to that site.²⁵⁻²⁷ The site of margin positivity can be used by the radiation oncologist to direct treatment to the area of greatest risk.

↑ Back

Note 8 – Lymph node status (Core and Non-core)

Lymph node status may be presented in tabular form for ease of interpretation, as illustrated in the reporting guide.

For cases in which an involved lymph node or tumour deposit straddles more than one lymph node level, it is recommended to include it in the level in which the bulk of the deposit is found, with an explanatory comment. In other cases, it may not be possible to precisely divide the neck dissection into individual levels and more than one level may need to be combined. If a neck dissection is received without any level designation, clarification from the surgeon is suggested. If this is not obtained, the data may be reported without further qualification, such as 'right neck dissection, not further specified'.

'Soft tissue metastasis' refers to a deposit of tumour in connective tissue, without a microscopically identifiable residual lymph node. It does not refer to intralymphatic tumour emboli in adipose tissue surrounding the lymph nodes. Soft tissue metastasis has been found to negatively impact survival in patients who are otherwise node-negative or in those with positive nodes lacking ENE.^{28,29} In many cases, a soft tissue metastasis is the largest focus of tumour in the specimen. This is presumed to represent one or more completely replaced lymph nodes and should be recorded as such. Less commonly, small soft tissue metastases (e.g., <1 mm in greatest dimension) are identified that do not appear to be of nodal origin. Special stains and deeper levels may help to identify a vascular origin for these deposits. The pathologist must use his/her discretion as to their designation as positive lymph nodes, with the use of a clarifying comment.

For tumour deposits in which there is residual lymph node tissue with widespread ENE, a combined gross and microscopic estimate of the number of involved lymph nodes is suggested. Correlation with pre-surgical imaging studies may be of benefit.

The largest metastatic focus may be an intranodal or a soft tissue metastasis. Often, the maximum dimension of the largest metastatic tumour deposit is determined at gross examination of the specimen. Determination of the greatest dimension of a metastasis may be difficult in cases where multiple

microscopic intranodal deposits are identified. Options including measuring the greatest dimension of the largest microscopic deposit, combining the sizes of the deposits to give an aggregate dimension, and measuring the greatest dimension 'end-to-end' from a single slide, including discontinuous tumour deposits. The latter is recommended by the authoring committee.

The maximum dimension of the largest involved lymph node may not be the same as the maximum dimension of the largest metastatic deposit. For instance, this may be due to the presence of an enlarged reactive lymph node in the tumour basin with a microscopic tumour deposit. Both measurements are considered 'core' items in this dataset so as to avoid confusion, to facilitate correlation with imaging studies and to provide the maximum amount of data that may be relevant for clinical decision-making. The greatest dimension of the largest tumour deposit should be used to determine the pN category. In occasional cases, the largest lymph node in the specimen may not even contain tumour. The pathologist may elect to make a comment to this effect. However, it is not considered a necessary reporting element.

The prognostic significance of isolated tumour cells (ITC) (foci <0.2 mm diameter or <200 cells) and micrometastases (foci 2 mm or less in greatest dimension) is currently unknown for head and neck cancers, and their designation is not required as part of the TNM staging.^{18,19,30,31} ITCs are uncommon in metastatic SCC, but may occur in some less common primary tumours (e.g., small cell carcinoma of salivary origin). As such, any sized tumour deposit is considered a positive lymph node for staging purposes.^{18,19,32} Specific identification of tumour deposits as ITCs or micrometastases is not required as part of this dataset, but can be recorded as per local requirements for data collection, such as in sentinel node dissections. Mummified cells and keratin debris may be found; it should not be regarded as viable metastatic disease and should be considered pN0 for categorisation purposes.

Neck dissections may be performed as salvage surgery for a persistent neck mass following adjuvant radiation therapy. In this circumstance, only viable tumour – not necrotic keratinous debris or keratin granulomas – should be considered as a positive lymph node. Extra sampling of residual neck deposits may be required to evaluate these specimens. The prefix 'yp' should be added to the TNM category. The presence and number of necrotic lymph nodes should be added under **NOTE 9 – OTHER PATHOLOGY**.

Non-lymphatic structures involved is a core item referring to the involvement of **named** tissues (such as the spinal accessory nerve, internal jugular vein or sternocleidomastoid muscle) that are identified either by virtue of the specimen designation or in consultation with the surgeon. Clinical or imaging involvement of some extranodal tissues may imply the need for more aggressive neck dissection, and pathological involvement should be documented in the final report.³³

Emerging evidence suggests that lymph node ratio (the ratio of positive nodes over total number of nodes resected) may be an independent prognostic indicator of survival in metastatic SSCs of the head and neck.³⁴⁻³⁶ As yet, insufficient evidence has been gathered to include this as a reporting guide component.

Extranodal extension

Extranodal extension (ENE) refers to extension of tumour outside the capsule of a lymph node and into the perinodal soft tissue. This is the preferred terminology to 'extracapsular extension/spread'. ENE is an adverse prognostic factor for locoregional relapse and survival in cervical node positive head and neck SSCs.³⁷ The significance of ENE in HPV-associated oropharyngeal carcinoma has been less certain,¹⁹⁻²¹ however some evidence confirms the adverse effect on survival in these carcinomas as well.^{38,39}

The presence of ENE is an important factor for oncologists when considering treatment with postoperative radiotherapy and the addition of chemotherapy.³⁸⁻⁴¹

Extranodal extension (ENE) is subcategorised pathologically as microscopic (ENE_{mi} , less than or equal to 2 mm in extent) or major (ENE_{ma} , more than 2 mm in extent). These subcategories are not required for pN categorisation but are core items as they can impact treatment decisions,³⁷ and are relevant for data collection and future analysis. The more precise measurement of greatest extent of ENE in millimetres is a non-core item, as the reproducibility of this measurement is questionable. Certainly, an attempt to be more precise than tenths of a millimetre is not advised.

Interobserver variation in the determination of ENE may be minimised if the following guidance is used:

1. Lymph nodes, especially smaller nodes and those in the parotid area, may not have a complete capsule. The node hilum may merge with adipose tissue, or there may be a rim of lymphoid tissue external to the capsule. Generally speaking, a conservative approach is recommended. For instance, tumour within fat near the hilum of a node should be considered intranodal if benign lymphoid tissue is identified nearby. Tumour within lymphatics near an involved lymph node should not be considered ENE. However, tumour extending beyond a clearly identifiable node capsule is extranodal, even if there is a surrounding lymphoid response. A stromal desmoplastic reaction is not necessarily required.
2. Grossly 'matted' lymph nodes. Grossly adherent lymph nodes may represent true macroscopic ENE or several closely aggregated lymph nodes with thickened nodal capsules without microscopic evidence of ENE. Additional levels and sections are recommended to exclude ENE. The presence of matted nodes, their site, size and an estimated of the number involved, should be included in the gross description and may be mentioned in a comment. One study has found that radiographically matted lymph nodes are a risk factor for distant metastases and decreased survival in oropharyngeal cancer.⁴²
3. Lymphatic spread to lymph nodes versus direct extension from the primary tumour. Some tumours may extend directly into adjacent lymph nodes without intervening normal tissue. This is common in parotid tumours as there are multiple lymph nodes within the parotid parenchyma itself. This finding is not considered nodal metastatic disease for the purposes of staging, and the concept of 'ENE' will not apply. Rare instances of direct extension into a lymph node from a mucosal site – for example, from a large floor of mouth primary to a level I node – is more controversial and potentially more difficult to evaluate. The general rule of choosing the lower stage in equivocal circumstances should apply, but a clarifying comment and/or discussion with the treating physicians is suggested.
4. The lymph node capsule is often markedly thickened and altered by large metastases with obliteration of the subcapsular sinus. ENE is measured as the greatest extent of tumour spread perpendicular to the external aspect of the node capsule. The exact site of the latter is subjective but may be estimated by examination of the remaining intact capsule and contour of the node (Figures 3 and 4).

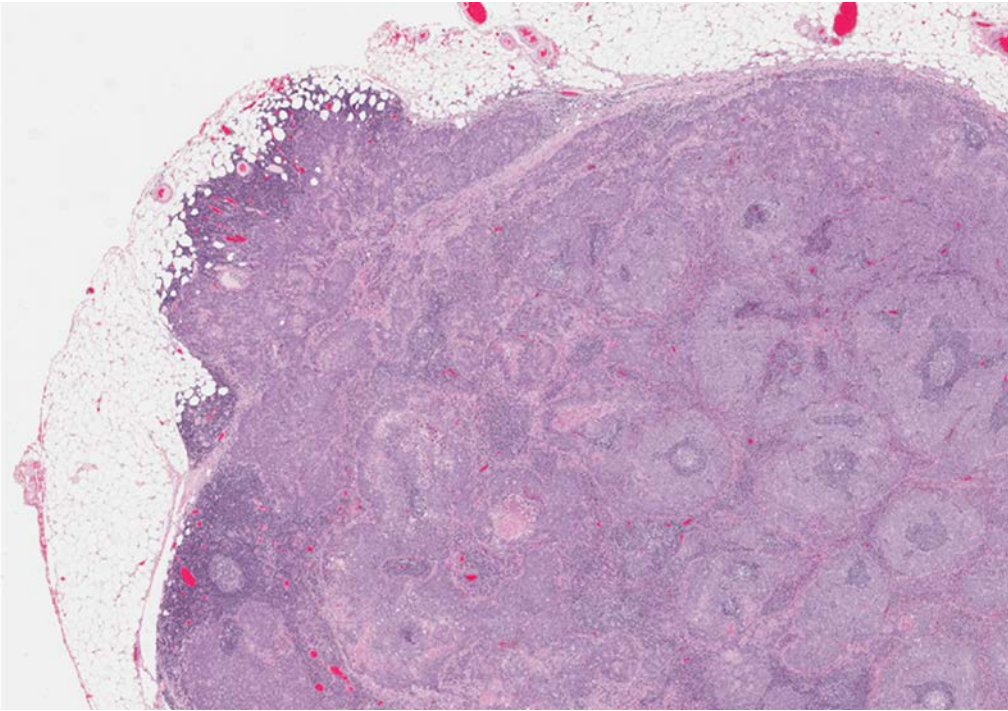


Figure 3: Low power image of a lymph node containing metastatic squamous cell carcinoma, with extranodal extension into perinodal adipose tissue (20x). *Permission courtesy of Dr Martin Bullock.*

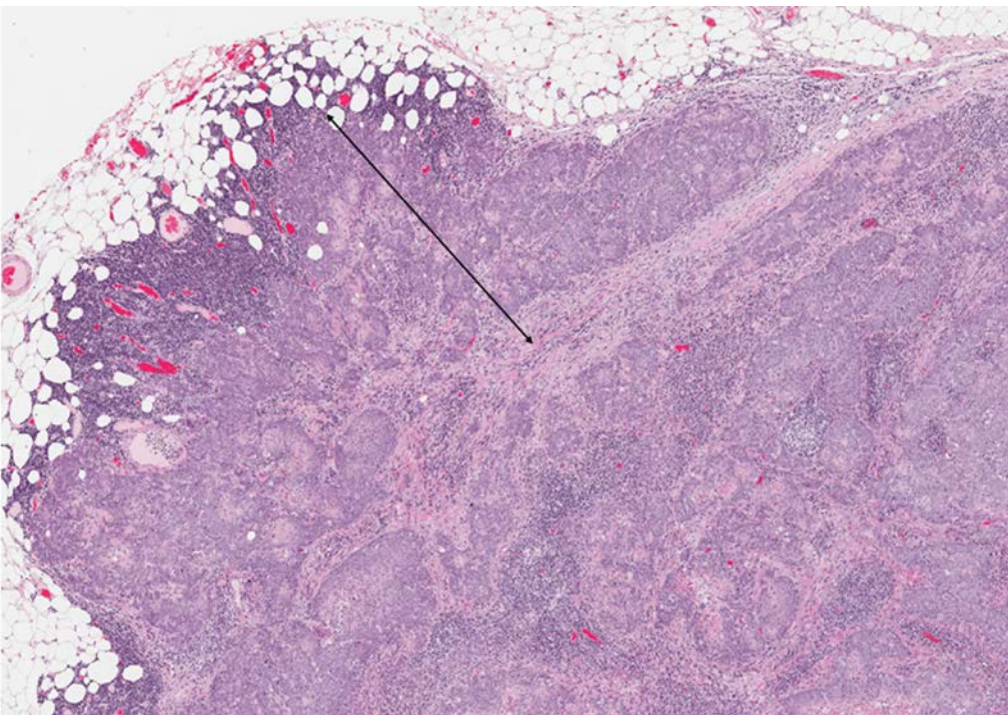


Figure 4: The extent of extranodal extension should be measured from external aspect of the capsule, or estimated site thereof, to the furthest point of tumour extension into the surrounding tissue. *Permission courtesy of Dr Martin Bullock.*

↑ Back

Note 9 – Sentinel lymph node biopsy (Non-core)

The use of sentinel lymph node (SLN) biopsy is gaining wider recognition within the head and neck oncology community for accurate staging of the neck in cT1-2 cN0 oral cavity squamous cell carcinoma (OCSCC).⁴³ Several national and international professional organisations now recommend SLN biopsy either as an alternative, or in preference, to elective neck dissection for cT1-2 cN0 OCSCC.⁴⁴⁻⁴⁸ There are currently no validated studies for the utility of SLN biopsy for other head and neck malignancies. SLN biopsy is a non-core element for OCSCC only. In general, the same principles of lymph node reporting as listed in this dataset can be applied to SLNs, except where additional information is required by local convention or study protocols. A negative SLN supports the cN0 category, assuming a formal neck dissection has not been performed.⁴³

Serial step sections with pan-cytokeratin immunohistochemistry increases the efficacy the technique, but there is currently no international consensus for the optimal histopathology laboratory handling of SLNs in OCSCC.^{49,50}

A SLN is positive when at least one node on one side of the neck contains viable carcinoma cells. If positive, the report should qualify this by stating whether the metastatic deposit is a metastasis (>2 mm), micrometastases (0.2 mm-2 mm) or ITCs (single cells or small clusters less than 0.2 mm).^{18,19} The low end diagnostic cut-offs for ITCs in OCSCC remain controversial, but their presence in SLNs have prognostic value and indicate the need for completion neck dissection.⁵¹⁻⁵³ In cases of positive SLN, the final neck staging should consider the completion neck dissection, whereas a negative SLN biopsy is staged as pN0(sn).

 **Back**

Note 10 – Other pathology (Non-core)

Additional findings should be reported at the discretion of the pathologist. Certain findings that relate to the immune status of the patient and which may be of prognostic and/or therapeutic importance are recommended by the DAC. This includes concurrent lymphoma (particularly small lymphocytic lymphoma), Castleman disease and granulomatous inflammation. The presence and number of necrotic lymph nodes following neoadjuvant therapy can also be recorded here.

 **Back**

Note 11 – Ancillary studies (Core and Non-core)

Ancillary testing for head and neck cancers most commonly refers to testing for high risk HPV status in tumours of the oropharynx and EBV status in tumours of the nasopharynx. Ancillary testing should be performed on the primary tumour if possible. Tumours presenting with a lymph node metastasis of squamous cell carcinoma and an unknown primary require testing on the lymph node specimen. When ancillary testing is performed, it is recommended to include the type of testing, the result and interpretive guidelines if applicable.⁵⁴

Ancillary testing for HPV (either using p16 or an HPV-specific method) is a core item for metastases for SCC to level II or III lymph nodes, with an unknown primary. Neck tumours with a lymphoepithelial pattern should be tested for EBV (for example, using in situ hybridisation for EBV-encoded RNA).

 **Back**

Note 12 – Regional lymph node categorisation (Core)

Information on lymph node status is crucial for the staging and treatment of head and neck malignancies. The staging described below conforms to the 8th edition of the Union for International Cancer Control (UICC)/American Joint Committee on Cancer (AJCC) Staging Manuals.^{18,19}

Note that (i) Midline nodes are considered ipsilateral nodes and (ii) ENE detected on histopathologic examination is designated as ENE_{mi} (microscopic ENE ≤2 mm) or ENE_{ma} (major ENE >2 mm). Both ENE_{mi} and ENE_{ma} qualify as ENE(+) for definition of pN.

Note that a designation of 'U' or 'L' may be used for any N category to indicate metastasis above the lower border of the cricoid (U) or below the lower border of the cricoid (L). Similarly, clinical and pathological ENE should be recorded as ENE(-) or ENE(+).

Assignment of a pN category is applicable for patients who are treated surgically with a cervical lymph node dissection, rather than single lymph node excisional biopsy, in which case the cN category is used.^{18,19}

Nasopharyngeal carcinoma (NPC) commonly presents with bulky nodal neck disease, and a lymph node biopsy may occasionally precede biopsy of the primary site. However, NPC is not a surgically treated disease,⁵⁵ and therefore pathologists are rarely called upon to provide a pN category for NPC. A single positive lymph node biopsy would contribute to the cN categorisation.

The reference document TNM Supplement: A commentary on uniform use, 5th Edition (C Wittekind et al. editors) may be of assistance when staging.⁵⁶

Notes on submission of neck dissection specimens

Correct submission of neck dissection specimens is required to obtain the most accurate and clinically useful information. The number of lymph nodes obtained in a neck dissection specimen can be used as a quality metric that is associated with loco-regional recurrence and overall survival in patients with head and neck cancer.⁵⁷

Several points regarding submission of neck dissection specimens are emphasised as follows:

1. Inking of neck dissection specimens. Most neck dissections without lymph node involvement or with limited involvement (in which nodes are freely mobile and not matted or grossly involving non-lymphatic structures), will not need to be inked. However, as margin assessment is recommended, specimens with large tumour deposits, in which ENE is considered likely, should be inked.
2. Grossly negative lymph nodes should be submitted in toto. Nodes 5 mm or more should be bisected or multisected to give tissue sections of 2-3 mm thickness. Grossly involved lymph node and soft tissue metastases need not be submitted in toto, but one section per centimetre (10 mm) in greatest dimension is a reasonable approach. Sections should focus on potential areas of ENE, involvement of non-lymphatic structures, and the margin.
3. Careful gross examination is required when attempting to estimate the number of lymph nodes involved by a soft tissue mass or matted group of lymph nodes. When submitting lymph nodes that cannot be removed from the surrounding tissue (e.g., parotidectomy specimens), care should be taken not to 'double count' nodes that may be bisected and present in two cassettes. An estimate of the number of nodes in each section, is recommended. In general, the gross estimate of the number of lymph nodes is most accurate, except when tissue originally designated as node is clearly another tissue (e.g., parathyroid gland).

 **Back**

References

- 1 Merlin T, Weston A and Tooher R (2009). Extending an evidence hierarchy to include topics other than treatment: revising the Australian 'levels of evidence'. *BMC Med Res Methodol* 9:34.
- 2 WHO Classification of Tumours Editorial Board (2024). *Head and Neck Tumours, WHO Classification of Tumours, 5th Edition, Volume 10*. IARC Press, Lyon.
- 3 Bal M, Sharma A, Rane SU, Mittal N, Chaukar D, Prabhaskar K and Patil A (2022). Neuroendocrine Neoplasms of the Larynx: A Clinicopathologic Analysis of 27 Neuroendocrine Tumors and Neuroendocrine Carcinomas. *Head Neck Pathol* 16(2):375-387.
- 4 Asa SL, Arkun K, Tischler AS, Qamar A, Deng FM, Perez-Ordóñez B, Weinreb I, Bishop JA, Wenig BM and Mete O (2021). Middle Ear "Adenoma": a Neuroendocrine Tumor with Predominant L Cell Differentiation. *Endocr Pathol* 32(4):433-441.
- 5 Rivero A and Liang J (2016). Sinonasal small cell neuroendocrine carcinoma: a systematic review of 80 patients. *Int Forum Allergy Rhinol* 6(7):744-751.
- 6 Kuan EC, Alonso JE, Tajudeen BA, Arshi A, Mallen-St Clair J and St John MA (2017). Small cell carcinoma of the head and neck: A comparative study by primary site based on population data. *Laryngoscope* 127(8):1785-1790.
- 7 van der Laan TP, Iepsema R, Witjes MJ, van der Laan BF, Plaat BE and Halmos GB (2016). Meta-analysis of 701 published cases of sinonasal neuroendocrine carcinoma: The importance of differentiation grade in determining treatment strategy. *Oral Oncol* 63:1-9.
- 8 Uccella S, La Rosa S, Metovic J, Marchiori D, Scoazec JY, Volante M, Mete O and Papotti M (2021). Genomics of High-Grade Neuroendocrine Neoplasms: Well-Differentiated Neuroendocrine Tumor with High-Grade Features (G3 NET) and Neuroendocrine Carcinomas (NEC) of Various Anatomic Sites. *Endocr Pathol* 32(1):192-210.
- 9 International Collaboration on Cancer Reporting (2024). *Carcinomas of the major salivary glands Histopathology Reporting Guide. 2nd edition*. Available from: <https://www.iccr-cancer.org/datasets/published-datasets/head-neck/salivary-glands/> (Accessed 31st July 2024).
- 10 International Collaboration on Cancer Reporting (2024). *Head & Neck datasets*. Available from: <https://www.iccr-cancer.org/datasets/published-datasets/head-neck/> (Accessed 31st July 2024).
- 11 Ferlito A, Robbins KT, Shah JP, Medina JE, Silver CE, Al-Tamimi S, Fagan JJ, Paleri V, Takes RP, Bradford CR, Devaney KO, Stoeckli SJ, Weber RS, Bradley PJ, Suarez C, Leemans CR, Coskun HH, Pitman KT, Saha AR, de Bree R, Hartl DM, Haigentz M, Jr., Rodrigo JP, Hamoir M, Khafif A, Langendijk JA, Owen RP, Sanabria A, Stojan P, Vander Poorten V, Werner JA, Bien S, Woolgar JA, Zbaren P, Betka J, Folz BJ, Genden EM, Talmi YP, Strome M, Gonzalez Botas JH, Olofsson J, Kowalski LP, Holmes JD, Hira Y and Rinaldo A (2011). Proposal for a rational classification of neck dissections. *Head Neck* 33(3):445-450.
- 12 Robbins KT, Medina JE, Wolfe GT, Levine PA, Sessions RB and Pruet CW (1991). Standardizing neck dissection terminology. Official report of the Academy's Committee for Head and Neck Surgery and Oncology. *Arch Otolaryngol Head Neck Surg* 117(6):601-605.

- 13 Spiessl B (1992). *TNM Atlas: Illustrated Guide to the TNM/pTNM Classification of Malignant Tumours (UICC International Union Against Cancer)*. Springer, Germany.
- 14 Gregoire V, Coche E, Cosnard G, Hamoir M and Reychler H (2000). Selection and delineation of lymph node target volumes in head and neck conformal radiotherapy. Proposal for standardizing terminology and procedure based on the surgical experience. *Radiother Oncol* 56(2):135-150.
- 15 Chiesa-Estomba CM, Urazan JD, Cammaroto G, Mannelli G, Molteni G, Dallari V, Lechien JR, Mayo-Yanez M, González-García J, Sistiaga-Suarez JA, Tucciarone M, Ayad T and Meccariello G (2023). Lymph node metastasis in level IIb in oropharyngeal squamous cell carcinoma: a multicentric, longitudinal, retrospective analysis. *Eur Arch Otorhinolaryngol* 280(2):869-876.
- 16 Movahed A, Reeves WC, Rose GC, Wheeler WS and Jolly SR (1990). Dobutamine and improvement of regional and global left ventricular function in coronary artery disease. *Am J Cardiol* 66(3):375-377.
- 17 Contrera KJ, Huang AT, Shenson JA, Tang C, Roberts D, Myers JN, Weber RS, Lai SY, Williams M, El-Hallal M, Jacob D and Zafereo M (2022). Primary and recurrent regional metastases for lateralized oral cavity squamous cell carcinoma. *Surg Oncol* 44:101804.
- 18 Brierley JD, Gospodarowicz MK and Wittekind C (eds) (2016). *Union for International Cancer Control. TNM Classification of Malignant Tumours, 8th Edition*, Wiley, USA.
- 19 Amin MB, Edge SB, Greene FL, Byrd DR, Brookland RK, Washington MK, Gershenwald JE, Compton CC, Hess KR, Sullivan DC, Jessup JM, Brierley JD, Gaspar LE, Schilsky RL, Balch CM, Winchester DP, Asare EA, Madera M, Gress DM and Meyer LR (eds) (2017). *AJCC Cancer Staging Manual. 8th ed.*, Springer, New York.
- 20 Robbins KT, Clayman G, Levine PA, Medina J, Sessions R, Shaha A, Som P and Wolf GT (2002). Neck dissection classification update: revisions proposed by the American Head and Neck Society and the American Academy of Otolaryngology-Head and Neck Surgery. *Arch Otolaryngol Head Neck Surg* 128(7):751-758.
- 21 Robbins KT, Shaha AR, Medina JE, Califano JA, Wolf GT, Ferlito A, Som PM and Day TA (2008). Consensus statement on the classification and terminology of neck dissection. *Arch Otolaryngol Head Neck Surg* 134(5):536-538.
- 22 Medina JE (1989). A rational classification of neck dissections. *Otolaryngol Head Neck Surg* 100(3):169-176.
- 23 Paleri V, Urbano TG, Mehanna H, Repanos C, Lancaster J, Roques T, Patel M and Sen M (2016). Management of neck metastases in head and neck cancer: United Kingdom National Multidisciplinary Guidelines. *J Laryngol Otol* 130(S2):S161-s169.
- 24 Lewis JS, Jr., Beadle B, Bishop JA, Chernock RD, Colasacco C, Lacchetti C, Moncur JT, Rocco JW, Schwartz MR, Seethala RR, Thomas NE, Westra WH and Faquin WC (2017). Human Papillomavirus Testing in Head and Neck Carcinomas: Guideline From the College of American Pathologists. *Arch Pathol Lab Med* 142(5):559-597.

- 25 Leemans CR, Tiwari R, van der Waal I, Karim AB, Nauta JJ and Snow GB (1990). The efficacy of comprehensive neck dissection with or without postoperative radiotherapy in nodal metastases of squamous cell carcinoma of the upper respiratory and digestive tracts. *Laryngoscope* 100(11):1194-1198.
- 26 Smeele LE, Leemans CR, Langendijk JA, Tiwari R, Slotman BJ, van Der Waal I and Snow GB (2000). Positive surgical margins in neck dissection specimens in patients with head and neck squamous cell carcinoma and the effect of radiotherapy. *Head Neck* 22(6):559-563.
- 27 Harris JP, Chen MM, Orosco RK, Sirjani D, Divi V and Hara W (2018). Association of Survival With Shorter Time to Radiation Therapy After Surgery for US Patients With Head and Neck Cancer. *JAMA Otolaryngol Head Neck Surg* 144(4):349-359.
- 28 Jose J, Moor JW, Coatesworth AP, Johnston C and MacLennan K (2004). Soft tissue deposits in neck dissections of patients with head and neck squamous cell carcinoma: prospective analysis of prevalence, survival, and its implications. *Arch Otolaryngol Head Neck Surg* 130(2):157-160.
- 29 Kaul P, Malhotra M, Arora V, Agarwal N, Singh MP and Garg PK (2023). Prognostic significance of soft tissue deposits in head and neck squamous cell carcinoma: a systematic review and meta-analysis. *Int J Oral Maxillofac Surg* 52(9):917-922.
- 30 Ferlito A, Shaha AR and Rinaldo A (2001). Evolution in the philosophy of neck dissection. *Acta Otolaryngol* 121(8):963-966.
- 31 Devaney KO, Rinaldo A and Ferlito A (2007). Micrometastases in cervical lymph nodes from patients with squamous carcinoma of the head and neck: should they be actively sought? Maybe. *Am J Otolaryngol* 28(4):271-274.
- 32 Alkureishi LW, Burak Z, Alvarez JA, Ballinger J, Bilde A, Britten AJ, Calabrese L, Chiesa C, Chiti A, de Bree R, Gray HW, Hunter K, Kovacs AF, Lassmann M, Leemans CR, Mamelle G, McGurk M, Mortensen J, Poli T, Shoaib T, Sloan P, Sorensen JA, Stoeckli SJ, Thomsen JB, Trifiro G, Werner J and Ross GL (2009). Joint practice guidelines for radionuclide lymphoscintigraphy for sentinel node localization in oral/oropharyngeal squamous cell carcinoma. *Ann Surg Oncol* 16(11):3190-3210.
- 33 Harish K (2005). Neck dissections: radical to conservative. *World J Surg Oncol* 3(1):21.
- 34 Tsai MH, Chuang HC, Chien CY, Huang TL, Lu H, Su YY, Yang CH, Lai CC, Tsai WL, Lin YT and Fang FM (2023). Lymph node ratio as a survival predictor for head and neck squamous cell carcinoma with multiple adverse pathological features. *Head Neck* 45(8):2017-2027.
- 35 Wang K, Tian W, Xu X, Peng X, Tang H, Zhao Y, Wang X and Li G (2022). Positive lymph node ratio predicts adverse prognosis for patients with lymph nodes metastatic hypopharyngeal squamous cell carcinoma after primary surgery. *Transl Cancer Res* 11(3):463-474.
- 36 Gartagani Z, Doumas S, Kyriakopoulou A, Economopoulou P, Psaltopoulou T, Kotsantis I, Sergentanis TN and Psyrris A (2022). Lymph Node Ratio as a Prognostic Factor in Neck Dissection in Oral Cancer Patients: A Systematic Review and Meta-Analysis. *Cancers (Basel)* 14(18):4456.
- 37 Huang SH, Chernock R, O'Sullivan B and Fakhry C (2021). Assessment Criteria and Clinical Implications of Extranodal Extension in Head and Neck Cancer. *Am Soc Clin Oncol Educ Book* 41:265-278.

- 38 Benchetrit L, Torabi SJ, Givi B, Haughey B and Judson BL (2021). Prognostic Significance of Extranodal Extension in HPV-Mediated Oropharyngeal Carcinoma: A Systematic Review and Meta-analysis. *Otolaryngol Head Neck Surg* 164(4):720-732.
- 39 An Y, Park HS, Kelly JR, Stahl JM, Yarbrough WG, Burtness BA, Contessa JN, Decker RH, Koshy M and Husain ZA (2017). The prognostic value of extranodal extension in human papillomavirus-associated oropharyngeal squamous cell carcinoma. *Cancer* 123(14):2762-2772.
- 40 Cooper JS, Pajak TF, Forastiere AA, Jacobs J, Campbell BH, Saxman SB, Kish JA, Kim HE, Cmelak AJ, Rotman M, Machtay M, Ensley JF, Chao KS, Schultz CJ, Lee N and Fu KK (2004). Postoperative concurrent radiotherapy and chemotherapy for high-risk squamous-cell carcinoma of the head and neck. *N Engl J Med* 350(19):1937-1944.
- 41 Bernier J, Dometge C, Ozsahin M, Matuszewska K, Lefebvre JL, Greiner RH, Giralt J, Maingon P, Rolland F, Bolla M, Cогnetti F, Bourhis J, Kirkpatrick A and van Glabbeke M (2004). Postoperative irradiation with or without concomitant chemotherapy for locally advanced head and neck cancer. *N Engl J Med* 350(19):1945-1952.
- 42 Spector ME, Chinn SB, Bellile E, Gallagher KK, Ibrahim M, Vainshtein J, Chanowski EJ, Walline HM, Moyer JS, Prince ME, Wolf GT, Bradford CR, McHugh JB, Carey T, Worden FP, Eisbruch A and Chepeha DB (2016). Matted nodes as a predictor of distant metastasis in advanced-stage III/IV oropharyngeal squamous cell carcinoma. *Head Neck* 38(2):184-190.
- 43 Vaish R, Mittal N, Mahajan A, Rane SU, Agrawal A and D'Cruz AK (2022). Sentinel node biopsy in node negative early oral cancers: Solution to the conundrum! *Oral Oncol* 134:106070.
- 44 Keam B, Machiels JP, Kim HR, Licitra L, Golusinski W, Gregoire V, Lee YG, Belka C, Guo Y, Rajappa SJ, Tahara M, Azrif M, Ang MK, Yang MH, Wang CH, Ng QS, Wan Zamaniah WI, Kiyota N, Babu S, Yang K, Curigliano G, Peters S, Kim TW, Yoshino T and Pentheroudakis G (2021). Pan-Asian adaptation of the EHNS-ESMO-ESTRO Clinical Practice Guidelines for the diagnosis, treatment and follow-up of patients with squamous cell carcinoma of the head and neck. *ESMO Open* 6(6):100309.
- 45 Machiels JP, René Leemans C, Golusinski W, Grau C, Licitra L and Gregoire V (2020). Squamous cell carcinoma of the oral cavity, larynx, oropharynx and hypopharynx: EHNS-ESMO-ESTRO Clinical Practice Guidelines for diagnosis, treatment and follow-up. *Ann Oncol* 31(11):1462-1475.
- 46 National Institute for Health and Care Excellence (2018). *Cancer of the upper aerodigestive tract: assessment and management in people aged 16 and over*. Available from: <https://www.ncbi.nlm.nih.gov/books/NBK553116/> (Accessed 18th July 2024).
- 47 Lai SY and Ferris RL (2020). Evolving Evidence in Support of Sentinel Lymph Node Biopsy for Early-Stage Oral Cavity Cancer. *J Clin Oncol* 38(34):3983-3986.
- 48 National Comprehensive Cancer Network (2024). *Head and Neck Cancers: NCCN Guidelines Version 4.2024*. Available from: <https://www.nccn.org/guidelines/guidelines-detail?category=1&id=1437> (Accessed 18th July 2024).
- 49 Liu M, Wang SJ, Yang X and Peng H (2017). Diagnostic Efficacy of Sentinel Lymph Node Biopsy in Early Oral Squamous Cell Carcinoma: A Meta-Analysis of 66 Studies. *PLoS One* 12(1):e0170322.

- 50 King C, Elsherif N, Kirwan R, Schilling C, Hall G, Morgan P, Collins L, Sandison A, Odell E and Thavaraj S (2021). Serial step sections at narrow intervals with immunohistochemistry are required for accurate histological assessment of sentinel lymph node biopsy in oral squamous cell carcinoma. *Head Neck* 43(10):2985-2993.
- 51 Broglie MA, Haerle SK, Huber GF, Haile SR and Stoeckli SJ (2013). Occult metastases detected by sentinel node biopsy in patients with early oral and oropharyngeal squamous cell carcinomas: impact on survival. *Head Neck* 35(5):660-666.
- 52 Schilling C, Stoeckli SJ, Haerle SK, Broglie MA, Huber GF, Sorensen JA, Bakholdt V, Krogdahl A, von Buchwald C, Bilde A, Sebbesen LR, Odell E, Gurney B, O'Doherty M, de Bree R, Bloemena E, Flach GB, Villarreal PM, Fresno Forcelledo MF, Junquera Gutiérrez LM, Amézaga JA, Barbier L, Santamaría-Zuazua J, Moreira A, Jacome M, Vigili MG, Rahimi S, Tartaglione G, Lawson G, Nollevaux MC, Grandi C, Donner D, Bragantini E, Dequanter D, Lothaire P, Poli T, Silini EM, Sesenna E, Dolivet G, Mastronicola R, Leroux A, Sassoon I, Sloan P and McGurk M (2015). Sentinel European Node Trial (SENT): 3-year results of sentinel node biopsy in oral cancer. *Eur J Cancer* 51(18):2777-2784.
- 53 Den Toom IJ, Bloemena E, van Weert S, Karagozoglu KH, Hoekstra OS and de Bree R (2017). Additional non-sentinel lymph node metastases in early oral cancer patients with positive sentinel lymph nodes. *Eur Arch Otorhinolaryngol* 274(2):961-968.
- 54 Singhi AD and Westra WH (2010). Comparison of human papillomavirus in situ hybridization and p16 immunohistochemistry in the detection of human papillomavirus-associated head and neck cancer based on a prospective clinical experience. *Cancer* 116(9):2166-2173.
- 55 Yoshizaki T, Ito M, Murono S, Wakisaka N, Kondo S and Endo K (2012). Current understanding and management of nasopharyngeal carcinoma. *Auris Nasus Larynx* 39(2):137-144.
- 56 Wittekind C, Brierley JD, van Eycken AL and van Eycken E (eds) (2019). *TNM Supplement: A Commentary on Uniform Use, 5th Edition*, Wiley, USA.
- 57 Divi V, Harris J, Harari PM, Cooper JS, McHugh J, Bell D, Sturgis EM, Cmelak AJ, Suntharalingam M, Raben D, Kim H, Spencer SA, Laramore GE, Trotti A, Foote RL, Schultz C, Thorstad WL, Zhang QE, Le QT and Holsinger FC (2016). Establishing quality indicators for neck dissection: Correlating the number of lymph nodes with oncologic outcomes (NRG Oncology RTOG 9501 and RTOG 0234). *Cancer* 122(22):3464-3471.