

Family/Last name Date of birth Given name(s) Patient identifiers Date of request Accession/Laboratory number Elements in **black text** are **CORE**. Elements in **grey text** are **NON-CORE**. indicates multi-select values indicates single select values[SCOPE OF THIS DATASET](#)**CLINICAL INFORMATION** (Note 1)

- Information not provided
 Information provided (select all that apply)

 Previous therapy

- Surgery
 Chemotherapy
 Radiotherapy

 Targeted therapy, *specify if available* Immunotherapy, *specify if available* Other clinical information, *specify***OPERATIVE PROCEDURE** (select all that apply) (Note 2)

- Not specified
 Biopsy (excisional, incisional, core needle (diagnostic sampling)), *specify*

 Resection

- Sleeve resection: cartilaginous portion of ear canal, and skin of the external auditory canal (EAC), and ear drum
 Limited temporal bone resection: removal of mastoid bone, preserving bony EAC
 Lateral temporal bone (LTB): removal of the temporal bone including ear canal, middle ear, mastoid
 Subtotal temporal bone resection (STBR): removal of the temporal bone as stated in LTB, and inner ear structure
 Total temporal bone resection (TTBR): removal of the temporal bone as stated in STBR, and petrous apex

 Parotidectomy Neck (lymph node) dissection,^a *specify* Other, *specify including laterality*^a If a *neck (lymph node) dissection* is submitted, then a separate dataset is used to record the information.**SPECIMEN(S) SUBMITTED** (select all that apply) (Note 3)

- Not specified
 Biopsy only
 Sleeve resection of temporal bone
 Lateral temporal bone
 Middle ear contents
 Subtotal temporal bone resection
 Partial mastoidectomy with middle ear contents
 Radical mastoidectomy
 Pinna
 Parotidectomy
 Temporomandibular joint (TMJ)
 Dura

- Temporal fossa
 Posterior fossa

 Neck (lymph node) dissection,^a *specify* Other, *specify including laterality***TUMOUR SITE** (select all that apply) (Note 4)

- Not specified
 External auditory canal (EAC)
 Middle ear
 Temporal bone (including mastoid, petrous)
 Inner ear
 Other, *specify*

TUMOUR LATERALITY

- Not specified
 Left
 Right

TUMOUR FOCALITY (Note 5)

- Unifocal
- Bilateral
- Multifocal

Specify number of tumours

TUMOUR DIMENSIONS (Note 6)

Maximum tumour dimension (largest tumour)
(pathology and/or imaging determination)

mm

Additional dimensions (largest tumour)

mm x mm

BLOCK IDENTIFICATION KEY (Note 7)

(List overleaf or separately with an indication of the nature and origin of all tissue blocks)

HISTOLOGICAL TUMOUR TYPE (select all that apply) (Note 8)

(Value list based on the World Health Organization Classification of Head and Neck Tumours (2024))

External auditory canal

- Ceruminous adenoma
- Ceruminous adenocarcinoma
 - Adenoid cystic
 - Mucoepidermoid
 - NOS
- Squamous cell carcinoma

Middle and inner ear

- Middle ear papilloma
- Vestibular schwannoma
- Middle ear neuroendocrine tumour
- Endolymphatic sac tumour
- Squamous cell carcinoma of the middle ear
- Middle ear adenocarcinoma

Other, specify

HISTOLOGICAL TUMOUR GRADE^b (Note 9)

(Applicable to squamous cell carcinoma and neuroendocrine tumours only)

- Grade 1, well differentiated, low grade
- Grade 2, moderately differentiated, intermediate grade
- Grade 3, poorly differentiated, high grade
- Undifferentiated
- High grade transformation

Grading system used, specify

- Cannot be assessed, specify

^b Grading of neuroendocrine tumours is non-core. Use only Grade 1, 2 and 3 for neuroendocrine tumours; neuroendocrine carcinomas are considered high grade by definition and are therefore not graded.

EXTENT OF INVASION (Note 10)

- Not identified
- Present (select all that apply)
 - Clinical observation and/or imaging
 - Histologic



- Skin involvement
- Bone/cartilage (mastoid bone)
 - Superficial cortical involvement
 - Full thickness bone involvement
- Dura involvement
- Brain involvement
- Temporomandibular joint (TMJ) involvement
- Parotid gland involvement
- Soft tissue involvement
 - ≤5 mm
 - >5 mm
 - Indeterminate, specify reason

- Other, specify

- Cannot be assessed, specify

LYMPHOVASCULAR INVASION (Note 11)

- Not identified
- Present, specify if named (select all that apply)
 - Internal jugular vein
 - Carotid artery
- Indeterminate, specify reason

PERINEURAL INVASION (Note 12)

- Not identified
- Present, specify nerve if possible (e.g., facial nerve, tympanic nerve, glossopharyngeal nerve, lesser petrosal nerve, greater petrosal nerve)

- Indeterminate, specify reason

MARGIN STATUS (Note 13)

(Applicable for squamous cell carcinoma and adenocarcinoma only)

Not involved by invasive carcinoma
 Distance of tumour from closest margin mm

Distance not assessable
 Specify closest margin(s), if possible (select all that apply)

- Skin
- Bone
- Soft tissue
- Parotid gland

Involved by invasive carcinoma
 Specify margin(s), if possible

Cannot be assessed, specify

COEXISTENT PATHOLOGY (select all that apply) (Note 14)

- None identified
- Cholesterol granuloma
- Cholesteatoma
- Osteomyelitis (acute, chronic)
- Papilloma
- Other, specify

ANCILLARY STUDIES (Note 15)

Neuroendocrine neoplasms (select all that apply)

Not applicable
 Neuroendocrine markers, specify

Cytokeratin(s), specify

Ki-67 proliferation index %

Rb
 Retained
 Deficient

p53
 Abnormal, specify

Other, record test(s), methodology and results

Other tumours

- Not performed
- Performed, record test(s), methodology and results

Representative blocks for ancillary studies, specify those blocks best representing tumour and/or normal tissue for further study

PATHOLOGICAL STAGING (Note 16)

TNM Descriptors (only if applicable) (select all that apply)

- m - multiple primary tumours
- r - recurrent
- y - during or following multimodality therapy

Primary tumour (pT)^c

- Not applicable
- T1 Tumour limited to the external auditory canal (EAC) without bony erosion or evidence of soft tissue involvement
- T2 Tumour with limited EAC bone erosion (not full thickness) or limited (≤ 5 mm) soft tissue involvement
- T3 Tumour eroding the osseous EAC (full thickness) with limited (≤ 5 mm) soft tissue involvement, or tumour involving the middle ear and/or mastoid
- T4 Tumour eroding the cochlea, petrous apex, medial wall of the middle ear, carotid canal, jugular foramen, or dura, or with extensive soft tissue involvement (> 5 mm), such as involvement of temporomandibular joint (TMJ) or styloid process, or evidence of facial paresis

^c Note that the results of neck (lymph node) dissection are derived from a separate dataset.

Definitions

CORE elements

CORE elements are those which are essential for the clinical management, staging or prognosis of the cancer. These elements will either have evidentiary support at Level III-2 or above (based on prognostic factors in the National Health and Medical Research Council (NHMRC) levels of evidence¹). In rare circumstances, where level III-2 evidence is not available an element may be made a CORE element where there is unanimous agreement by the Dataset Authoring Committee (DAC). An appropriate staging system e.g., Pathological TNM staging would normally be included as a CORE element.

Molecular and immunohistochemical testing is a growing feature of cancer reporting. However, in many parts of the world this type of testing is limited by the available resources. In order to encourage the global adoption of ancillary tests for patient benefit, International Collaboration on Cancer Reporting (ICCR) includes the most relevant ancillary testing in ICCR Datasets as CORE elements, especially when they are necessary for the diagnosis. Where the technical capability does not yet exist, laboratories may consider temporarily using these data elements as NON-CORE items.

The summation of all CORE elements is considered to be the minimum reporting standard for a specific cancer.

NON-CORE elements

NON-CORE elements are those which are unanimously agreed should be included in the dataset but are not supported by level III-2 evidence. These elements may be clinically important and recommended as good practice but are not yet validated or regularly used in patient management.

Key information other than that which is essential for clinical management, staging or prognosis of the cancer such as macroscopic observations and interpretation, which are fundamental to the histological diagnosis and conclusion e.g., macroscopic tumour details, may be included as either CORE or NON-CORE elements by consensus of the DAC.

↑ Back

Scope

The dataset has been developed for the reporting of resection and biopsy specimens of the ear and temporal bone. It includes only primary tumours of the external auditory canal, middle and inner ear, including both benign and malignant entities (specifically due to anatomic confines and management alternatives which may require significant, destructive or disfiguring surgery).

By definition, all malignancies of the external ear (pinna, concha, scaphoid, lobe, etc., such as squamous cell carcinoma (SCC), basal cell carcinoma, pleomorphic dermal sarcoma, Merkel cell carcinoma and melanoma) are separately covered by the ICCR Skin datasets.² Primary parotid gland malignancies with direct extension in to the ear canal are excluded; the ICCR Carcinomas of the major salivary glands dataset should be used.³ Haematolymphoid neoplasms are also excluded from this dataset.

Neck dissections and nodal excisions are dealt with in a separate dataset, and this dataset should be used in conjunction, where applicable.⁴

For bilateral tumours, a separate dataset should be completed for each tumour.

This dataset is intended for use for primary tumour resections. For resections of recurrent disease, the reporting guide may be used pragmatically although some data elements may be not applicable nor assessable.

The second edition of this dataset includes changes to align the dataset with the World Health Organization (WHO) Classification of Head and Neck Tumours, 5th edition, 2023.⁵

There is very limited evidence supporting the various core and non-core elements in this dataset. All elements have thus been included by unanimous consensus of the DAC.

A list of changes in this dataset edition can be accessed [here](#).

The authors of this dataset can be accessed [here](#).

↑ Back

Note 1 – Clinical information (Core and Non-core)

In the context of a recurrent tumour, patients may have had previous surgery, radiotherapy, chemotherapy or immunotherapy. Diagnostic procedures may be performed, followed by various cytoreduction therapies. As such, a core needle biopsy, incisional biopsy or even debulking surgery may have been performed, and would be documented as ‘surgery’ in this context. Information regarding previous treatment should be recorded.

Currently, neoadjuvant therapy including radiotherapy, chemotherapy or immunotherapy is not deployed in the tumours of the ear and temporal bone. However, it will be wise to include this field for future utilisation and harmonisation across the suite of structured reporting protocols as the treatment paradigms evolve. Of note, criteria for assessment of pathological response will also need to be developed.

↑ Back

Note 2 – Operative procedure (Core)

The anatomy and surgical interventions of the ear and temporal bone are complex,^{6,7} with unfamiliar terminology frequently used (see Figure 1). Thus, it is absolutely critical to maintain open communication with the treating surgeon, oncologist, dermatologist and radiologist with respect to exact anatomic site of involvement, tumour laterality, and specific operative procedures or landmarks identified to yield the most accurate information.⁸⁻¹¹

There is no internationally standardised terminology to describe the type and extent of temporal bone resection. For this version of the ICCR Ear and temporal bone dataset, the dataset authors have adopted widely used terminologies to describe the various types of temporal bone resection, in progressively more radical procedures. These include:

1. Sleeve resection: The tumour is completely resected with or without the cartilaginous part of the external ear canal (EAC). The bony EAC and the tympanic membrane (TM) are preserved. This type of resection is suitable for very superficial malignancy (or in situ disease) limited to the skin of the EAC.
2. Limited (or cortical) temporal bone resection: In this procedure the mastoid bone is removed while the EAC structure and the TM are preserved. This surgery is generally used for tumours involving

- only the temporal bone, sparing the EAC and middle ear structures. It can also be used for tumours involving the skin posterior to the auricle, where a concurrent resection of the skin is performed.
3. Lateral temporal bone resection: In this procedure, the EAC, the TM, the middle ear structures and the mastoid are removed. The inner ear is preserved. This procedure is generally performed for tumour that involve the entire EAC where removal of the TM is necessary.
 4. Subtotal temporal bone resection: In this procedure, the temporal bone, the EAC, TM, the middle ear structure and the inner ear are removed. Often, the facial nerve will need to be either re-routed or sacrificed. Depending on the extent of tumour, a concurrent resection of the posterior fossa dura or the temporal lobe dura might be required for disease clearance.
 5. Total temporal bone resection: In this procedure, the temporal bone, EAC, TM/middle ear, the inner ear, as well as the petrous apex are removed. Often, ligation of the carotid artery will be required.

Any of these procedures may be accompanied by a parotidectomy and/or neck dissection.

Occasionally, the subtotal and total temporal bone resection may be accompanied by dura and brain parenchyma. Often, the specimens may be submitted for histopathological assessment in multiple parts and/or fragments. Communication with the surgeon and correlation with radiology is important for assessing the extent of invasion and particularly for margin assessment.

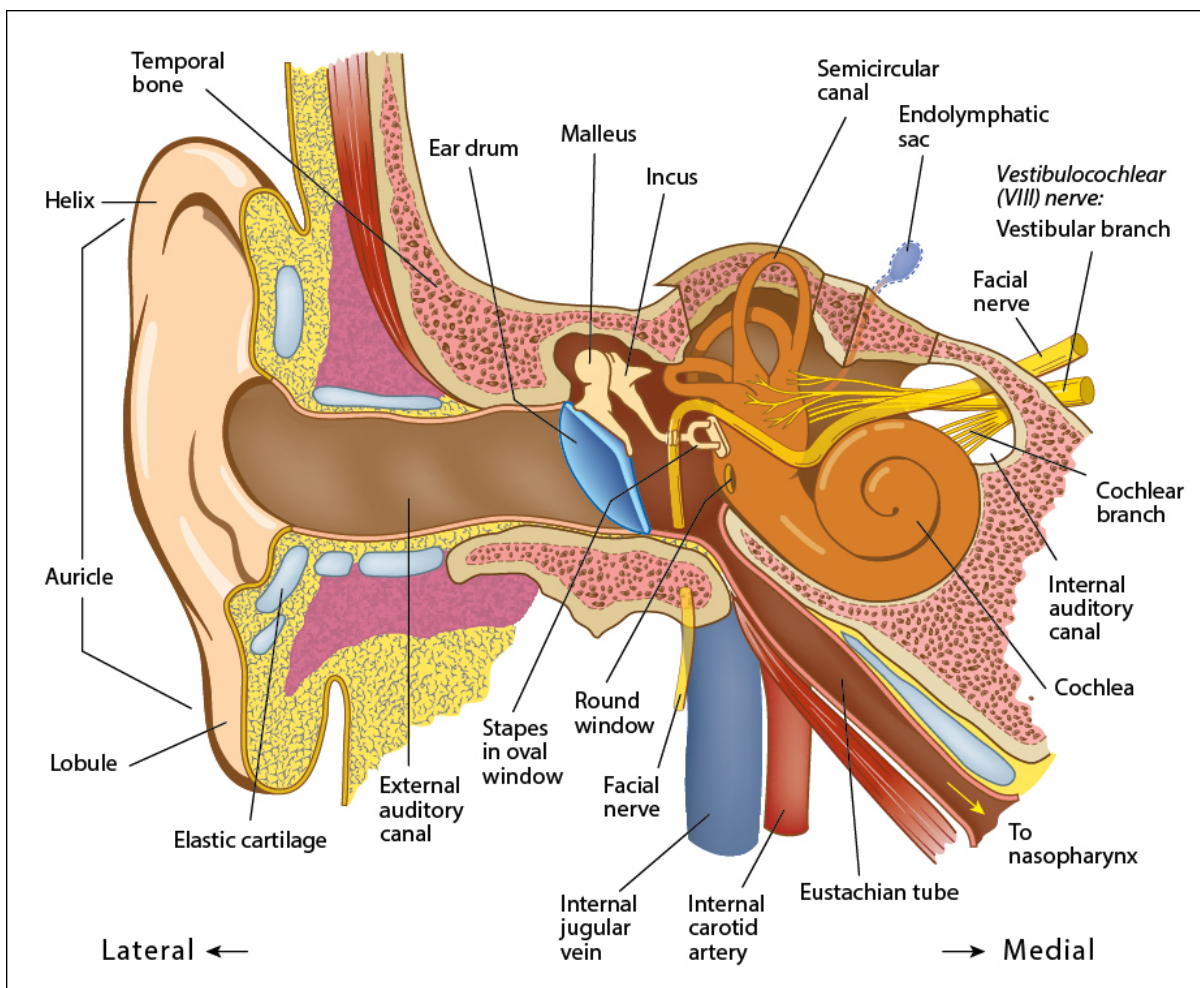


Figure 1: Diagram of ear and temporal bone anatomic landmarks.

© 2024 International Collaboration on Cancer Reporting Limited (ICCR).

↑ Back

Note 3 – Specimen(s) submitted (Core)

In light of the complex anatomy and often unfamiliar surgical interventions of the ear and temporal bone, it is imperative to obtain information about the exact anatomic site of involvement, tumour laterality, and specific operative procedures or landmarks identified to yield the most accurate information.^{12,13}

‘Not specified’ should be used rarely and only after good faith effort has been employed to obtain the requisite information.

 **Back**

Note 4 – Tumour site (Core)

It is important to document the exact site of the tumour, as tumour location is correlated with patient outcome. As an example, patients with middle ear SCCs have a worse outcome than patients with SCC of the external auditory canal.^{6,8,10,14-18}

 **Back**

Note 5 – Tumour focality (Non-core)

The identification of bilateral tumours, especially in the setting of endolymphatic sac tumours,^{19,20} paraganglioma,^{21,22} acoustic/vestibular Schwannoma,²³ and meningioma,²³ increases the potential discovery of genetic tumour syndrome associated disease.

For bilateral or multifocal tumours, a separate dataset should be completed for each tumour.

 **Back**

Note 6 – Tumour dimensions (Non-core)

The single greatest tumour dimension, using macroscopic and/or microscopic measurements, should be used to determine the most accurate extent of tumour. In biopsy samples, it may be underestimated. Thus, to be as thorough as possible, the documentation of the tumour dimension may require additional clinical/operative or imaging information to yield this value. However, as tumour size is not used in staging, this element is non-core. While tumour size is a non-core element, the extent of invasion contributes to the proposed staging system with 5 millimetres (mm) as a threshold with upstaging of tumours invading the soft tissues >5 mm (see **Note 10 – EXTENT OF INVASION**).

 **Back**

Note 7 – Block identification key (Non-core)

The origin/designation of all tissue blocks should be recorded. This information should ideally be documented in the final pathology report and is particularly important should the need for internal or external review arise. The reviewer needs to be clear about the origin of each block in order to provide an informed specialist opinion. If this information is not included in the final pathology report, it should be

available on the laboratory computer system and relayed to the reviewing pathologist. It may be useful to have a digital image of the specimen and record of the origin of the tumour blocks in some cases.

Recording the origin/designation of tissue blocks also facilitates retrieval of blocks for further immunohistochemical or molecular analysis, research studies or clinical trials.

↑ Back

Note 8 – Histological tumour type (Core)

Histologic diagnosis of ear and temporal bone tumours is based on the 2023 WHO Classification of Head and Neck Tumours, 5th edition (Table 1).^{5,24} Neuroendocrine tumours (NET) (formerly middle ear adenoma) are also included.²⁵⁻²⁷ While neuroendocrine carcinomas (NEC) are recognised, they are not documented yet as primary tumours in this anatomic site.

The types of ear and temporal bone primary tumours are limited. Few cases have been reported for several specific tumour categories, and thus prognostication about each specific tumour type is limited, at best. Overall, the most common tumour type is SCC, and it is known to have the worst patient outcome.^{5,28-33} When adenoid cystic carcinoma and mucoepidermoid carcinoma are the ceruminous adenocarcinoma type, parotid gland evaluation is recommended to exclude origin from the parotid gland with secondary invasion into the external canal.^{34,35}

Table 1: World Health Organization classification of tumours of the ear and temporal bone.⁵

Descriptor	ICD-O codes ^a
External auditory canal	
Ceruminous adenoma	8420/0
Squamous cell carcinoma of the external auditory canal	8070/3
Ceruminous adenocarcinoma	8420/3
Ceruminous adenoid cystic carcinoma	8420/3
Ceruminous mucoepidermoid carcinoma	8420/3
Middle ear	
Meningioma	9530/0
Middle ear papilloma	8121/0
Middle ear neuroendocrine tumour	8240/3
Squamous cell carcinoma of the middle ear	8070/3
Middle ear adenocarcinoma	8260/3
Inner ear	
Endolymphatic sac tumour	8140/3
Vestibular schwannoma	9560/0

^a These morphology codes are from the International Classification of Diseases for Oncology, third edition, second revision (ICD-O-3.2).³⁶ Behaviour is coded /0 for benign tumours; /1 for unspecified, borderline, or uncertain behaviour; /2 for carcinoma in situ and grade III intraepithelial neoplasia; /3 for malignant tumours, primary site; and /6 for malignant tumours, metastatic site. Behaviour code /6 is not generally used by cancer registries.

© World Health Organization/International Agency for Research on Cancer. Reproduced with permission.

↑ Back

Note 9 – Histological tumour grade (Core and Non-core)

Generally, histologic tumour grades are applied to SCC or NETs only (core). Ceruminous carcinomas (adenoid cystic and mucoepidermoid carcinoma exclusively) can be graded based on salivary gland primaries, but no grading is accepted for ceruminous adenocarcinoma, not otherwise specified (NOS). Poorly differentiated tumours indicate a poor patient survival.³⁷

The same grading of central nervous system meningiomas is applied to ear and temporal bone, realising that >95% are WHO grade 1 tumours.^{38,39}

A three tiered grading system has been proposed for NETs (non-core),⁵ utilising proliferation index/mitoses to aid separation, similar to NETs of the larynx, lung and gastrointestinal tract. In general, a Ki-67 proliferation index <2% is grade 1, 2-20%, grade 2, and >20% grade 3, although case numbers are small.⁴⁰ NECs are considered high grade by definition and are therefore not graded, although not yet documented as a primary tumour in this site.

Other tumour types for the most part do not have tiered grading systems (such as ceruminous adenocarcinoma, NOS, endolymphatic sac tumours, schwannoma or middle ear adenocarcinoma).

Still, several grading systems are available, with differing merits, and as such, recording which system has been applied is more clinically meaningful (use 'specify' to state the system used), with the ICCR deferring to the WHO Classification current edition for grading guidance and preference.⁵

 **Back**

Note 10 – Extent of invasion (Core)

The extent of invasion contributes to the proposed staging system and all attempts should be made to measure this accurately. Infiltration of the soft tissues by the tumour >5 mm indicates high stage (defined by measuring tumour involving submucosal stroma/soft tissues below the inter-rete basement membrane).

If there is involvement of any of these recognised structures, documentation will provide prognosis and management information.^{38,41} For example, patients with primary ear and temporal bone carcinoma with parotid gland involvement have a worse prognosis than patients without parotid gland involvement.³⁴ If there is advanced disease clinically, then parotid gland resection is generally recommended.³⁴ The macroscopic and microscopic extent of tumour frequently overlap. Thus, invasion 'microscopically' into any of these structures is for the most part not recognised, unless the part is specifically stated to be from the site. Thus, on histologic examination, you may not recognise the specific structure. Therefore, correlation between macroscopic and microscopic findings is encouraged to yield the most meaningful findings.^{5,11,30,35,42} As an example, patients who exhibit dura involvement, will have a worse patient outcome.^{5,43} The extent of invasion may need to be evaluated by imaging or during intraoperative assessment, as histologic identification of these structures may not be feasible.

Similarly, when there is destructive cartilage and/or bone invasion, the patients tend to have a worse prognosis.^{28,29,38,42-45} Bone and/or cartilage invasion may be a macroscopic feature, sometimes not seen on histology sections due to the nature of the clinical sampling performed, and so clinical/imaging observation and/or histologic evidence may be used to support the interpretation. However, it is recommended that a histologic section through the involved bone should be performed to obtain histologic evidence of the extent of bone and/or cartilage involvement (partial versus full thickness involvement). In general, stage correlates with bone and/or cartilage invasion, with high stage patients more frequently showing bone invasion than

low stage patients.⁸ Further, patients with bone and/or cartilage invasion will usually have a worse prognosis and require more extensive treatment than patients without bone invasion.^{42,46}

Due to the type of samples, tumour budding or tentacular pattern of invasion may not be histologically identified. However, if this type of growth is seen in SCC, patients tend to have a shorter survival.^{37,46,47}

↑ Back

Note 11 – Lymphovascular invasion (Core)

By inference and consensus of the DAC, lymphovascular invasion is considered to be associated with a worse clinical outcome. However, in ear and temporal bone tumours, this finding has not been independently evaluated in prospective or prognostic studies due to low cases numbers at any given referral centre.

Cases that are still equivocal after taking additional steps may be reported as ‘indeterminate’ for lymphovascular invasion, but this designation should be sparingly used and it is useful to provide the reason in a comment in the report.

↑ Back

Note 12 – Perineural invasion (Core)

Patients who manifest perineural/intraneural invasion, especially if it is identified in large or named nerves (such as facial nerve and chorda tympani nerve), have a worse clinical outcome, irrespective of the tumour type or tumour grade.^{47,48} If the biopsy is very small with only tumour included, it may be prudent to use ‘cannot be assessed’ in order to alert the clinician that perineural invasion cannot be reliably excluded in the sampled material.

↑ Back

Note 13 – Margin status (Core and Non-core)

Margin status is reported for SCC and adenocarcinoma specifically, rather than for the benign or intermediate neoplasms (i.e., ceruminous adenoma, endolymphatic sac tumour, middle ear papilloma) or NETs. The best overall outcomes for tumours of ear and temporal bone are achieved when margins are negative. In general, mucosal/epithelial margins are reported, but bone and soft tissue margins carry similar prognostic value, and thus should also be reported, especially as the deep margins (bone and soft tissue) are often more clinically significant than superficial margins (skin). Tumours which are meticulously debulked have the best long term outcome.^{11,14,29,31,43,49-54}

↑ Back

Note 14 – Coexistent pathology (Non-core)

Management may be complicated by coexistent pathology. Patient with otitis media generally show a poor survival,¹¹ but if there is acute or chronic osteomyelitis, options for radiation and chemotherapy may be limited.^{55,56}

↑ Back

Note 15 – Ancillary studies (Core and Non-core)

For neuroendocrine neoplasms core elements are neuroendocrine markers, epithelial markers, and Ki-67 proliferation index. The diagnosis of neuroendocrine neoplasms (specifically NETs and NECs) must be confirmed immunohistochemically, with positive reaction for neuroendocrine markers (synaptophysin, chromogranin, INSM1), and for epithelial markers (pancytokeratin, cytokeratin). Furthermore, a proliferation index as determined by Ki-67 immunohistochemical analysis is recommended for grading all NETs, helping to confirm NECs, and p53 and Rb1 may be helpful in the distinction between NET and NEC, especially G3 NET from NEC.^{25,57,58}

In most patients, further studies are not required for the diagnosis. However, additional molecular testing may be of benefit, especially in syndrome associated, bilateral, or uncommon tumour presentations. Translocation associated malignancies (*BRD4::NUTM1*, *DEK::AFF2*, *EWSR1::FLI1*, *EWSR1::ERG*) should also be considered in the morphologic context of poorly differentiated non keratinising SCC.⁵⁹⁻⁶²

Immunohistochemistry may also be considered to differentiate between tumour types especially in limited sampling or tumours affected by distortional changes. Ancillary tests rarely may be required to identify the primary site of metastatic disease.

Programmed cell death-ligand 1 (PD-L1) expression has been used as predictive biomarker for checkpoint inhibitor therapy since the anti-programmed cell death-1 receptor (PD-1) antibodies, nivolumab and pembrolizumab, have been approved for the treatment of patients with recurrent and/or unresectable metastatic head and neck SCC,⁶³⁻⁶⁶ with various cutoffs of expression associated with better responses, although not in all patients.⁶⁷

↑ Back

Note 16 – Pathological staging (Core)

There is no standardised staging system for this anatomic site, although it has been suggested by several groups.^{13,68-70} However, staging is still of value in standardising therapy for these various unusual tumours. The pathological staging presented on the reporting guide is adapted from the Pittsburgh system,⁶⁹ and based on a consensus of the DAC. The T staging is most significant for SCCs and for salivary gland-type tumours, particularly of the external auditory canal and middle ear.^{14,15,29,43,71-75}

Pathological staging has not been well developed for middle ear and inner ear tumours (i.e., endolymphatic sac tumour), where clinical staging may be more appropriate.⁶⁹ In inner ear cases, it is probably more important to make certain that a clinical stage is accurately determined, than necessarily being definitive about a pathological stage. As such, benign tumours and NETs do not require staging, although the reporting guide can be used to aid treatment and outcome prognostication. The studies used as a guide are

retrospective where the patient outcomes were not available, primarily used as a guide for therapy rather than prognosis.

Overall, there is a poor prognosis when lymph node metastases are identified, correlating to advanced stage, whether in the cervical lymph nodes or those of the parotid gland parenchyma.^{11,15,35,75-77}

 **Back**

References

- 1 Merlin T, Weston A and Tooher R (2009). Extending an evidence hierarchy to include topics other than treatment: revising the Australian 'levels of evidence'. *BMC Med Res Methodol* 9:34.
- 2 International Collaboration on Cancer Reporting (2024). *Skin Datasets*. Available from: <https://www.iccr-cancer.org/datasets/published-datasets/skin/> (Accessed 15th January 2024).
- 3 International Collaboration on Cancer Reporting (2024). *Carcinomas of the major salivary glands Histopathology Reporting Guide. 2nd edition*. Available from: <https://www.iccr-cancer.org/datasets/published-datasets/head-neck/salivary-glands/> (Accessed 31st July 2024).
- 4 International Collaboration on Cancer Reporting (2024). *Nodal Excisions and Neck Dissection Specimens for Head & Neck Tumours Histopathology Reporting Guide. 2nd edition*. Available from: <https://www.iccr-cancer.org/datasets/published-datasets/head-neck/nodal-excisions/> (Accessed 31st July 2024).
- 5 WHO Classification of Tumours Editorial Board (2024). *Head and Neck Tumours, WHO Classification of Tumours, 5th Edition, Volume 10*. IARC Press, Lyon.
- 6 Isaacson B (2018). Anatomy and Surgical Approach of the Ear and Temporal Bone. *Head Neck Pathol* 12(3):321-327.
- 7 Sandison A (2022). Update from the 5th Edition of the World Health Organization Classification of Head and Neck Tumours: Tumours of the Ear. *Head Neck Pathol* 16(1):76-86.
- 8 Cristalli G, Manciooco V, Pichi B, Marucci L, Arcangeli G, Telera S and Spriano G (2009). Treatment and outcome of advanced external auditory canal and middle ear squamous cell carcinoma. *J Craniofac Surg* 20(3):816-821.
- 9 Isipradit P, Wadwongtham W, Aeumjaturapat S and Aramwatanapong P (2005). Carcinoma of the external auditory canal. *J Med Assoc Thai* 88(1):114-117.
- 10 Madsen AR, Gundgaard MG, Hoff CM, Maare C, Holmboe P, Knap M, Thomsen LL, Buchwald C, Hansen HS, Bretlau P and Grau C (2008). Cancer of the external auditory canal and middle ear in Denmark from 1992 to 2001. *Head Neck* 30(10):1332-1338.
- 11 Nakagawa T, Kumamoto Y, Natori Y, Shiratsuchi H, Toh S, Kakazu Y, Shibata S, Nakashima T and Komune S (2006). Squamous cell carcinoma of the external auditory canal and middle ear: an operation combined with preoperative chemoradiotherapy and a free surgical margin. *Otol Neurotol* 27(2):242-248; discussion 249.

- 12 Kollert M, Draf W, Minovi A, Hofmann E and Bockmuhl U (2004). [Carcinoma of the external auditory canal and middle ear: therapeutic strategy and follow up]. *Laryngorhinootologie* 83(12):818-823.
- 13 Allanson BM, Low TH, Clark JR and Gupta R (2018). Squamous Cell Carcinoma of the External Auditory Canal and Temporal Bone: An Update. *Head Neck Pathol* 12(3):407-418.
- 14 Yin M, Ishikawa K, Honda K, Arakawa T, Harabuchi Y, Nagabashi T, Fukuda S, Taira A, Himi T, Nakamura N, Tanaka K, Ichinohe M, Shinkawa H, Nakada Y, Sato H, Shiga K, Kobayashi T, Watanabe T, Aoyagi M, Ogawa H and Omori K (2006). Analysis of 95 cases of squamous cell carcinoma of the external and middle ear. *Auris Nasus Larynx* 33(3):251-257.
- 15 Stell PM and McCormick MS (1985). Carcinoma of the external auditory meatus and middle ear. Prognostic factors and a suggested staging system. *J Laryngol Otol* 99(9):847-850.
- 16 Gupta R, Bal M and Magliocca K. Squamous cell carcinoma of the external auditory canal. In: WHO Classification of Tumours Editorial Board. Head and Neck Tumours. Lyon (France): International Agency for Research on Cancer; 2024. (WHO classification of tumours series, 5th ed.; vol. 9).
- 17 Nosé V, Thompson LDR, Rodriguez FJ, et al. Endolymphatic sac tumour. In: WHO Classification of Tumours Editorial Board. Head and Neck Tumours. Lyon (France): International Agency for Research on Cancer; 2024. (WHO classification of tumours series, 5th ed.; vol. 9).
- 18 Gupta R, Agaimy A and Bal M. Middle ear squamous cell carcinoma. In: WHO Classification of Tumours Editorial Board. Head and Neck Tumours. Lyon (France): International Agency for Research on Cancer; 2024. (WHO classification of tumours series, 5th ed.; vol. 9).
- 19 Kim HJ, Hagan M, Butman JA, Baggenstos M, Brewer C, Zalewski C, Linehan WM and Lonser RR (2013). Surgical resection of endolymphatic sac tumors in von Hippel-Lindau disease: findings, results, and indications. *Laryngoscope* 123(2):477-483.
- 20 Michaels L (2007). Origin of endolymphatic sac tumor. *Head Neck Pathol* 1(2):104-111.
- 21 Wang JH, Chan KH and Lee TY (1989). Parenteral tramadol in postoperative pain relief. *Ma Zui Xue Za Zhi* 27(3):283-286.
- 22 Boedeker CC (2011). Paragangliomas and paraganglioma syndromes. *GMS Curr Top Otorhinolaryngol Head Neck Surg* 10:Doc03.
- 23 Slattery WH (2015). Neurofibromatosis type 2. *Otolaryngol Clin North Am* 48(3):443-460.
- 24 Thompson LDR (2021). Middle Ear and Temporal Bone Papilloma: A Clinicopathologic Study and Comprehensive Literature Review of 57 Cases. *Head Neck Pathol* 15(4):1212-1220.
- 25 Asa SL, Arkun K, Tischler AS, Qamar A, Deng FM, Perez-Ordóñez B, Weinreb I, Bishop JA, Wenig BM and Mete O (2021). Middle Ear "Adenoma": a Neuroendocrine Tumor with Predominant L Cell Differentiation. *Endocr Pathol* 32(4):433-441.
- 26 van der Lans RJL, Engel MSD, Rijken JA, Hensen EF, Bloemena E, van der Torn M, Leemans CR and Smit C (2021). Neuroendocrine neoplasms of the middle ear: Unpredictable tumor behavior and tendency for recurrence. *Head Neck* 43(6):1848-1853.

- 27 Engel MSD, van der Lans RJL, Jansen JC, Leemans CR, Bloemena E, Lissenberg-Witte BI, Rijken JA, Smit CF and Hensen EF (2021). Management and outcome of middle ear adenomatous neuroendocrine tumours: A systematic review. *Oral Oncol* 121:105465.
- 28 Hosokawa S, Mizuta K, Takahashi G, Okamura J, Takizawa Y, Hosokawa K, Yamatodani T and Mineta H (2014). Carcinoma of the external auditory canal: histological and treatment groups. *B-ent* 10(4):259-264.
- 29 Testa JR, Fukuda Y and Kowalski LP (1997). Prognostic factors in carcinoma of the external auditory canal. *Arch Otolaryngol Head Neck Surg* 123(7):720-724.
- 30 Rodriguez Paramas A, Gil Carrasco R, Arenas Britez O and Yurrita Scola B (2004). [Malignant tumours of the external auditory canal and of the middle ear]. *Acta Otorrinolaringol Esp* 55(10):470-474.
- 31 Shen W, Sakamoto N and Yang L (2014). Prognostic models to predict overall and cause-specific survival for patients with middle ear cancer: a population-based analysis. *BMC Cancer* 14:554.
- 32 Acharya PP, Sarma D and McKinnon B (2020). Trends of temporal bone cancer: SEER database. *Am J Otolaryngol* 41(1):102297.
- 33 Ruangritchankul K and Sandison A (2023). DEK::AFF2 Fusion Carcinomas of Head and Neck. *Adv Anat Pathol* 30(2):86-94.
- 34 Choi JY, Choi EC, Lee HK, Yoo JB, Kim SG and Lee WS (2003). Mode of parotid involvement in external auditory canal carcinoma. *J Laryngol Otol* 117(12):951-954.
- 35 Crain N, Nelson BL, Barnes EL and Thompson LD (2009). Ceruminous gland carcinomas: a clinicopathologic and immunophenotypic study of 17 cases. *Head Neck Pathol* 3(1):1-17.
- 36 Fritz A, Percy C, Jack A, Shanmugaratnam K, Sobin L, Parkin DM and Whelan S (eds) (2020). *International Classification of Diseases for Oncology, Third edition, Second revision ICD-O-3.2*. Available from: http://www.iacr.com.fr/index.php?option=com_content&view=category&layout=blog&id=100&Itemid=577 (Accessed 16th March 2024).
- 37 Leong SC, Youssef A and Lesser TH (2013). Squamous cell carcinoma of the temporal bone: outcomes of radical surgery and postoperative radiotherapy. *Laryngoscope* 123(10):2442-2448.
- 38 George M, Borsotti F, Gereige R, Kolethekkat AA, Das A, Messerer M, Mahasampath G and Simon C (2021). A systematic review of the primary squamous cell carcinoma of the external auditory canal: survival outcome based on T-staging and proposal of a new classification. *J Laryngol Otol* 135(2):96-103.
- 39 Thompson LD, Bouffard JP, Sandberg GD and Mena H (2003). Primary ear and temporal bone meningiomas: a clinicopathologic study of 36 cases with a review of the literature. *Mod Pathol* 16(3):236-245.
- 40 Mete O and Wenig BM (2022). Update from the 5th Edition of the World Health Organization Classification of Head and Neck Tumors: Overview of the 2022 WHO Classification of Head and Neck Neuroendocrine Neoplasms. *Head Neck Pathol* 16(1):123-142.

- 41 McCracken M, Pai K, Cabrera CI, Johnson BR, Tamaki A, Gidley PW and Manzoor NF (2023). Temporal Bone Resection for Squamous Cell Carcinoma of the Lateral Skull Base: Systematic Review and Meta-analysis. *Otolaryngol Head Neck Surg* 168(2):154-164.
- 42 Ito M, Hatano M and Yoshizaki T (2009). Prognostic factors for squamous cell carcinoma of the temporal bone: extensive bone involvement or extensive soft tissue involvement? *Acta Otolaryngol* 129(11):1313-1319.
- 43 Pfreundner L, Schwager K, Willner J, Baier K, Bratengeier K, Brunner FX and Flentje M (1999). Carcinoma of the external auditory canal and middle ear. *Int J Radiat Oncol Biol Phys* 44(4):777-788.
- 44 Gidley PW (2009). Managing malignancies of the external auditory canal. *Expert Rev Anticancer Ther* 9(9):1277-1282.
- 45 Shiga K, Nibu KI, Fujimoto Y, Asakage T, Homma A, Mitani H, Ogawa T, Okami K, Murono S, Hirano S, Ueda T, Hanai N, Tsukahara K, Ota I, Yoshimoto S, Shinozaki T, Iwae S, Katagiri K, Saito D, Kiyota N, Tahara M, Takahashi F and Hayashi R (2021). Multi-institutional Survey of Squamous Cell Carcinoma of the External Auditory Canal in Japan. *Laryngoscope* 131(3):E870-e874.
- 46 Hashi N, Shirato H, Omatsu T, Kagei K, Nishioka T, Hashimoto S, Aoyama H, Fukuda S, Inuyama Y and Miyasaka K (2000). The role of radiotherapy in treating squamous cell carcinoma of the external auditory canal, especially in early stages of disease. *Radiother Oncol* 56(2):221-225.
- 47 Higgins TS and Antonio SA (2010). The role of facial palsy in staging squamous cell carcinoma of the temporal bone and external auditory canal: a comparative survival analysis. *Otol Neurotol* 31(9):1473-1479.
- 48 Chee G, Mok P and Sim R (2000). Squamous cell carcinoma of the temporal bone: diagnosis, treatment and prognosis. *Singapore Med J* 41(9):441-446, 451.
- 49 Matoba T, Hanai N, Suzuki H, Nishikawa D, Tachibana E, Okada T, Murakami S and Hasegawa Y (2018). Treatment and Outcomes of Carcinoma of the External and Middle Ear: The Validity of En Bloc Resection for Advanced Tumor. *Neurol Med Chir (Tokyo)* 58(1):32-38.
- 50 Saijo K, Ueki Y, Tanaka R, Yokoyama Y, Omata J, Takahashi T, Ota H, Shodo R, Yamazaki K, Togashi T, Okabe R, Matsuyama H, Honda K, Sato Y, Morita Y, Takahashi K and Horii A (2021). Treatment Outcome of External Auditory Canal Carcinoma: The Utility of Lateral Temporal Bone Resection. *Front Surg* 8:708245.
- 51 Schwager K, Pfreundner L, Hoppe F, Baier G, Willner J and Baier K (2001). [Carcinoma of the external ear canal and middle ear as interdisciplinary challenge for ear surgery and radiotherapy]. *Laryngorhinootologie* 80(4):196-202.
- 52 Knegt PP, Ah-See KW, Meeuwis CA, van der Velden LA, Kerrebijn JD and De Boer MF (2002). Squamous carcinoma of the external auditory canal: a different approach. *Clin Otolaryngol Allied Sci* 27(3):183-187.
- 53 Chang CH, Shu MT, Lee JC, Leu YS, Chen YC and Lee KS (2009). Treatments and outcomes of malignant tumors of external auditory canal. *Am J Otolaryngol* 30(1):44-48.

- 54 Nyrop M and Grontved A (2002). Cancer of the external auditory canal. *Arch Otolaryngol Head Neck Surg* 128(7):834-837.
- 55 Lim LH, Goh YH, Chan YM, Chong VF and Low WK (2000). Malignancy of the temporal bone and external auditory canal. *Otolaryngol Head Neck Surg* 122(6):882-886.
- 56 Wang J, Xie B and Dai C (2015). Clinical Characteristics and Management of External Auditory Canal Squamous Cell Carcinoma in Post-Irradiated Nasopharyngeal Carcinoma Patients. *Otol Neurotol* 36(6):1081-1088.
- 57 Rindi G, Klimstra DS, Abedi-Ardekani B, Asa SL, Bosman FT, Brambilla E, Busam KJ, de Krijger RR, Dietel M, El-Naggar AK, Fernandez-Cuesta L, Klöppel G, McCluggage WG, Moch H, Ohgaki H, Rakha EA, Reed NS, Rous BA, Sasano H, Scarpa A, Scoazec JY, Travis WD, Tallini G, Trouillas J, van Krieken JH and Cree IA (2018). A common classification framework for neuroendocrine neoplasms: an International Agency for Research on Cancer (IARC) and World Health Organization (WHO) expert consensus proposal. *Mod Pathol* 31(12):1770-1786.
- 58 Uccella S, La Rosa S, Metovic J, Marchiori D, Scoazec JY, Volante M, Mete O and Papotti M (2021). Genomics of High-Grade Neuroendocrine Neoplasms: Well-Differentiated Neuroendocrine Tumor with High-Grade Features (G3 NET) and Neuroendocrine Carcinomas (NEC) of Various Anatomic Sites. *Endocr Pathol* 32(1):192-210.
- 59 Todorovic E, Truong T, Eskander A, Lin V, Swanson D, Dickson BC and Weinreb I (2020). Middle Ear and Temporal Bone Nonkeratinizing Squamous Cell Carcinomas With DEK-AFF2 Fusion: An Emerging Entity. *Am J Surg Pathol* 44(9):1244-1250.
- 60 Ungar OJ, Santos F, Nadol JB, Horowitz G, Fliss DM, Faquin WC and Handzel O (2021). Invasion Patterns of External Auditory Canal Squamous Cell Carcinoma: A Histopathology Study. *Laryngoscope* 131(2):E590-e597.
- 61 Correia-Rodrigues P, Ramalho S, Montalvão P and Magalhães M (2020). External auditory canal carcinoma: clinical characteristics and long-term treatment outcomes. *Eur Arch Otorhinolaryngol* 277(10):2709-2720.
- 62 Sato K, Komune N, Hongo T, Koike K, Niida A, Uchi R, Noda T, Kogo R, Matsumoto N, Yamamoto H, Masuda M, Oda Y, Mimori K and Nakagawa T (2020). Genetic landscape of external auditory canal squamous cell carcinoma. *Cancer Sci* 111(8):3010-3019.
- 63 Ferris RL, Blumenschein G, Jr., Fayette J, Guigay J, Colevas AD, Licitra L, Harrington K, Kasper S, Vokes EE, Even C, Worden F, Saba NF, Iglesias Docampo LC, Haddad R, Rordorf T, Kiyota N, Tahara M, Monga M, Lynch M, Geese WJ, Kopit J, Shaw JW and Gillison ML (2016). Nivolumab for Recurrent Squamous-Cell Carcinoma of the Head and Neck. *N Engl J Med* 375(19):1856-1867.
- 64 Cohen EEW, Soulières D, Le Tourneau C, Dinis J, Licitra L, Ahn MJ, Soria A, Machiels JP, Mach N, Mehra R, Burtness B, Zhang P, Cheng J, Swaby RF and Harrington KJ (2019). Pembrolizumab versus methotrexate, docetaxel, or cetuximab for recurrent or metastatic head-and-neck squamous cell carcinoma (KEYNOTE-040): a randomised, open-label, phase 3 study. *Lancet* 393(10167):156-167.

- 65 Burtneß B, Harrington KJ, Greil R, Soulières D, Tahara M, de Castro G, Jr., Psyrrí A, Basté N, Neupane P, Bratland Å, Fuefeder T, Hughes BGM, Mesía R, Ngamphaiboon N, Rordorf T, Wan Ishak WZ, Hong RL, González Mendoza R, Roy A, Zhang Y, Gumuscu B, Cheng JD, Jin F and Rischin D (2019). Pembrolizumab alone or with chemotherapy versus cetuximab with chemotherapy for recurrent or metastatic squamous cell carcinoma of the head and neck (KEYNOTE-048): a randomised, open-label, phase 3 study. *Lancet* 394(10212):1915-1928.
- 66 Seiwert TY, Burtneß B, Mehra R, Weiss J, Berger R, Eder JP, Heath K, McClanahan T, Lunceford J, Gause C, Cheng JD and Chow LQ (2016). Safety and clinical activity of pembrolizumab for treatment of recurrent or metastatic squamous cell carcinoma of the head and neck (KEYNOTE-012): an open-label, multicentre, phase 1b trial. *Lancet Oncol* 17(7):956-965.
- 67 Litchfield K, Reading JL, Puttick C, Thakkar K, Abbosh C, Bentham R, Watkins TBK, Rosenthal R, Biswas D, Rowan A, Lim E, Al Bakir M, Turati V, Guerra-Assunção JA, Conde L, Furness AJS, Saini SK, Hadrup SR, Herrero J, Lee SH, Van Loo P, Enver T, Larkin J, Hellmann MD, Turajlic S, Quezada SA, McGranahan N and Swanton C (2021). Meta-analysis of tumor- and T cell-intrinsic mechanisms of sensitization to checkpoint inhibition. *Cell* 184(3):596-614.e514.
- 68 Nabuurs CH, Kievit W, Labbé N, Leemans CR, Smit C, van den Brekel MWM, Pauw RJ, van der Laan B, Jansen JC, Lacko M, Braunius WW, Morita S, Wierzbicka M, Matoba T, Hanai N, Takes RP and Kunst HPM (2020). Evaluation of the modified Pittsburgh classification for predicting the disease-free survival outcome of squamous cell carcinoma of the external auditory canal. *Head Neck* 42(12):3609-3622.
- 69 Arriaga M, Curtin H, Takahashi H, Hirsch BE and Kameroner DB (1990). Staging proposal for external auditory meatus carcinoma based on preoperative clinical examination and computed tomography findings. *Ann Otol Rhinol Laryngol* 99(9 Pt 1):714-721.
- 70 Shinomiya H, Uehara N, Teshima M, Kakigi A, Otsuki N and Nibu KI (2019). Clinical management for T1 and T2 external auditory canal cancer. *Auris Nasus Larynx* 46(5):785-789.
- 71 Cazzador D, Franz L, Tealdo G, Carobbio ALC, Ferraro M, Mazzone A, Marioni G and Zanoletti E (2023). Survival Outcomes in Squamous Cell Carcinoma of the External Auditory Canal: A Systematic Review and Meta-Analysis. *J Clin Med* 12(7):2490.
- 72 Bacciu A, Clemente IA, Piccirillo E, Ferrari S and Sanna M (2013). Guidelines for treating temporal bone carcinoma based on long-term outcomes. *Otol Neurotol* 34(5):898-907.
- 73 Mazzone A, Danesi G and Zanoletti E (2014). Primary squamous cell carcinoma of the external auditory canal: surgical treatment and long-term outcomes. *Acta Otorhinolaryngol Ital* 34(2):129-137.
- 74 Xia S, Yan S, Zhang M, Cheng Y, Noel J, Chong V and Shen W (2015). Radiological Findings of Malignant Tumors of External Auditory Canal: A Cross-Sectional Study Between Squamous Cell Carcinoma and Adenocarcinoma. *Medicine (Baltimore)* 94(35):e1452.
- 75 Moody SA, Hirsch BE and Myers EN (2000). Squamous cell carcinoma of the external auditory canal: an evaluation of a staging system. *Am J Otol* 21(4):582-588.

- 76 Brandwein-Gensler M, Teixeira MS, Lewis CM, Lee B, Rolnitzky L, Hille JJ, Genden E, Urken ML and Wang BY (2005). Oral squamous cell carcinoma: histologic risk assessment, but not margin status, is strongly predictive of local disease-free and overall survival. *Am J Surg Pathol* 29(2):167-178.
- 77 Bambakidis NC, Megerian CA and Ratcheson RA (2004). Differential grading of endolymphatic sac tumor extension by virtue of von Hippel-Lindau disease status. *Otol Neurotol* 25(5):773-781.